



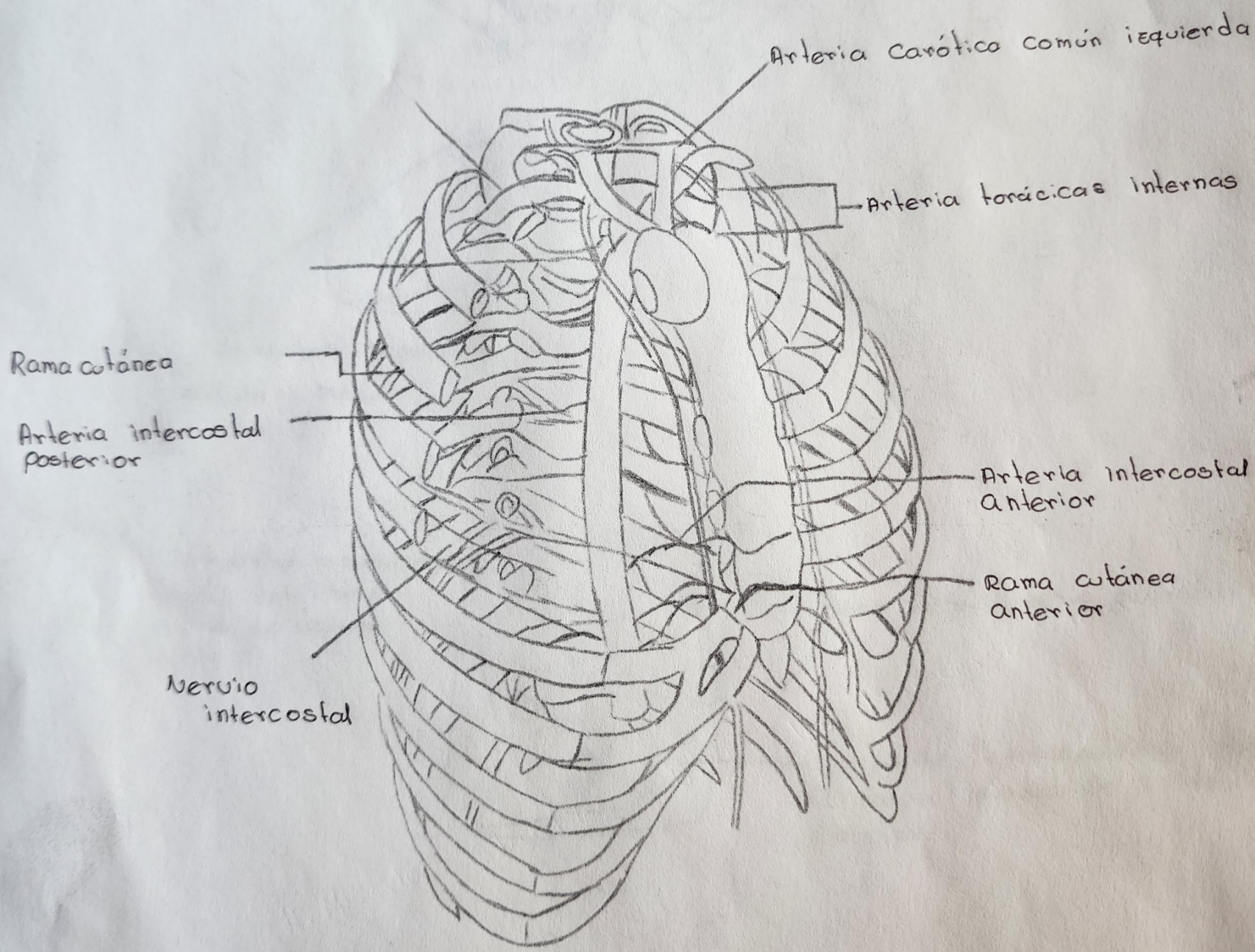
Esquema de la caja torácica

Franklin Samuel Gordillo Guillén

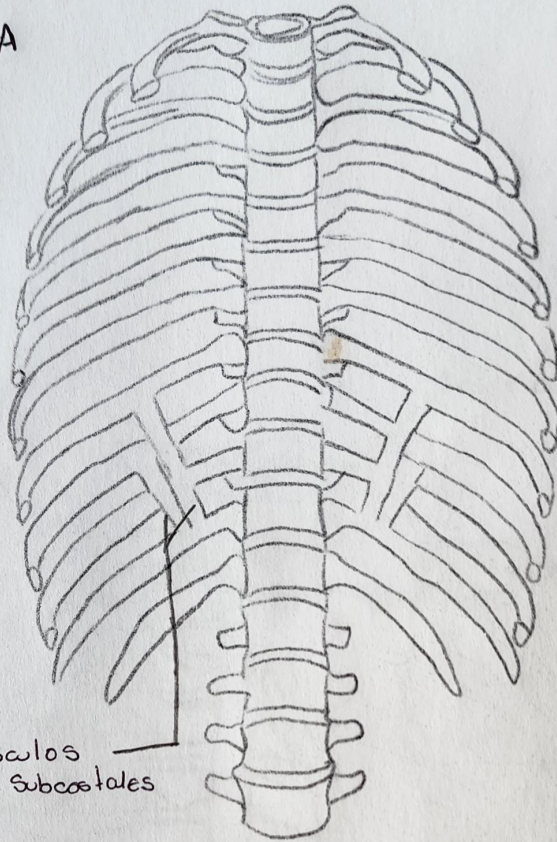
Universidad Del Sureste

Anatomía

Dr. Lizbeth Anahí Ruíz Córdova

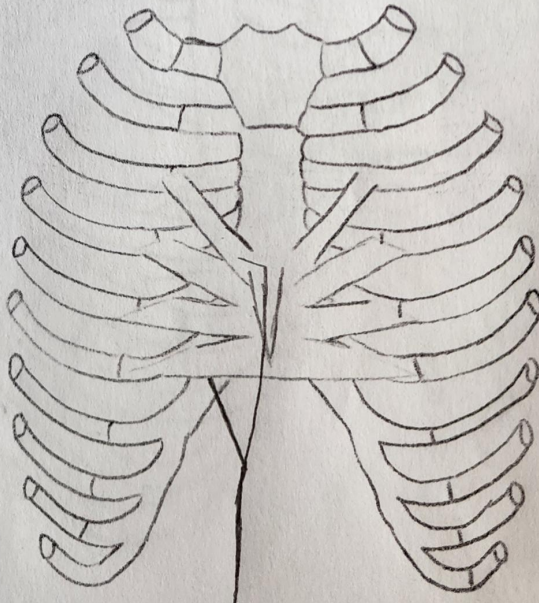


A



músculos
subcostales

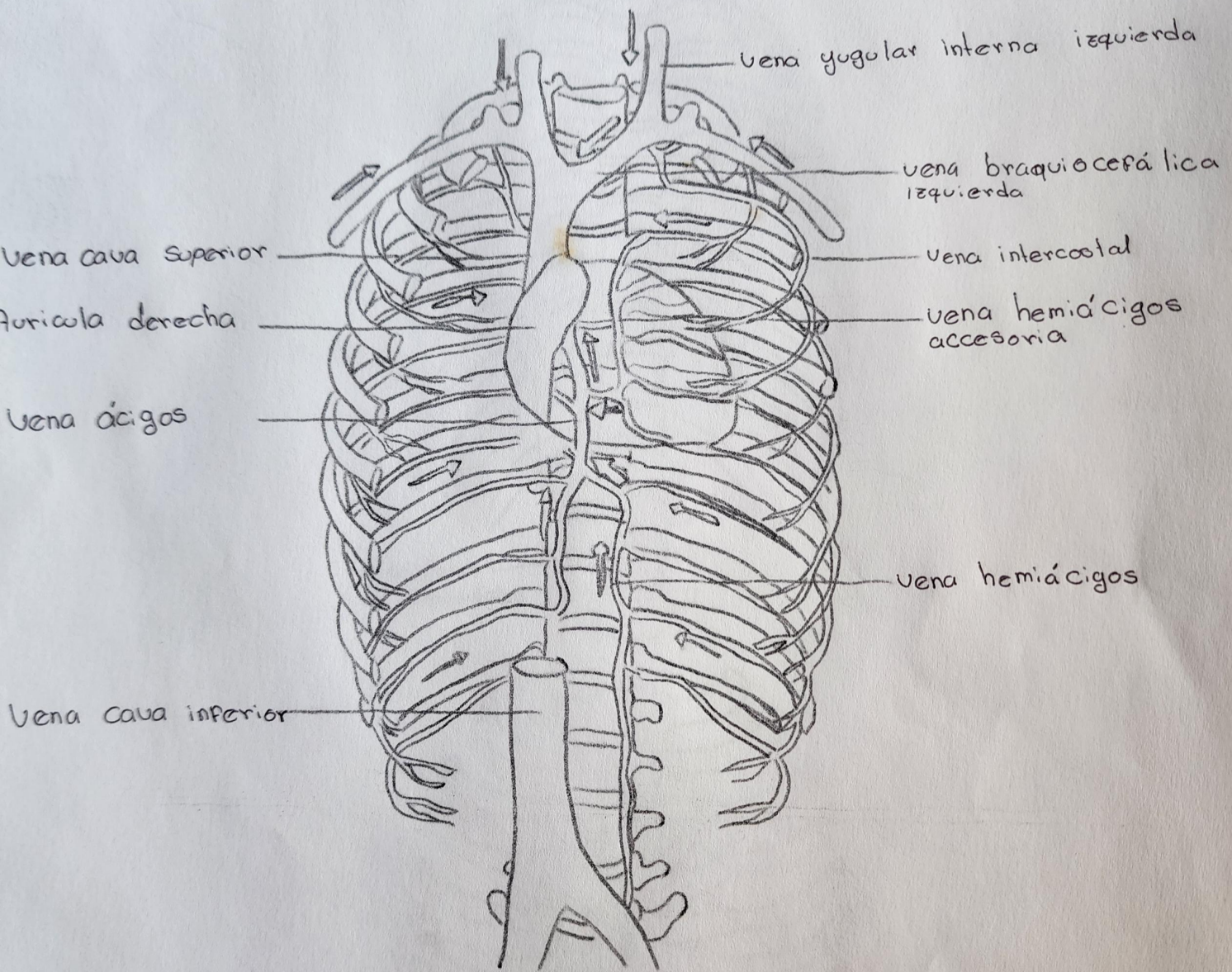
B



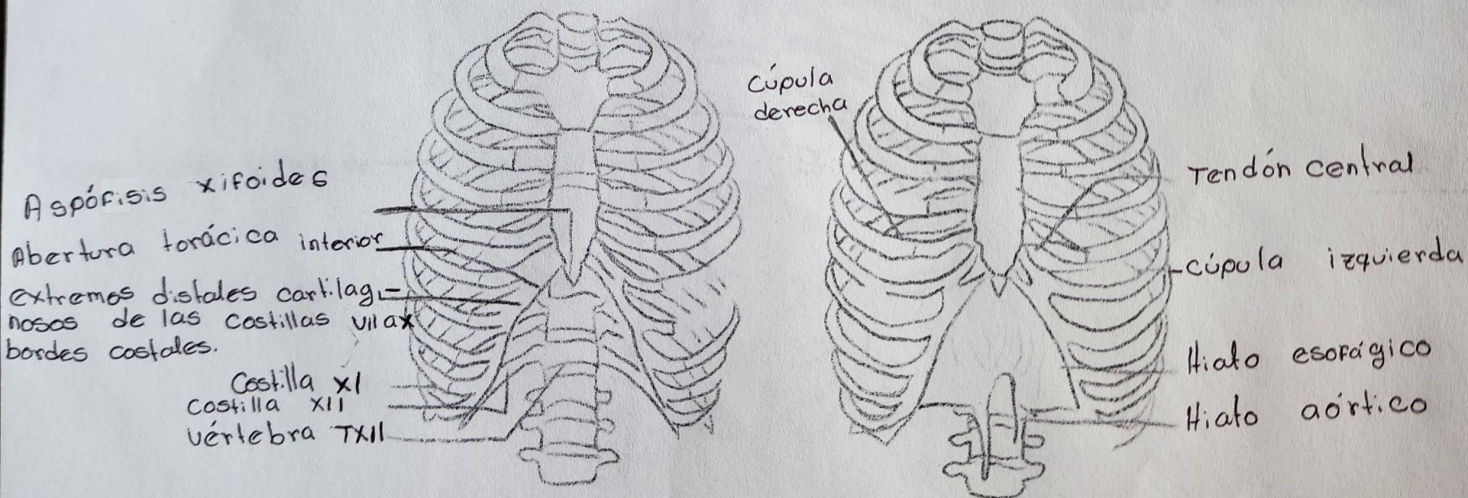
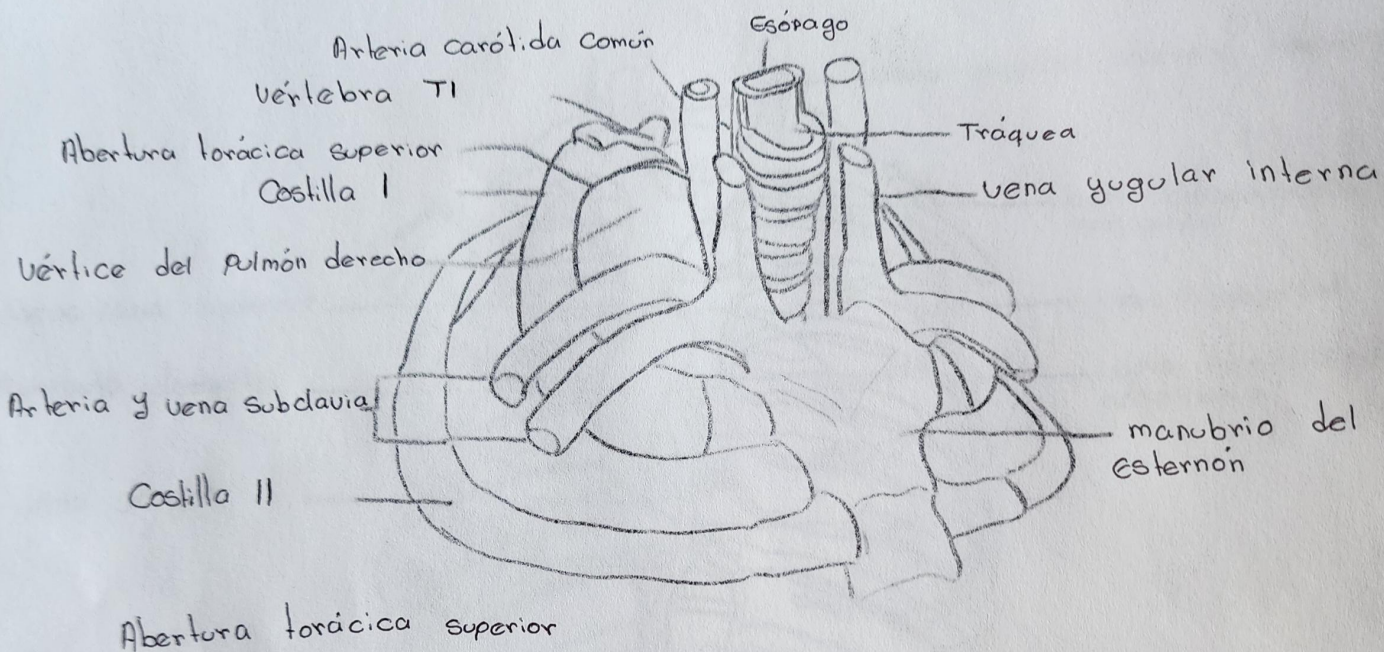
Músculos transversos torácicos

A. Músculos subcostales

B. Músculos transversos torácicos

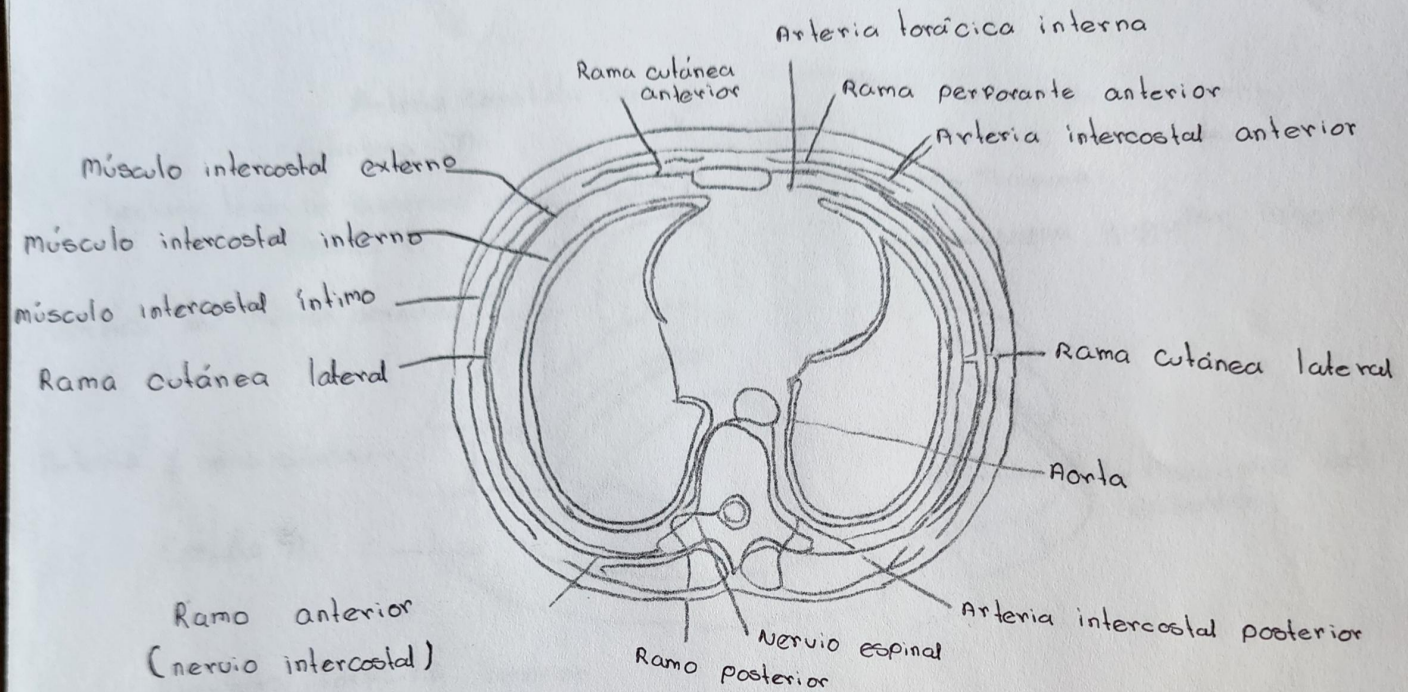


Circuitos venosos de izquierda a derecha.

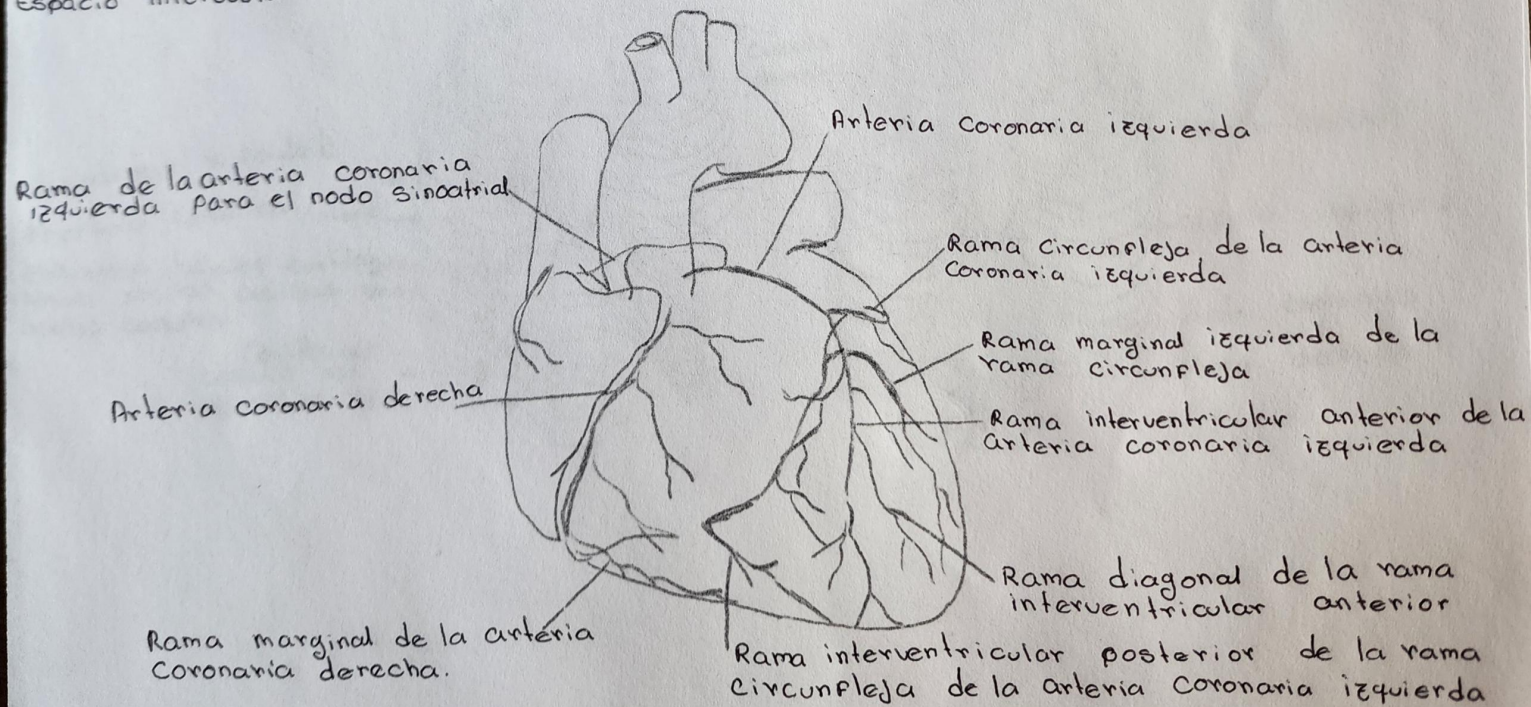


- A. Abertura torácica inferior
 B. Diafragma.

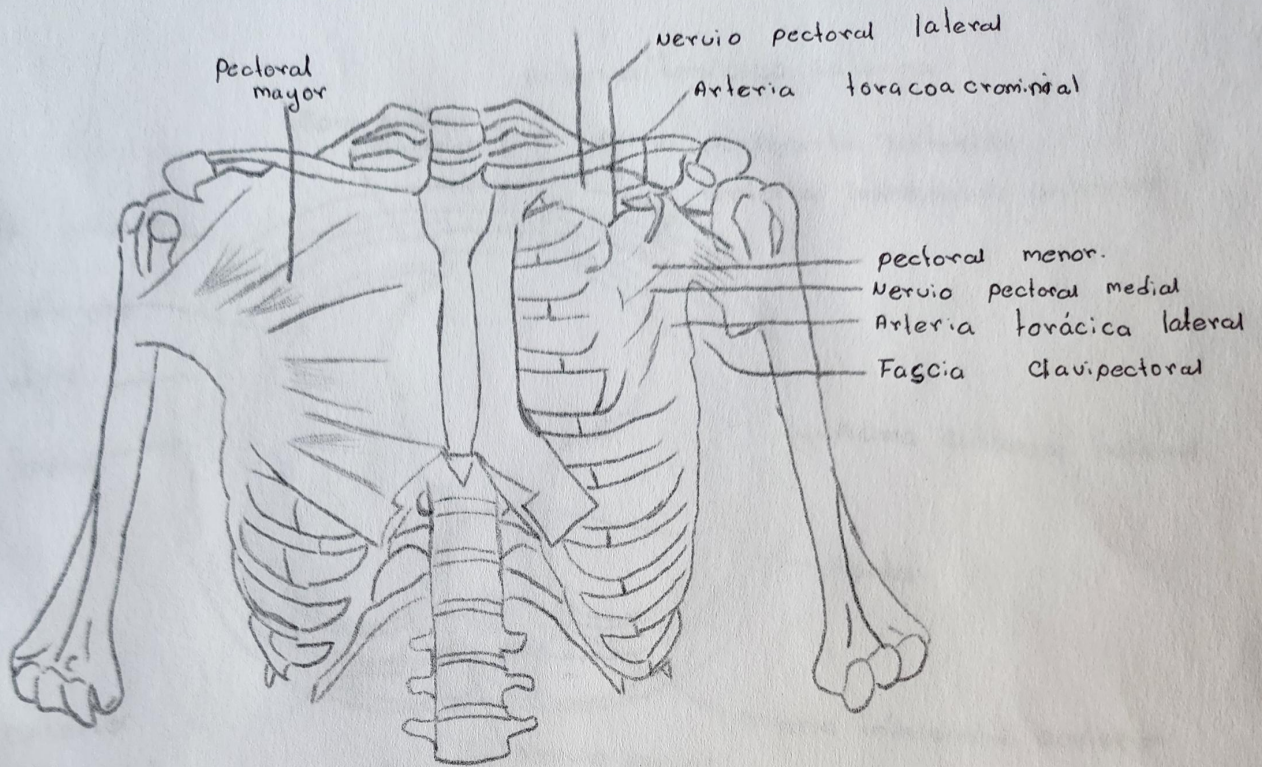
C



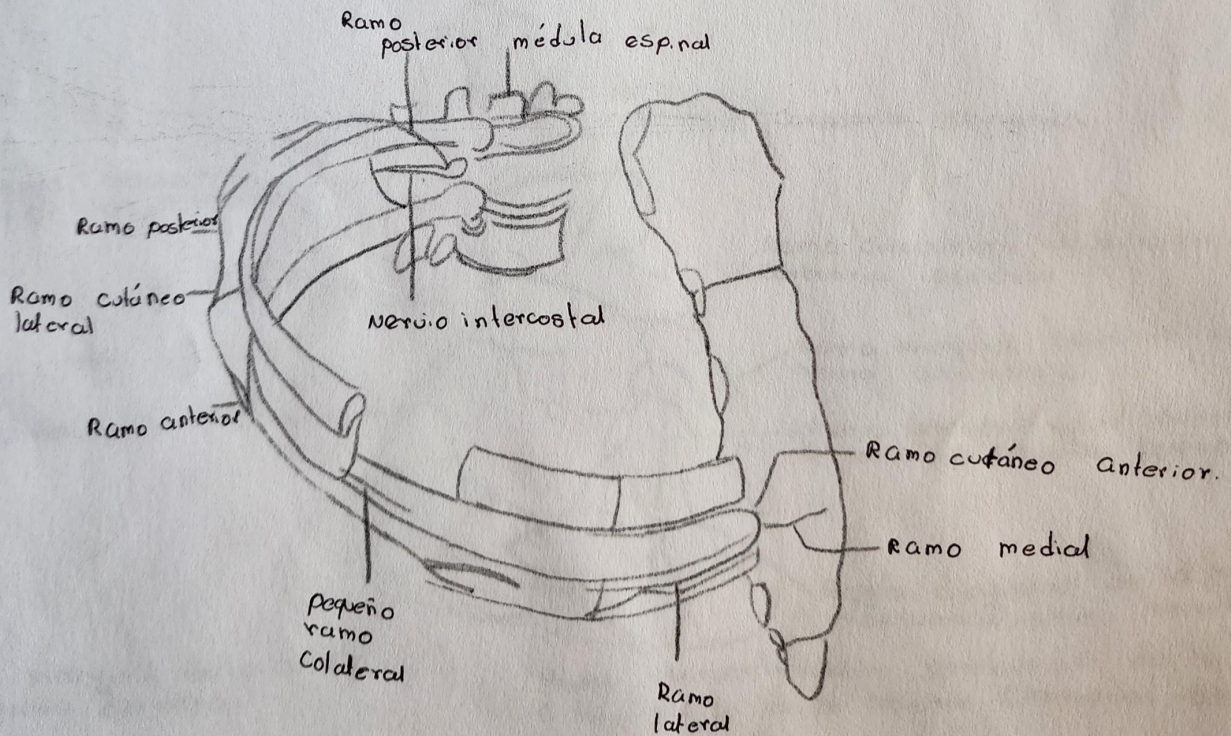
Espacio intercostal C. Apófisis transversal



Arteria Coronaria izquierda dominante.

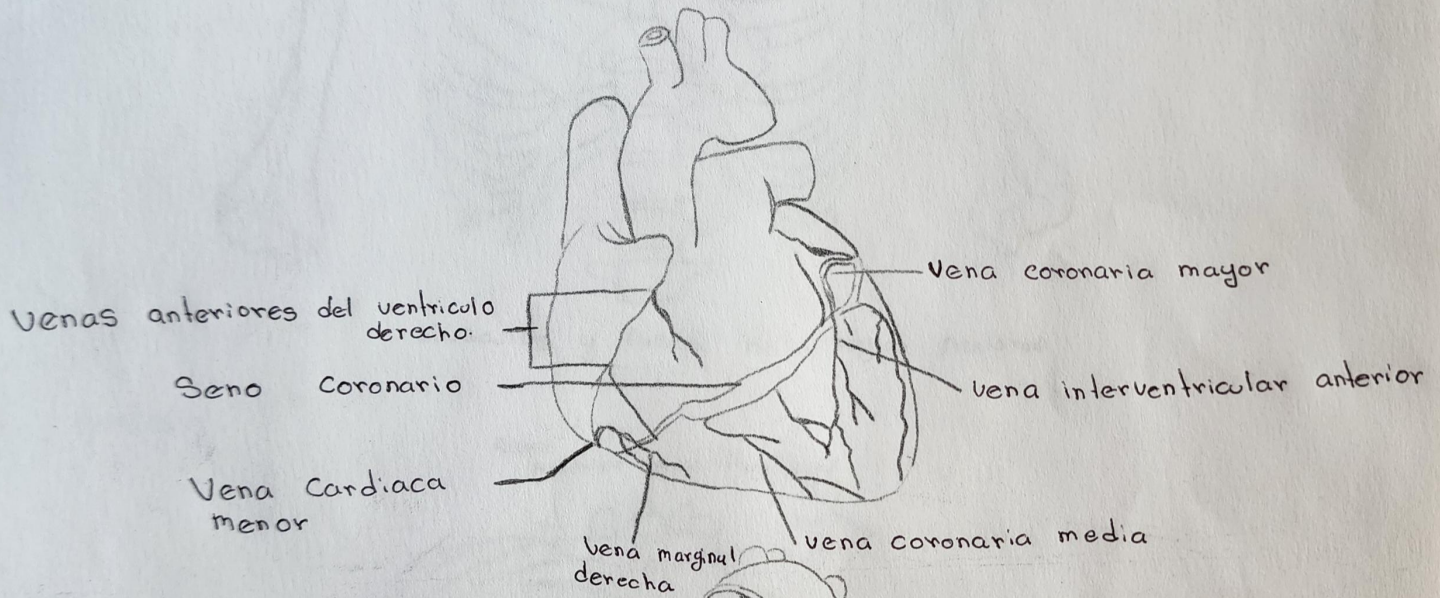


Músculos y fascia de la región pectoral

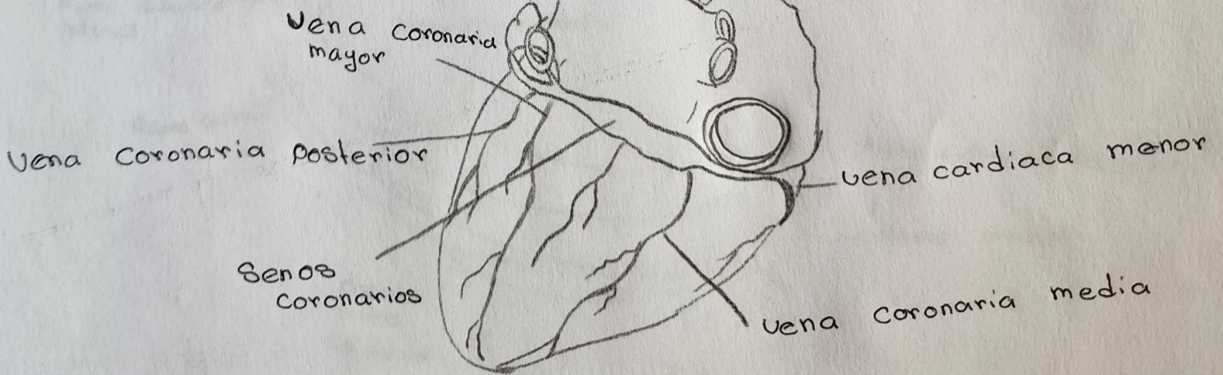


Nervios intercostales

A



B

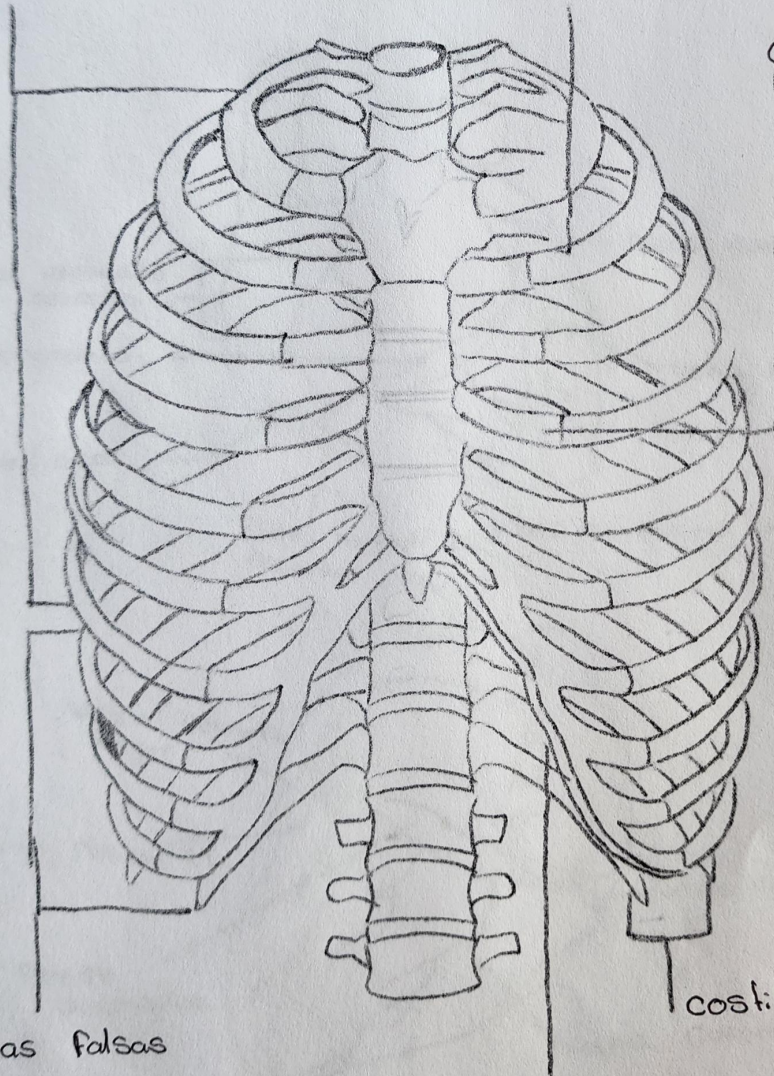


Venas Cardíacas mayores A. vision anterior de las Venas Cardíacas mayores.
B. vision posteroinferior de las Venas Cardíacas mayores

Costillas verdaderas

Espacio intercostal

Cartilago costal



Costillas falsas

costillas flotantes.

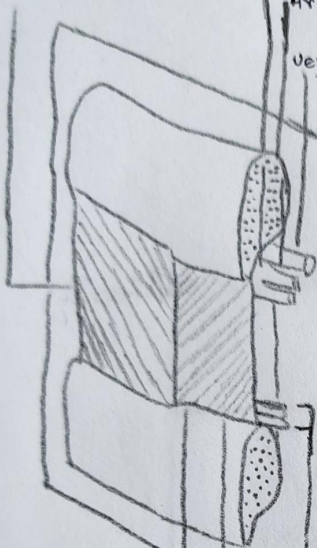
Borde costal

Músculo intercostal externo

Nervio intercostal

Arteria intercostal

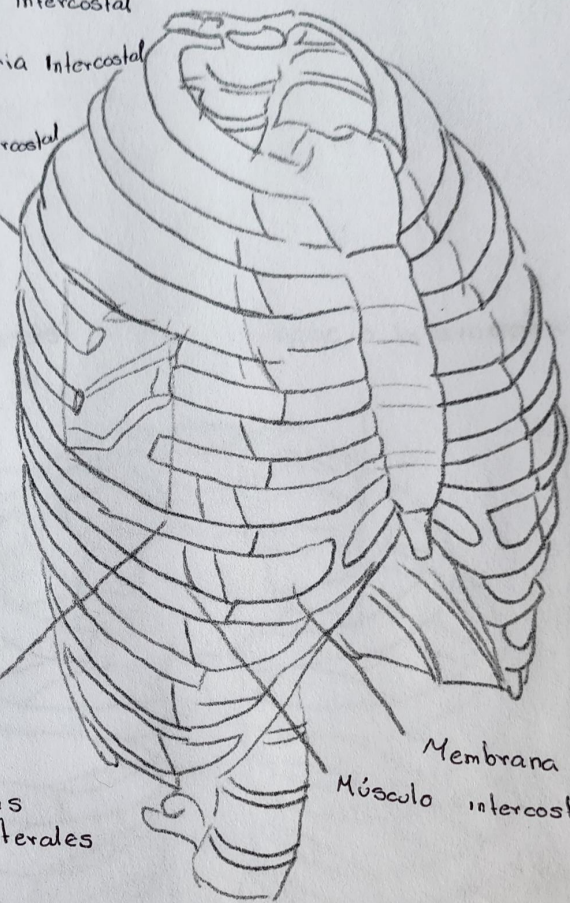
Vena intercostal



Músculo intercostal interno

Músculo intercostal íntimo

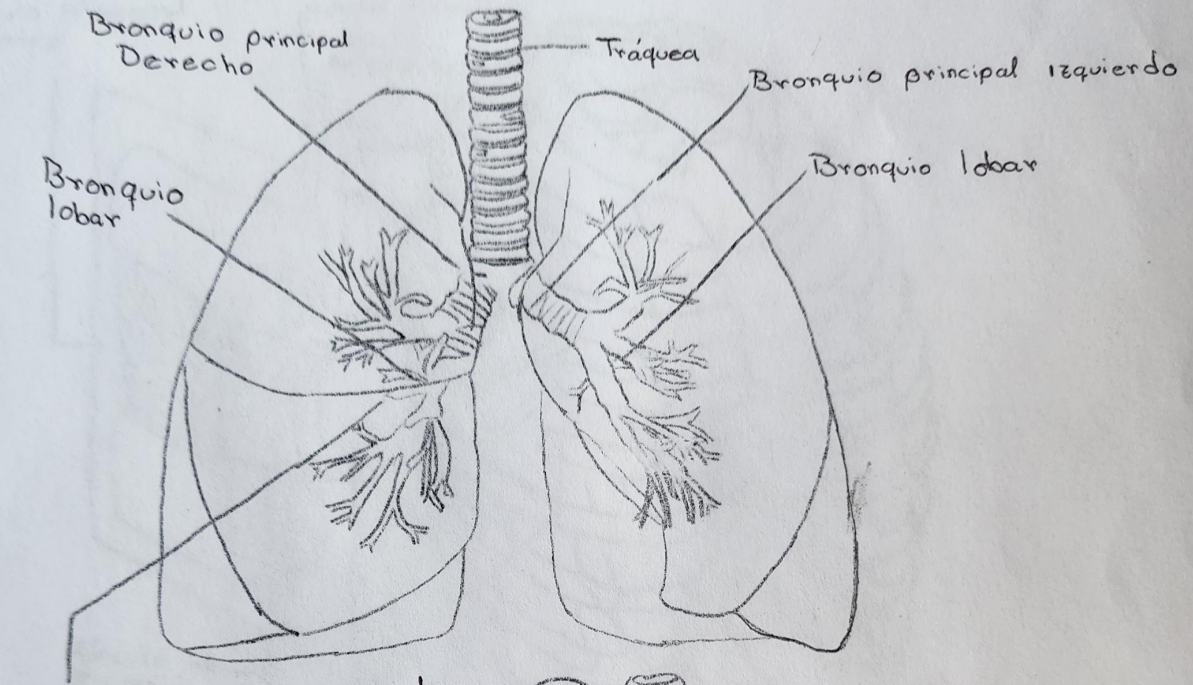
Ramas colaterales



Membrana intercostal externa

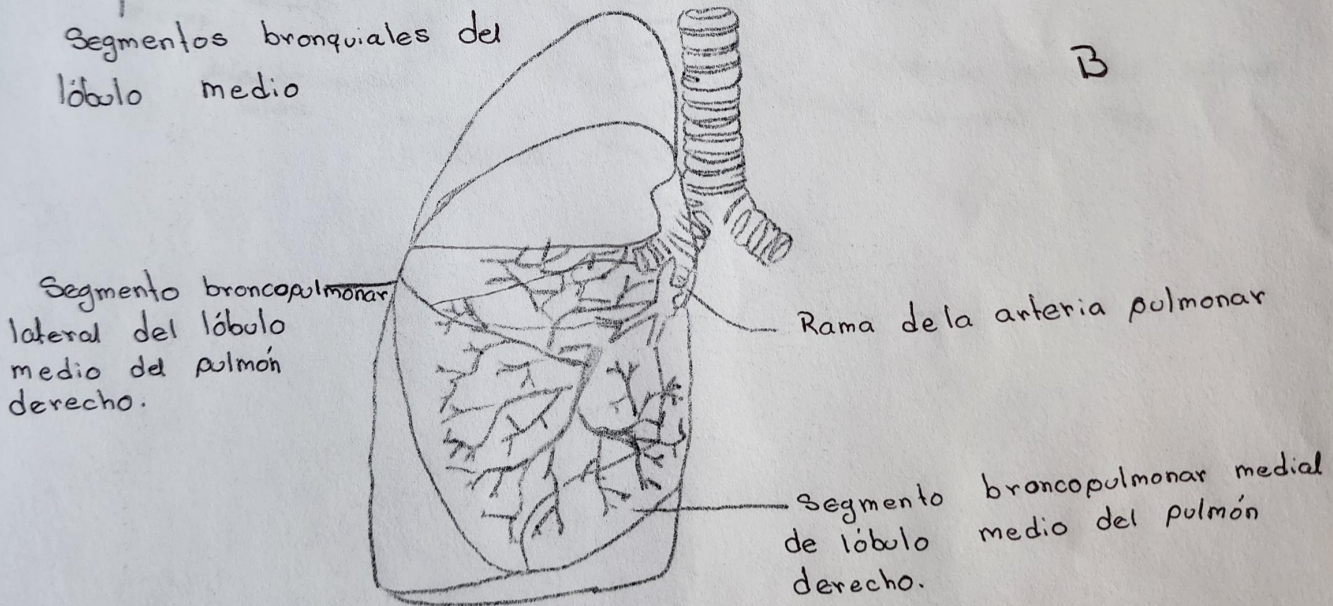
Músculo intercostal externo

A



Segmentos bronquiales del lóbulo medio

B



A. Árbol bronquial

B. Segmentos broncopulmonares.