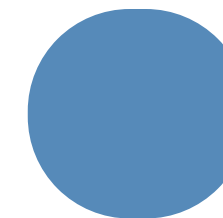


**Mi Universidad**

**UNIVERSIDAD DEL SURESTE**  
**CAMPUS COMITÁN DE DOMÍNGUEZ, CHIAPAS.**  
**MEDICINA HUMANA**



# **DUODENO Y OBSTRUCCIÓN INTESTINAL**

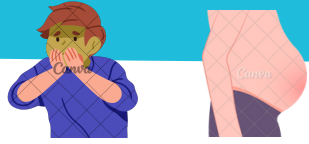
**VIRGINIA GUADALUPE CABRERA MALDONADO**

**IMAGENOLOGÍA I**

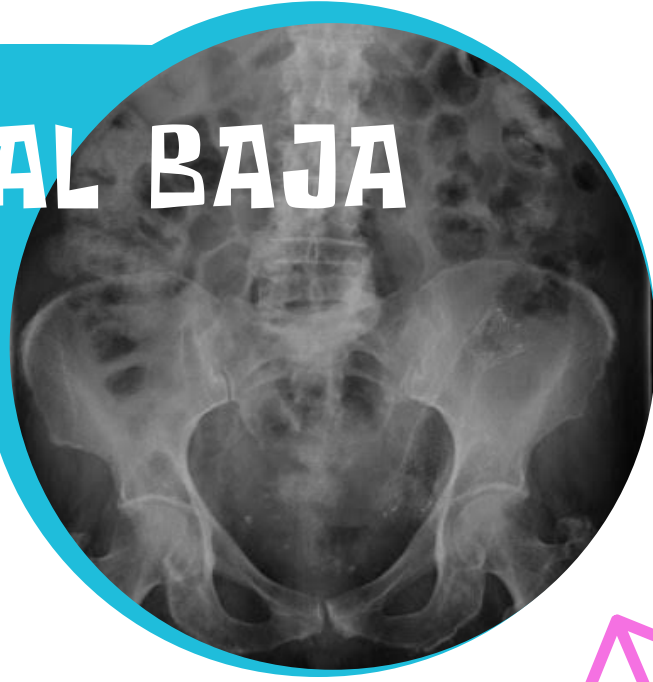**3° PARCIAL, 4° SEMESTRE "D"**

**VIERNES 24 DE MAYO DEL 2024.**


# OBSTRUC. INTESTINAL BAJA



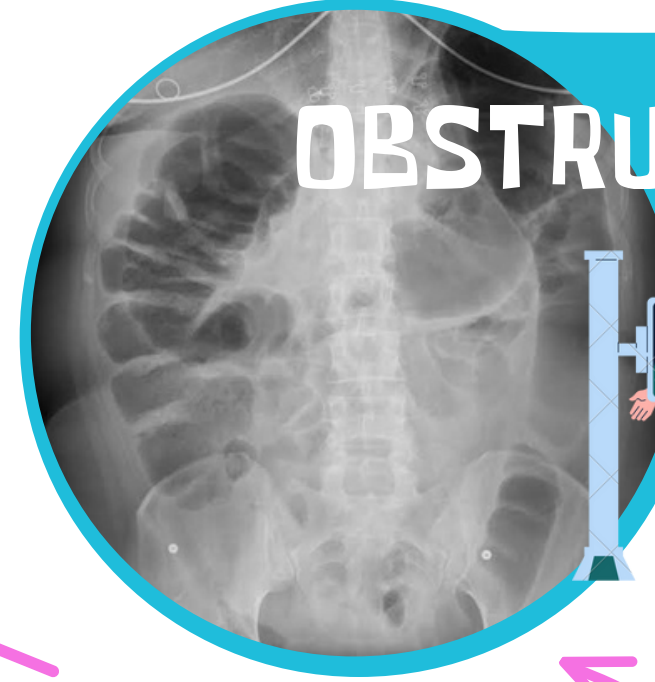
- RADIOGRAFÍA SIMPLE.
- COLON POR EDEMA.



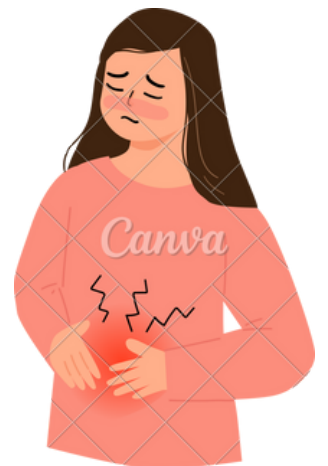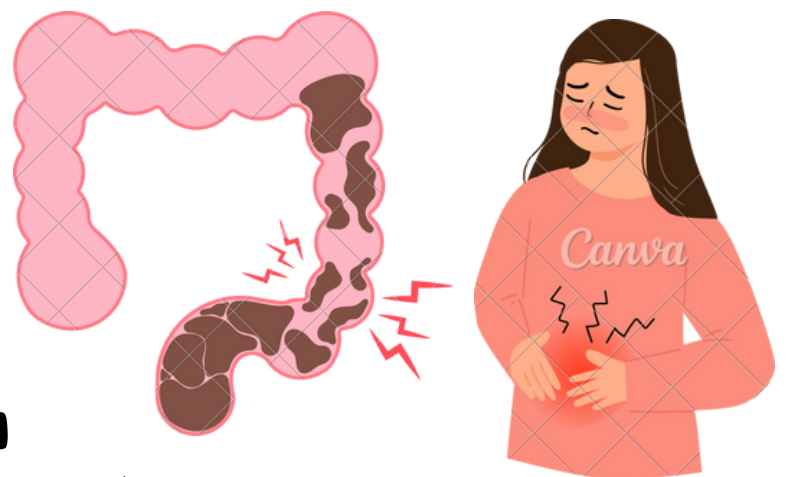
# OBSTRUC. INTESTINAL ALTA



- RADIOGRAFÍA SIMPLE.
- COLON POR EDEMA.

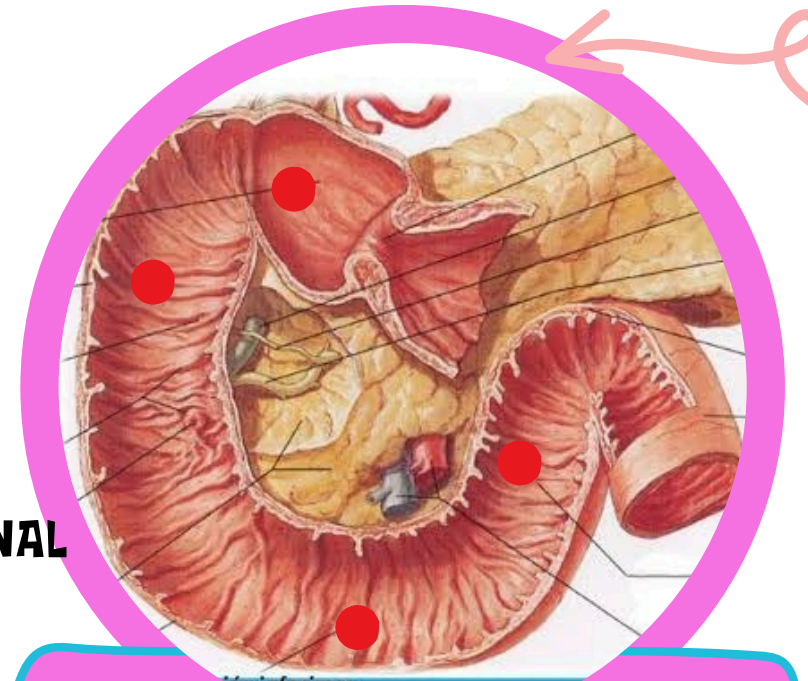


- VOMITO
- CONSTIPACIÓN
- DISTENSIÓN



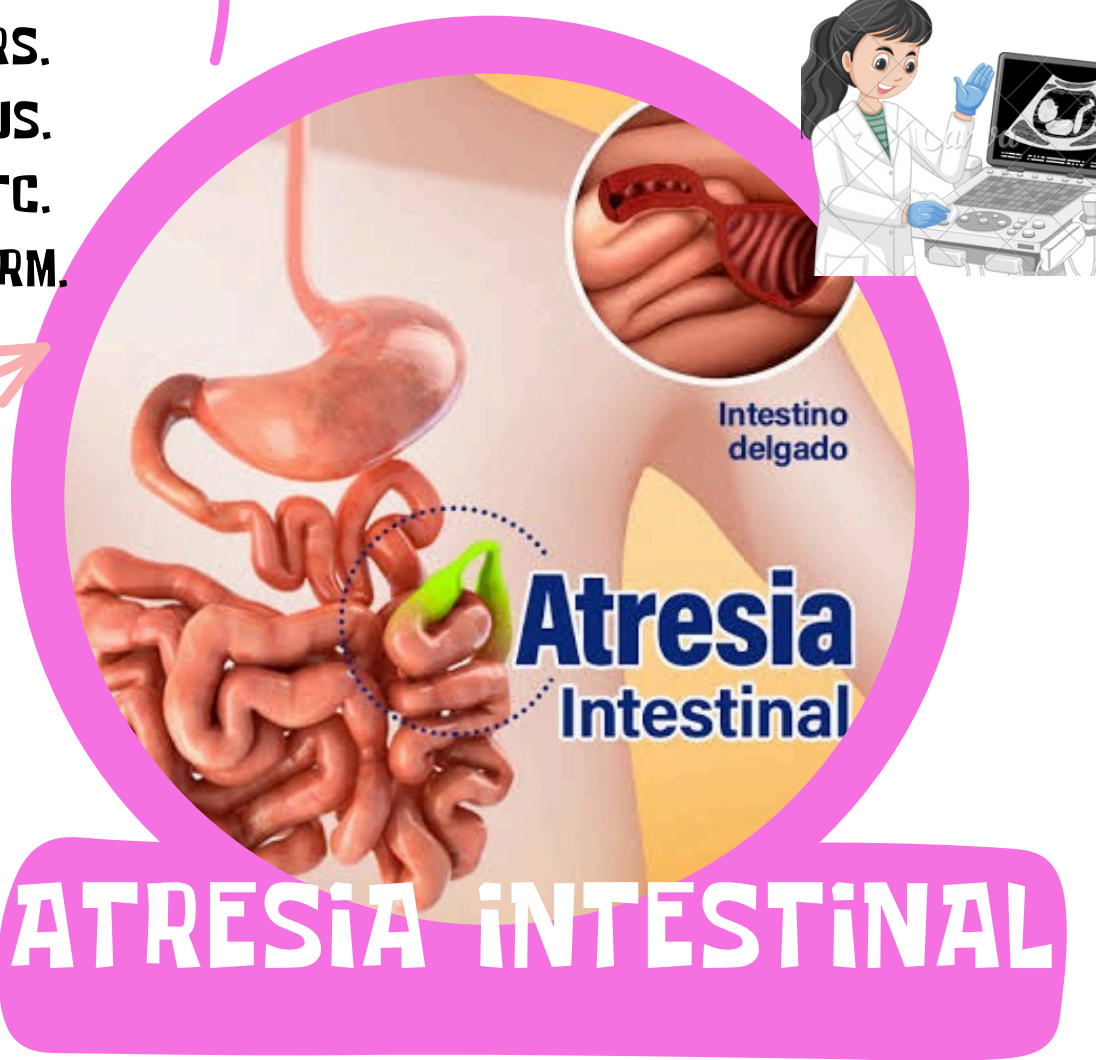
# DUODENO

- RS.
- US.
- TC.
- IRM.



- BULBO DUODENAL
- DESCENDENTE
- TRANSVERSO
- ASCENDENTE

## PORCIONES:



# ATRESIA INTESTINAL