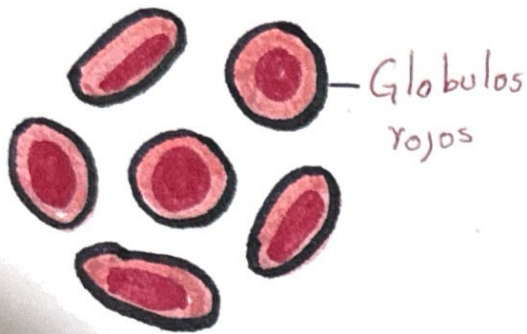


Globulos rojos

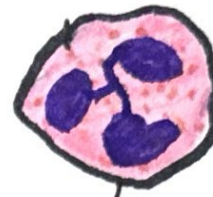Eritrocito



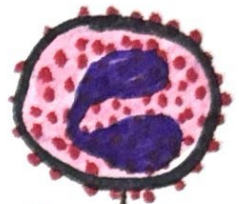Monocito



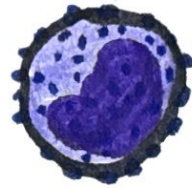Linfocito



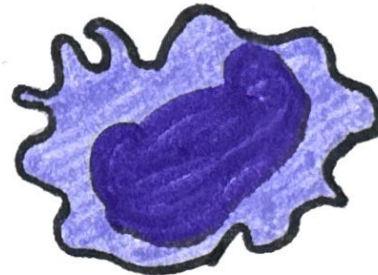
Neutrófilo



~~Eosinófilo~~
Eosinófilo

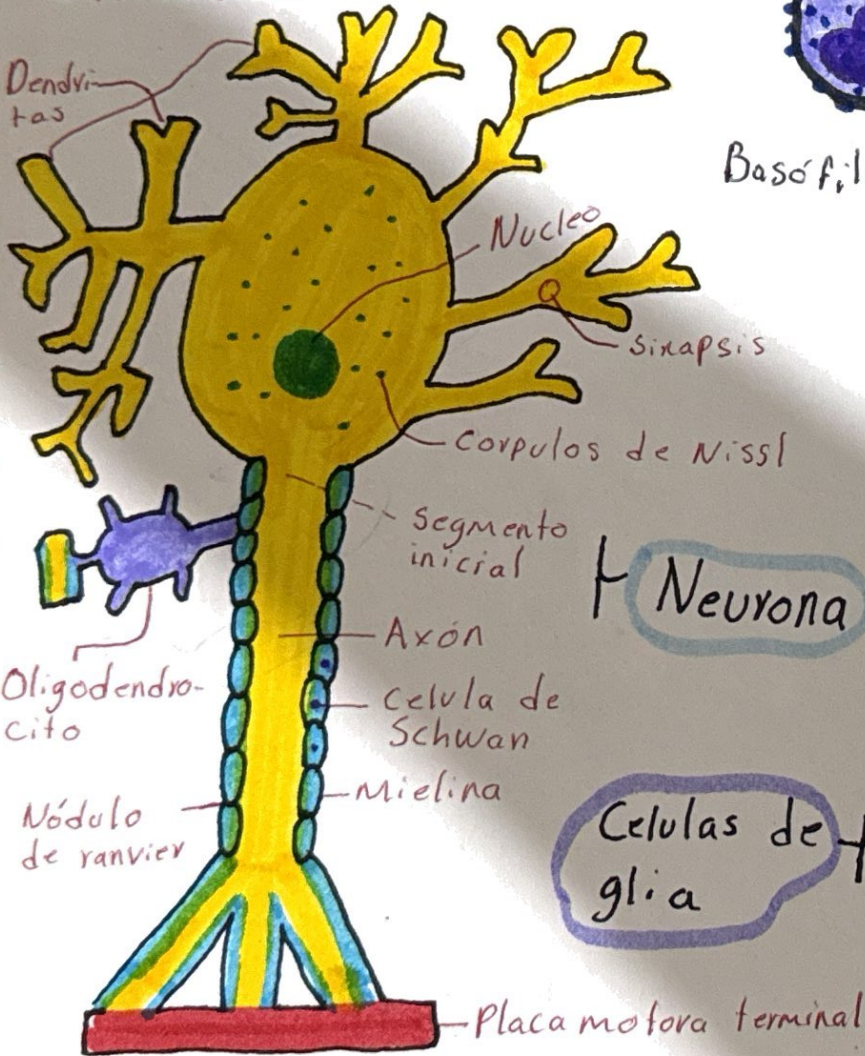


Basófilo



Macrófago

Tipos de leucocitos



Neurona

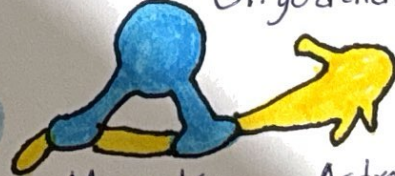
Cellulas de glia



Cellulas de Schwann




Oligodendrocitos



Microglia

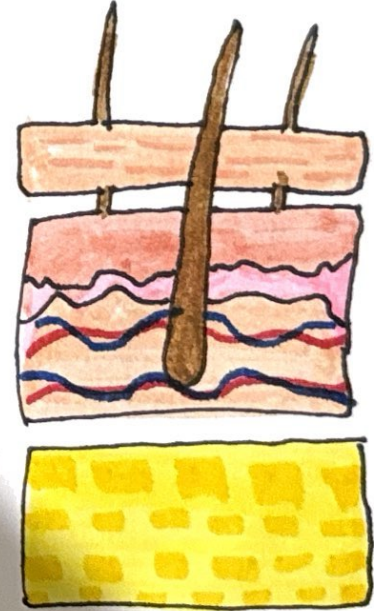


Astrocyto



Cellulas epidermicas

Capas de la piel



Epidermis

Dermis

hipodermis