



Mi Universidad

Nombre del Alumno: Juan Manuel Jimenez Alvarez.

Nombre del tema : Sistemas del cuerpo Humano

Nombre de la Materia: Ingles II

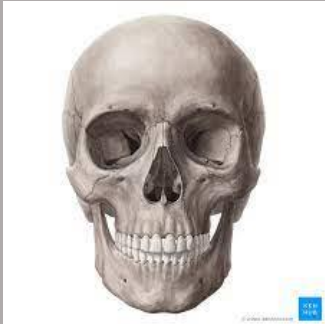Nombre del profesor: Ignacio Javier sossa

Nombre de la Licenciatura: Enfermería.

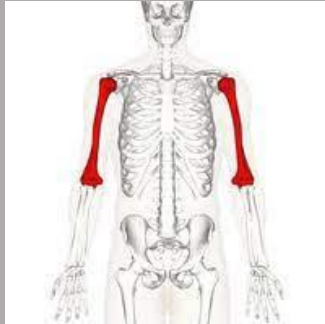Cuatrimestre: 2°

Parcial :2°

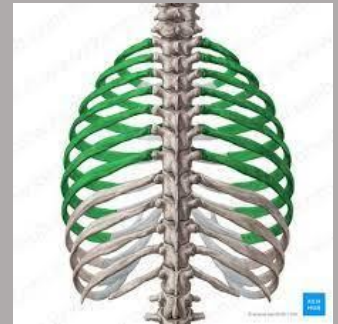SISTEMA ESQUELETICO



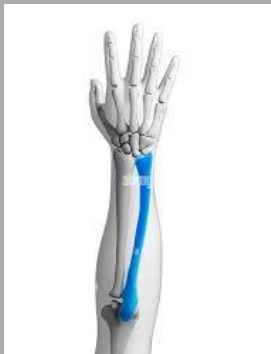Cranium



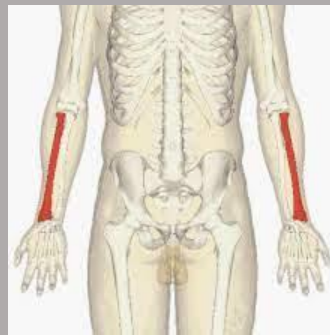Humerus



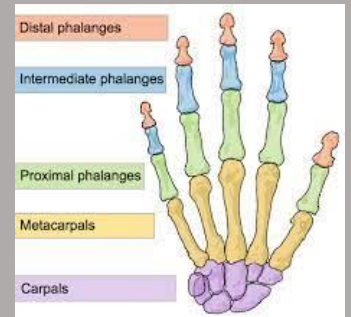
Ribs



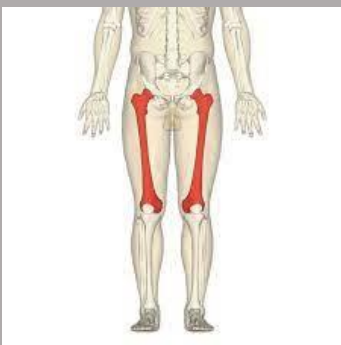Ulna



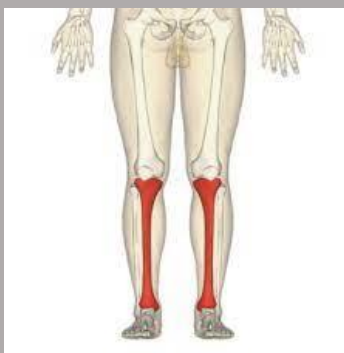Radius



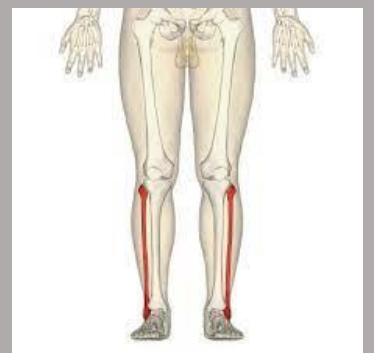Metacarpals



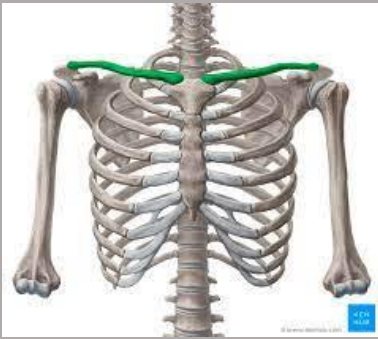
Femur



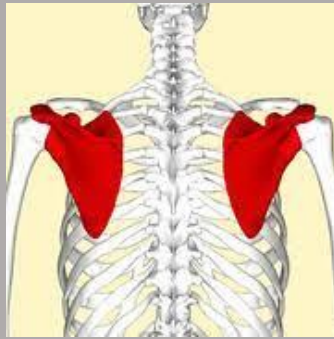
Tibia



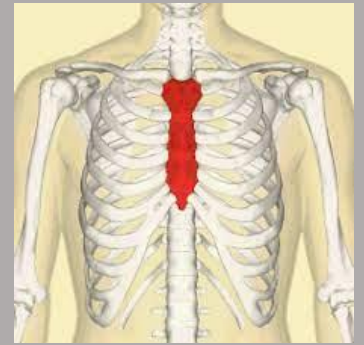
Fíbula



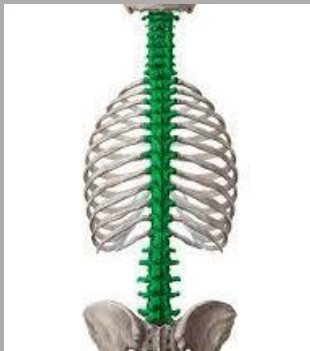Clavicle



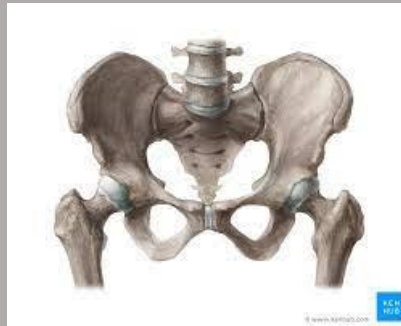Scapula



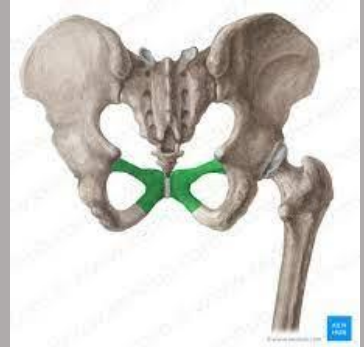Sternum



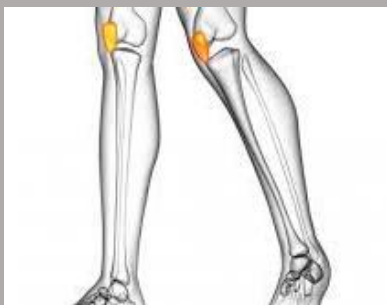**Vertebral
column**



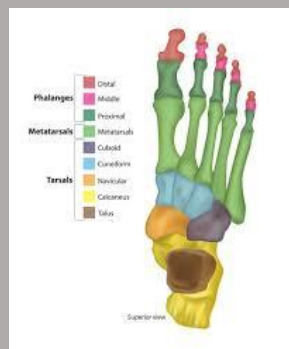
Pelvis



Pubis

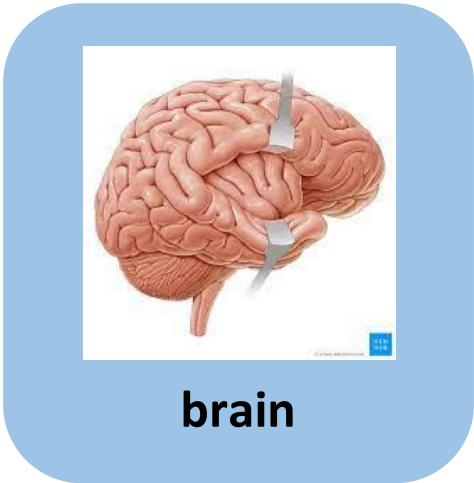


Patella

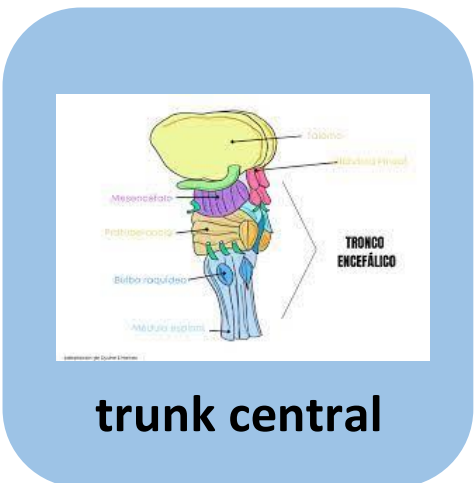


Metatarsals

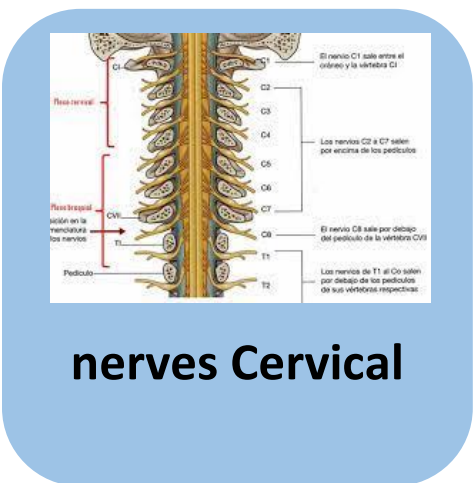
SISTEMA NERVIOSO



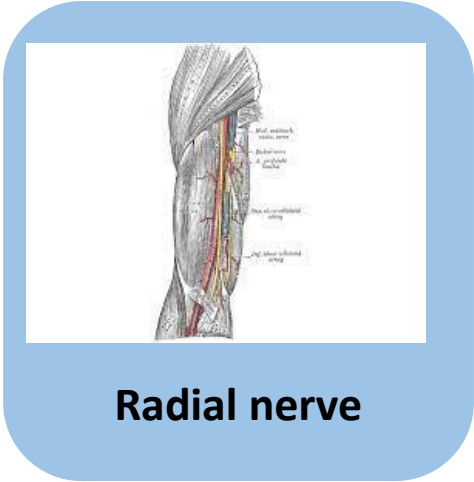
brain



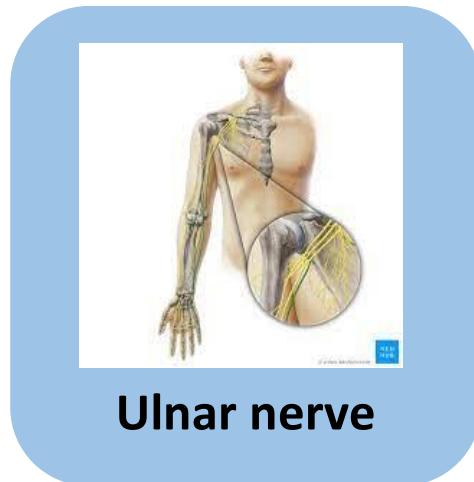
trunk central



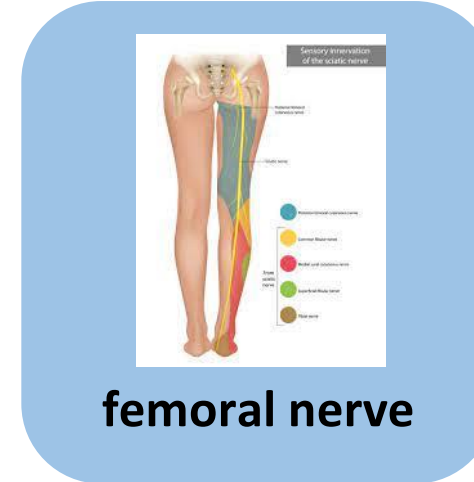
nerves Cervical



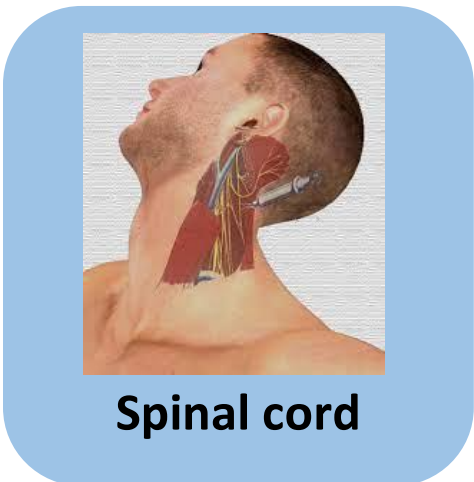
Radial nerve



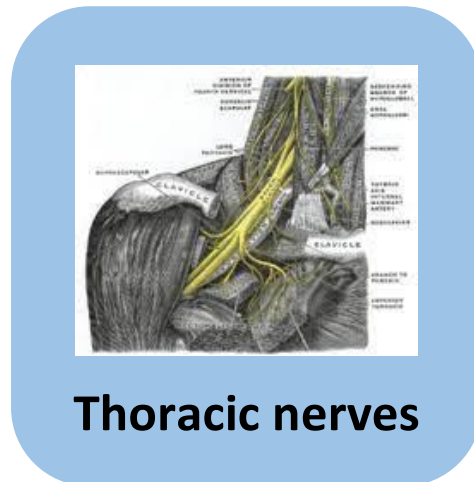
Ulnar nerve



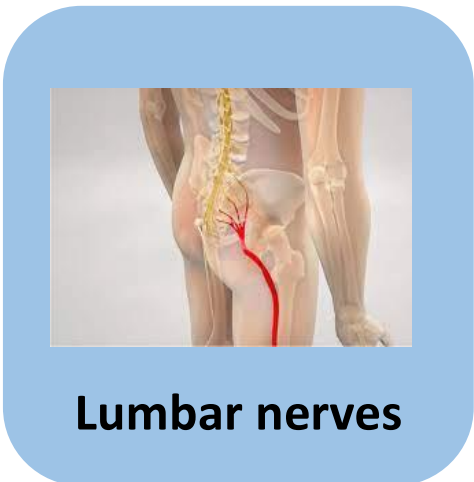femoral nerve



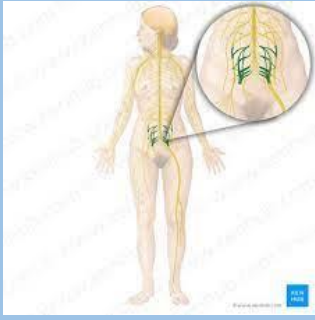Spinal cord



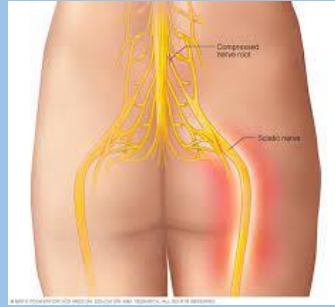
Thoracic nerves



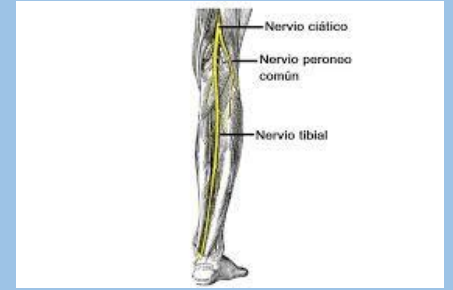Lumbar nerves



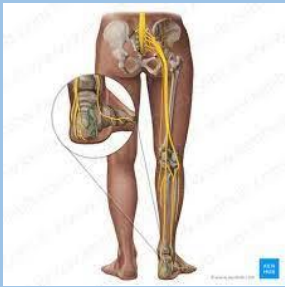Sacral nerves



sciatic nerve

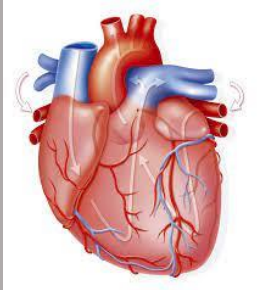


Tibial nerve

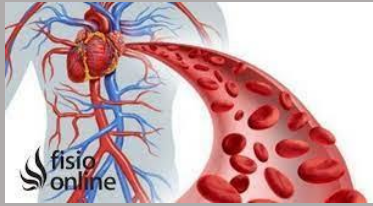


Plantar nerve

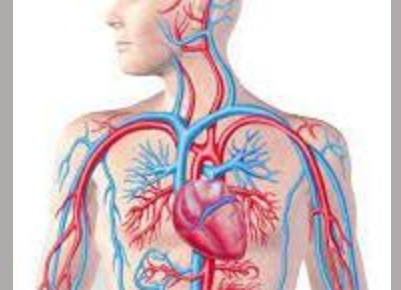SISTEMA CARDIOVASCULAR



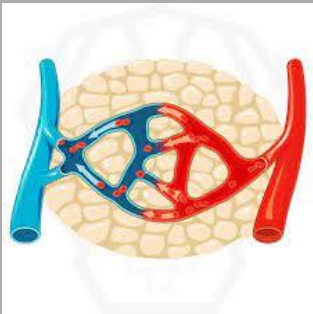
heart



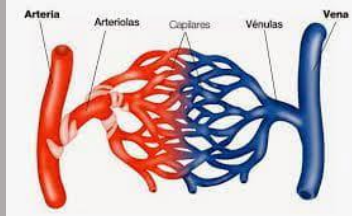
blood vessels



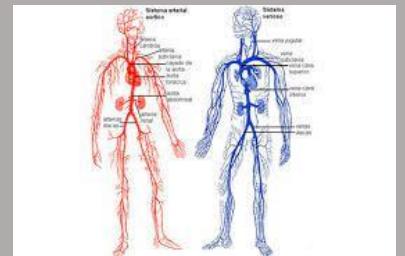
arteries



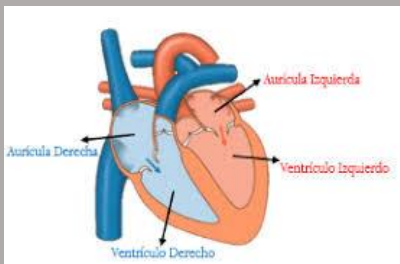
Capillaries



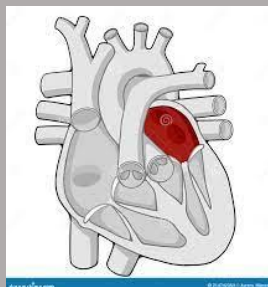
Venulas



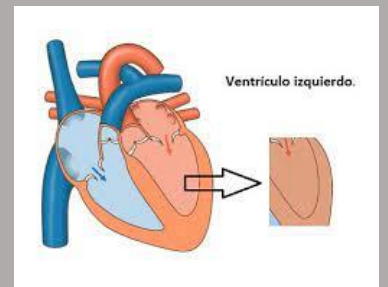
venas



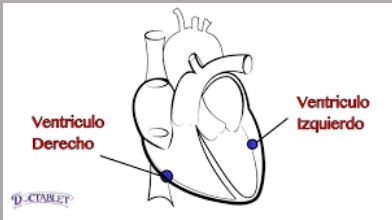
Left atrium



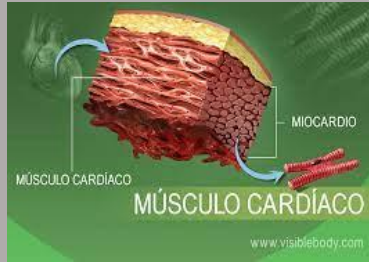Right atrium



Left Ventricle

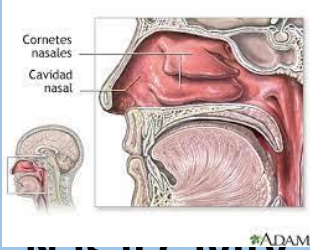


Right ventricle

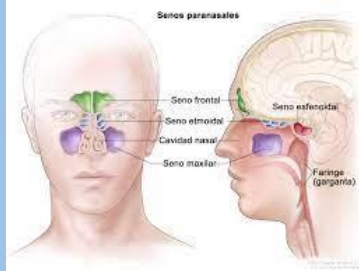


Heart muscle

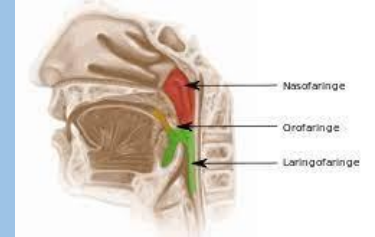
SISTEMA RESPIRATORIO



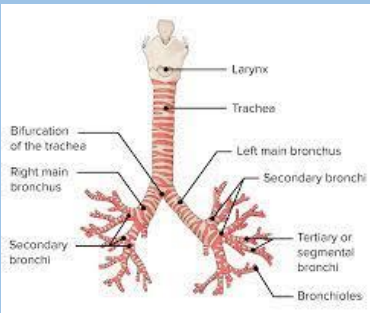
Nasal cavity



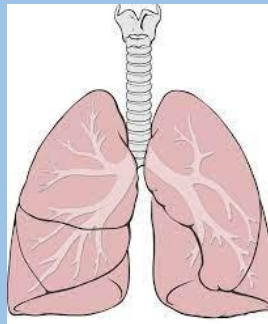
Sinuses



Pharynx



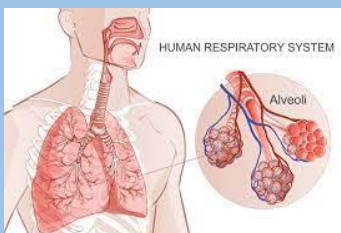**Tracheobronchial
arbol**



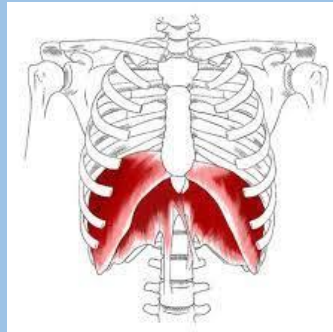
Lungs



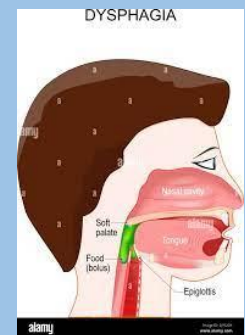
larynx



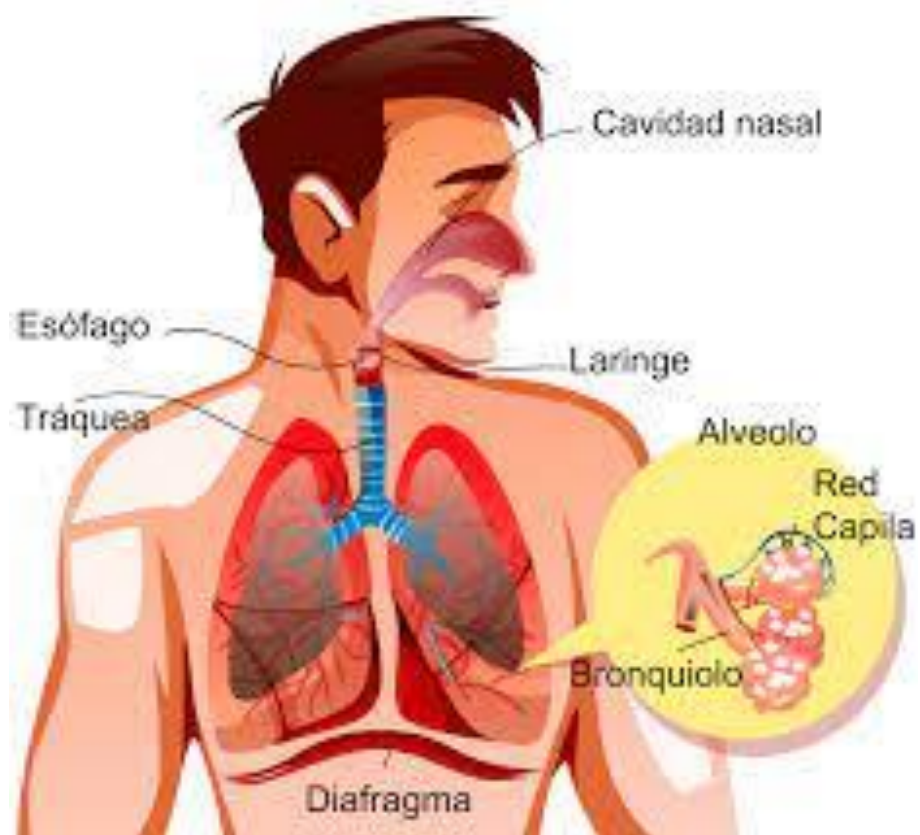
alveolos



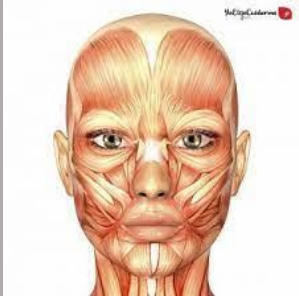diaphragm



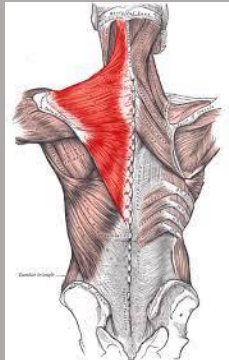epiglottis



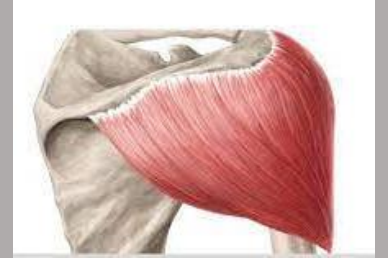SISTEMA MUSCULAR



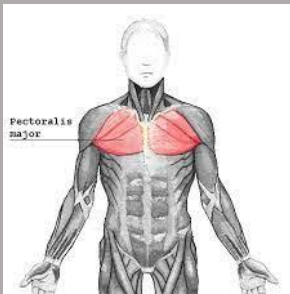
forehead



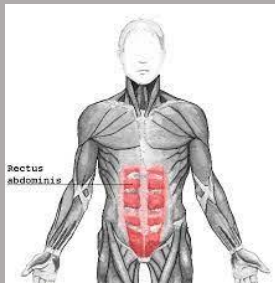
trapeze



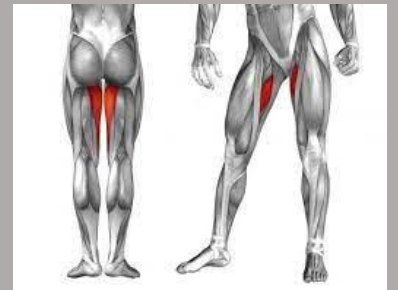Deltoids



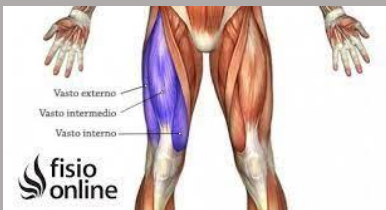Pectoralis major



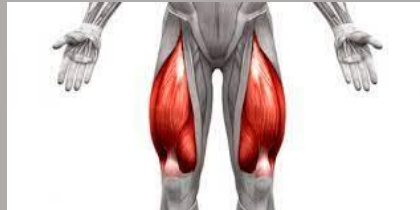Rectus



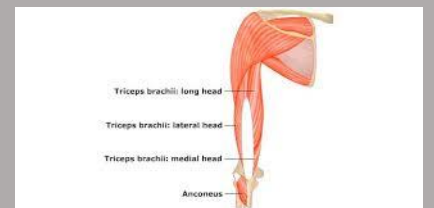
adductor



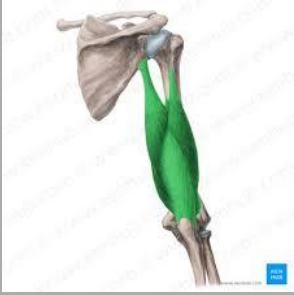Vast wide



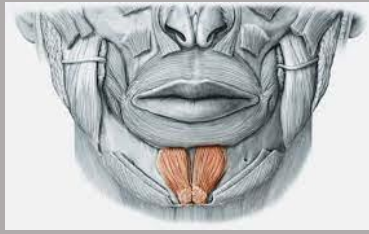quadriceps



Biceps brachii



Triceps brachii



chin

SISTEMA DIGESTIVO

