



**MATERIA: INGLES**

**DOCENTE: Ignacio  
Javier Sossa**

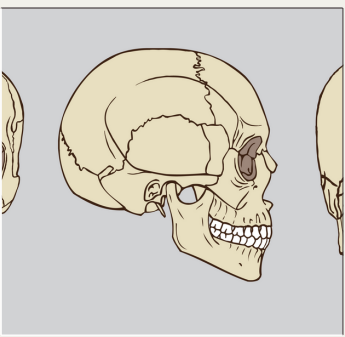
**ALUMNA: Karla  
Guadalupe Mérito  
Gómez**

**LICENCIATURA:  
ENFERMERÍA**

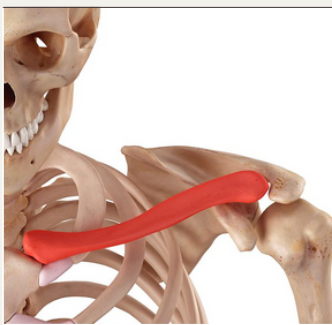
**CUATRIMESTRE:  
Segundo  
cuatrimestre**

# THE SKELETON

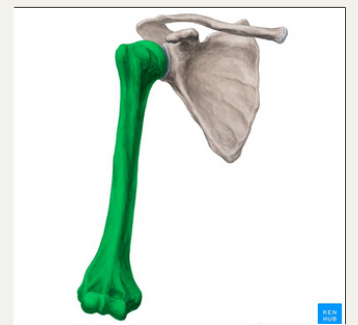The parts of the skeleton are:



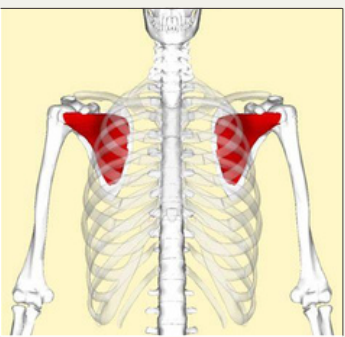
**cranium**



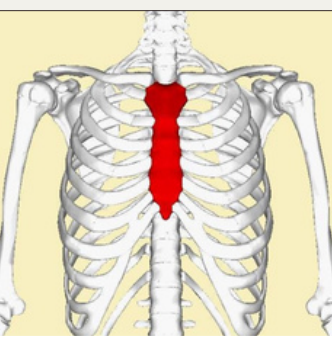
**Clavicle**



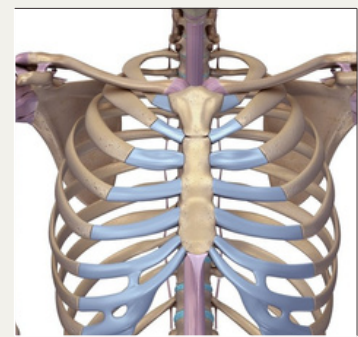
**Humerus**



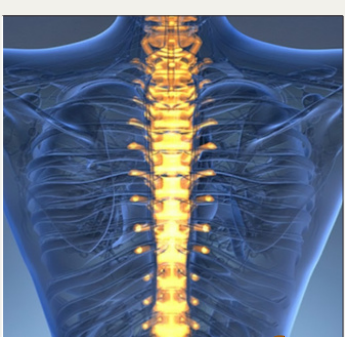
**Scapula**



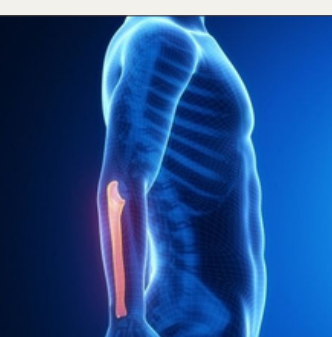**Sternum**



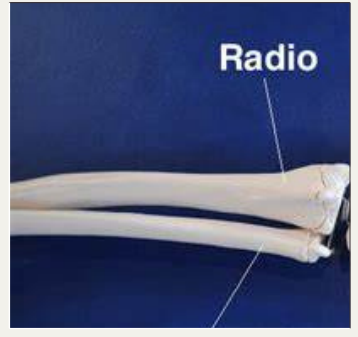
**Ribs**



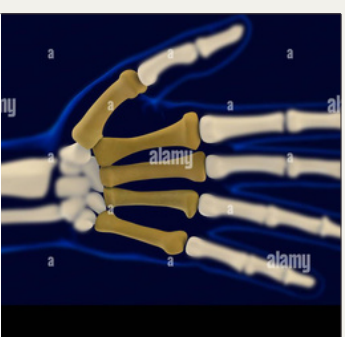
**vertebral column**



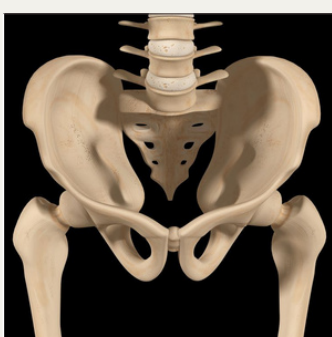**Ulna**



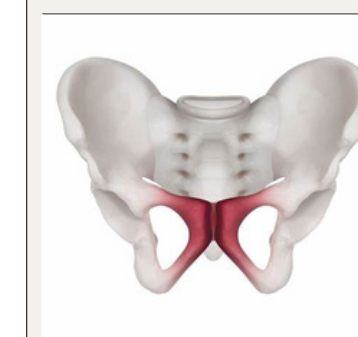
**Radius**



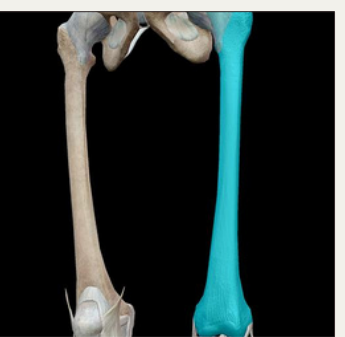**Metarcalps**



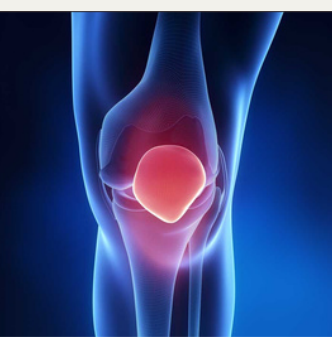
**Pelvis**



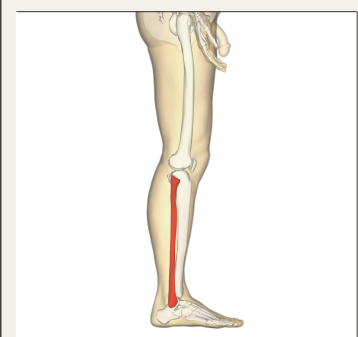**Pubis**



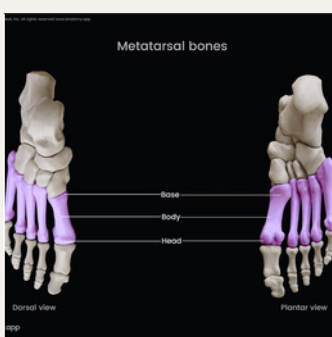**Tibia**



**Patella**

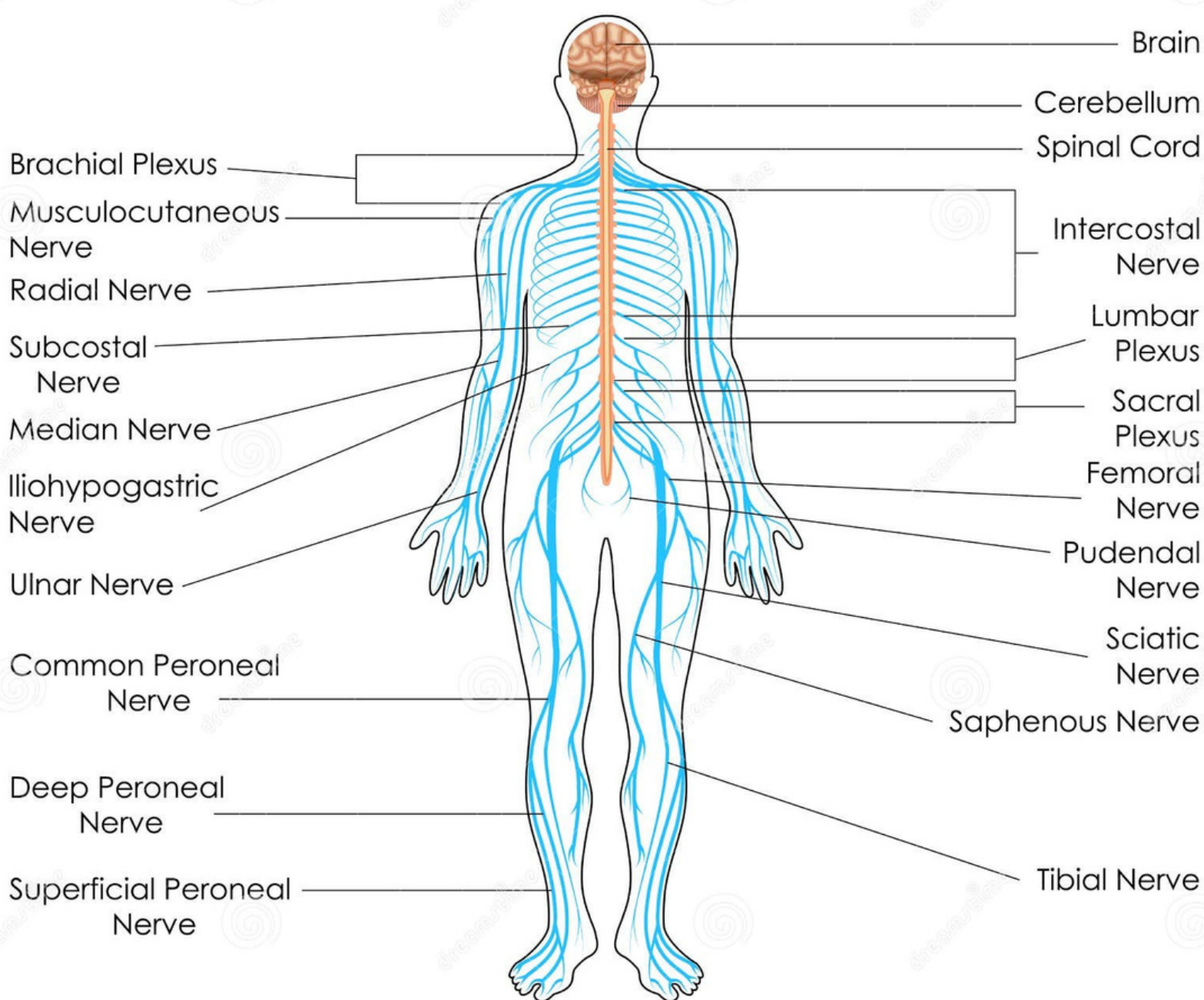


**Fibula**

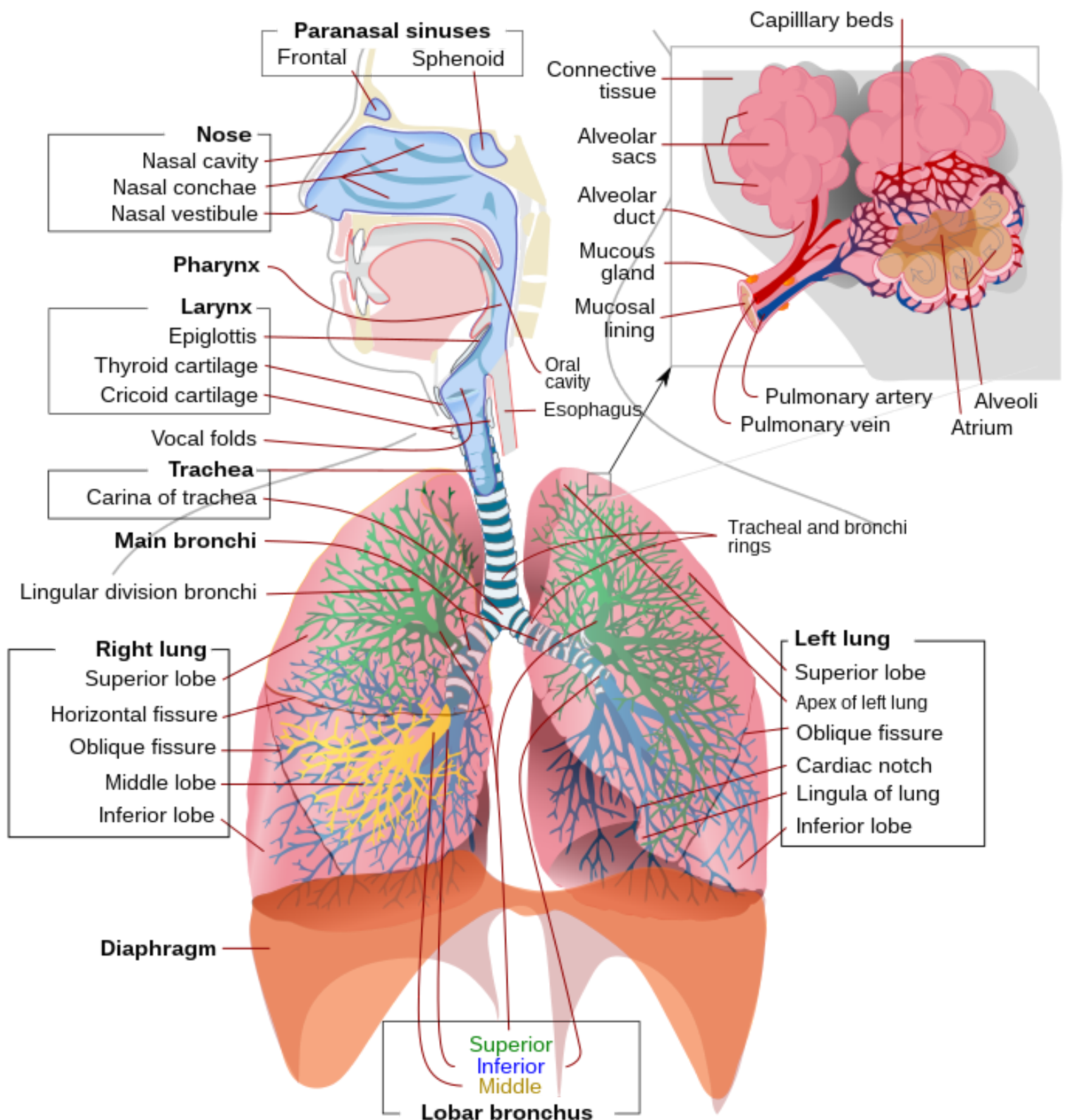


**Metatarsals**

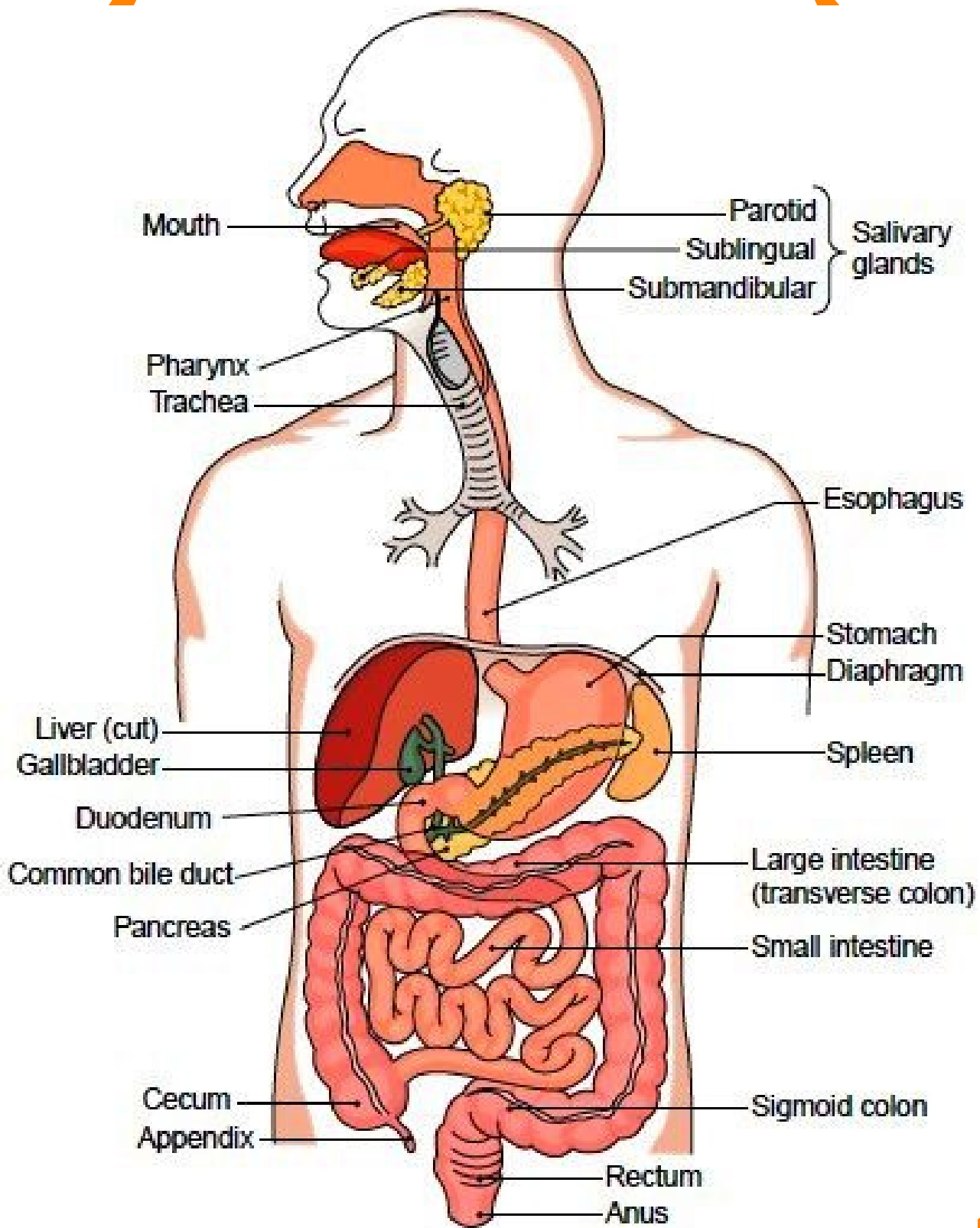
# NERVOUS SYSTEM



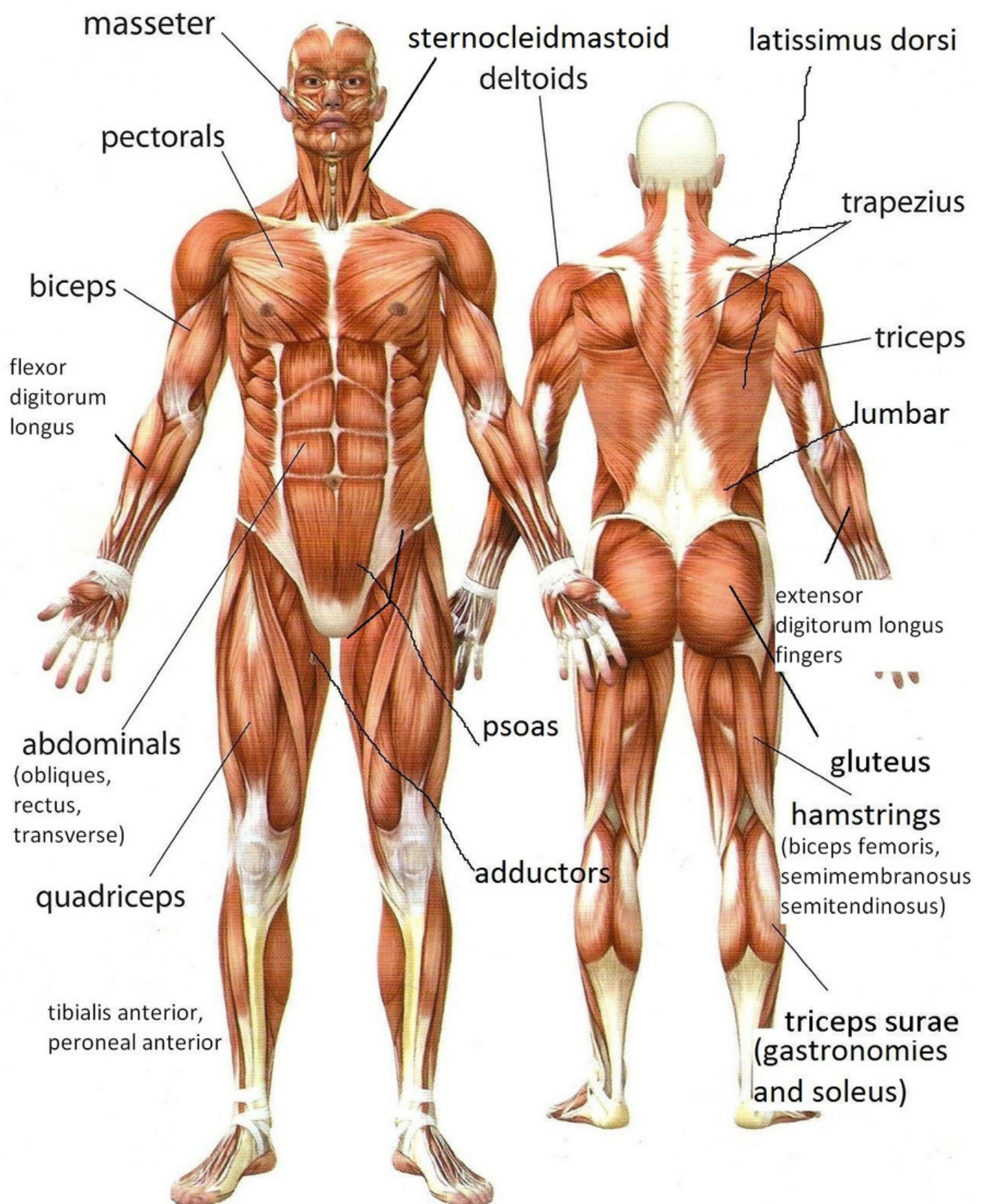
# Respiratory system



# Digestive System



# Muscular system



# Circulatory system

