



Rojas Velázquez Joan Natael

Suarez Martínez Romeo

**Flujograma: interpretación ECG
taquiarritmias y bradiarritmias**

PASIÓN POR EDUCAR

Cardiología

5°B

BRADIARRITMIAS Y TAQUIARRITMIAS

Ritmo

Regular

Irregular

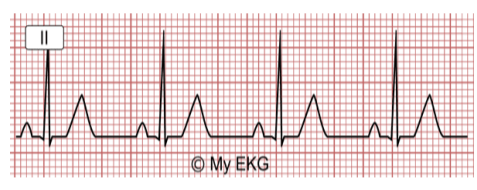Con onda P

Sin onda P

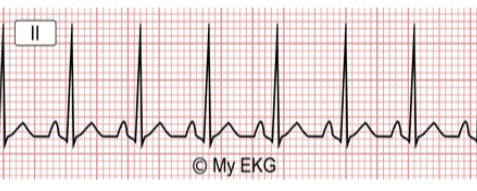Con onda P

Sin onda

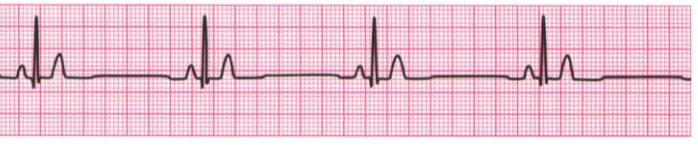Ritmo sinusal



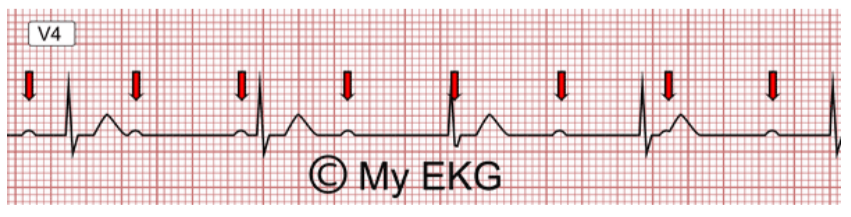
Taquicardia sinusal



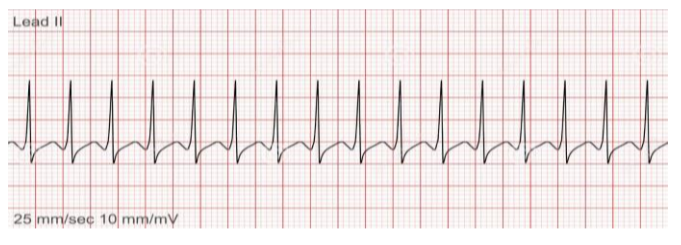
Bradicardia sinusal



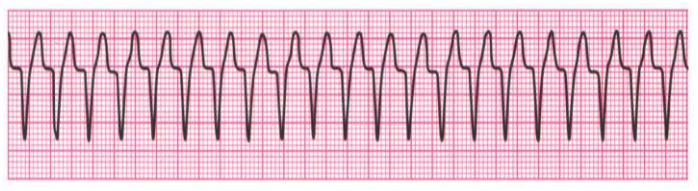
BAV 1er grado



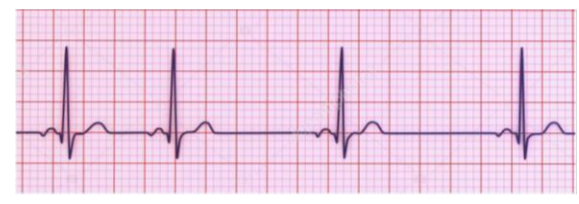Taquicardia supraventricular (QRS estrecho)



Taquicardia ventricular (QRS ancho)



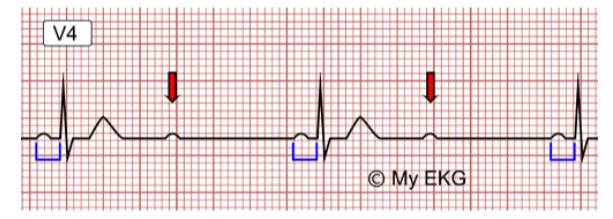
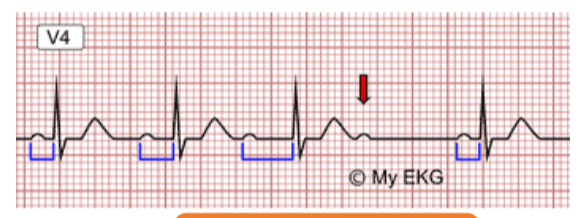
Arritmia sinusal



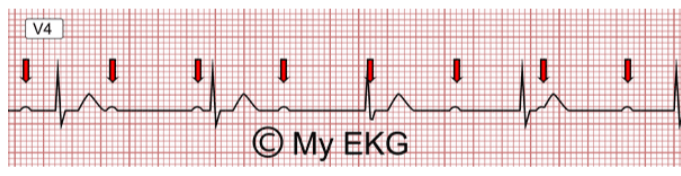
BAV 2do grado

Mobitz I

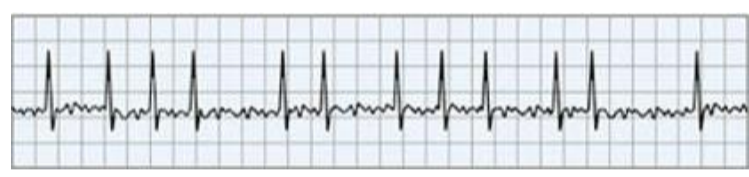
Mobitz II



BAV 3er grado



Fibrilación auricular



Fibrilación ventricular



