



Mi Universidad

ESTEFANIA OCHOA NAZAR

MORFOLOGIA

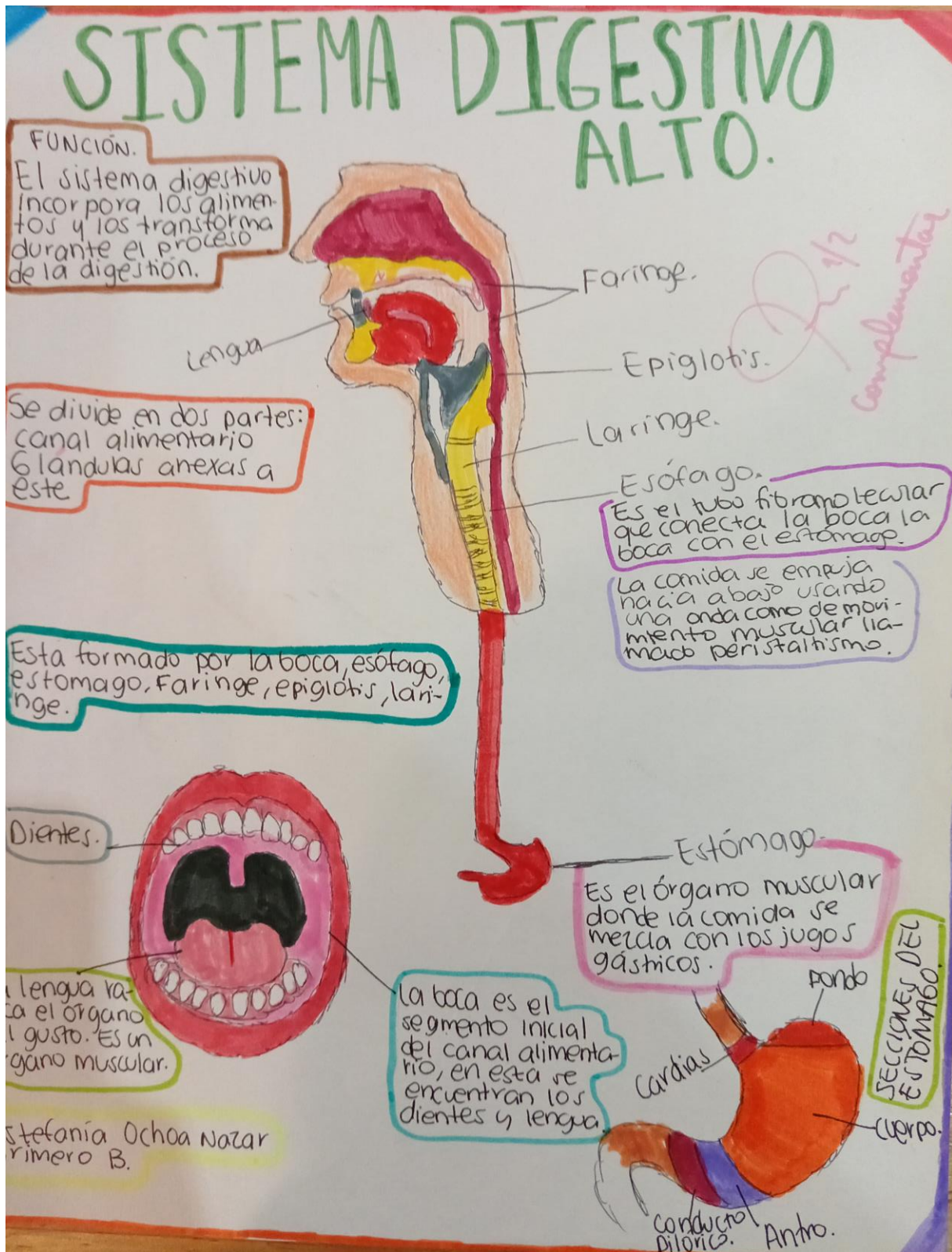
DRA.ROSVANI MARGINE MORALES

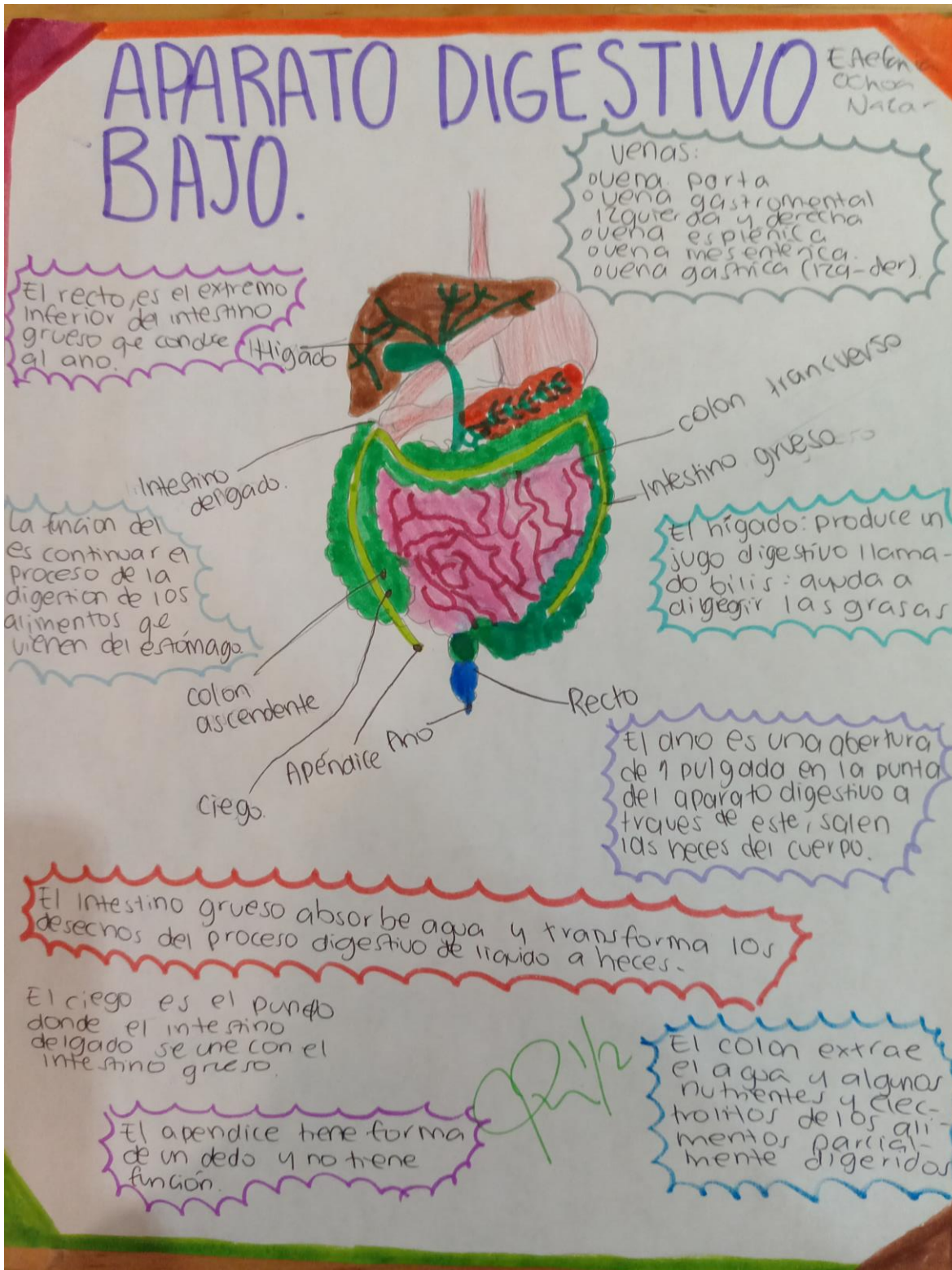
IRECTA

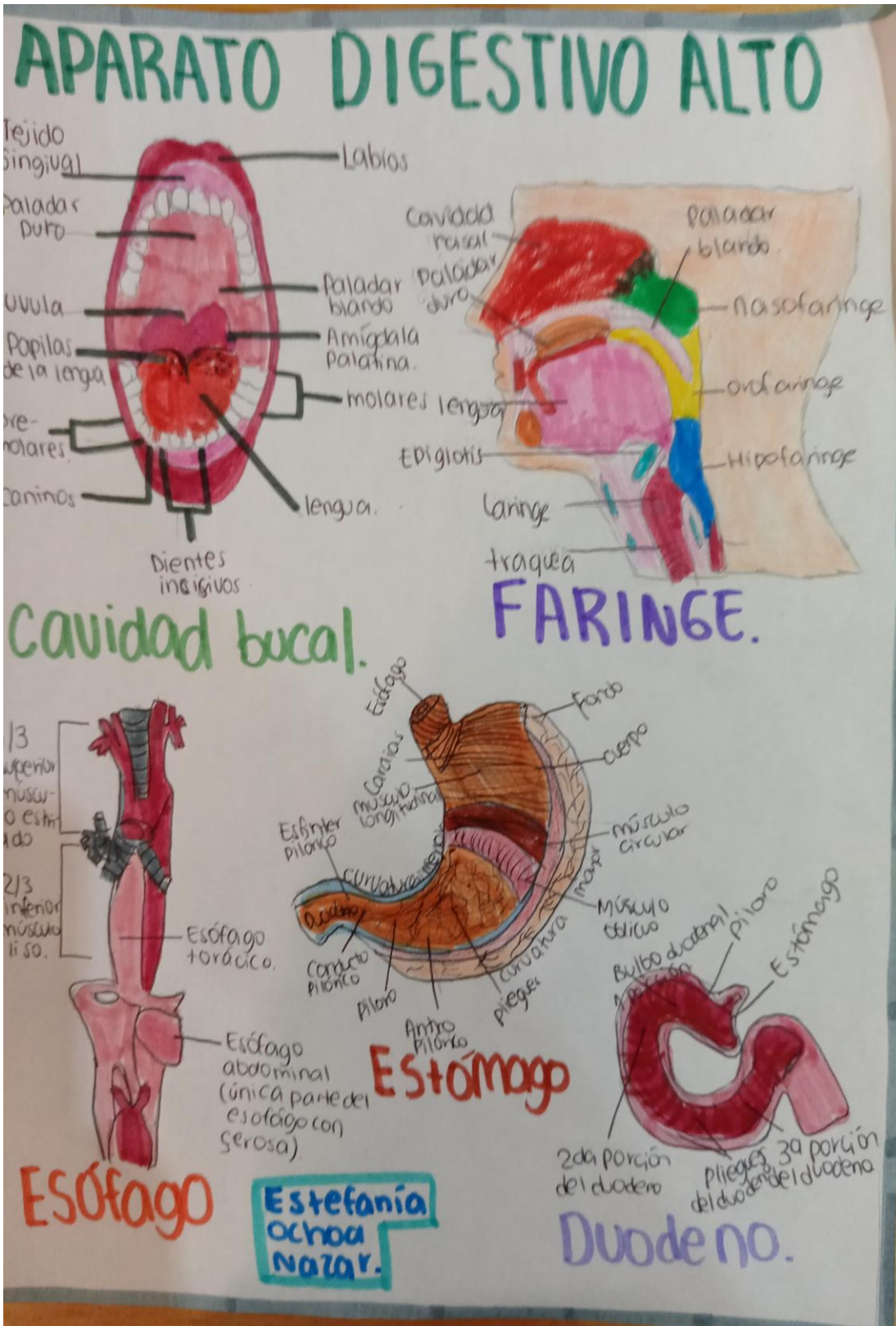
TRABAJOS EN CLASE:APARATO

DIGESTIVO

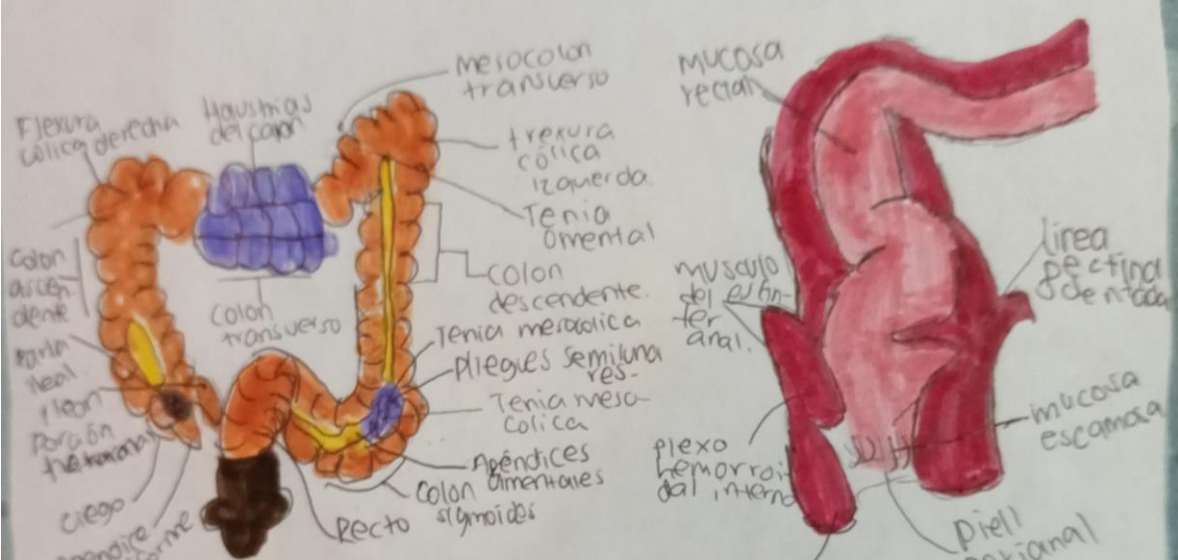
PRIMER SEMESTRE GRUPO B





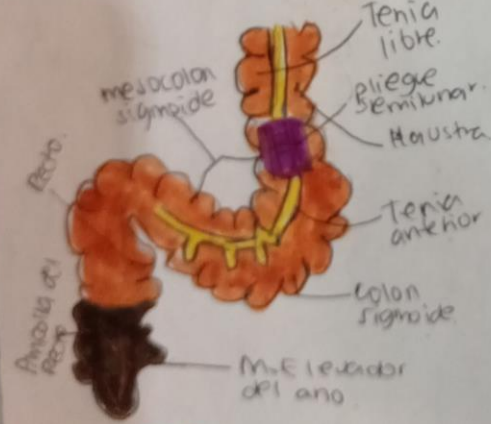


APARATO DIGESTIVO BAJO.

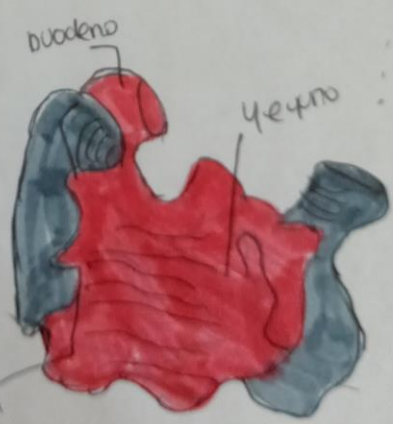

Intestino grueso

ANO



Colon



Fleón se vacía dentro del ciego (Intestino grueso)

Intestino delgado.

Estefanía Ochoa Nazar.