



Mi Universidad

Aparato digestivo

Cassandra Solís Pinto

Parcial 3

Morfología

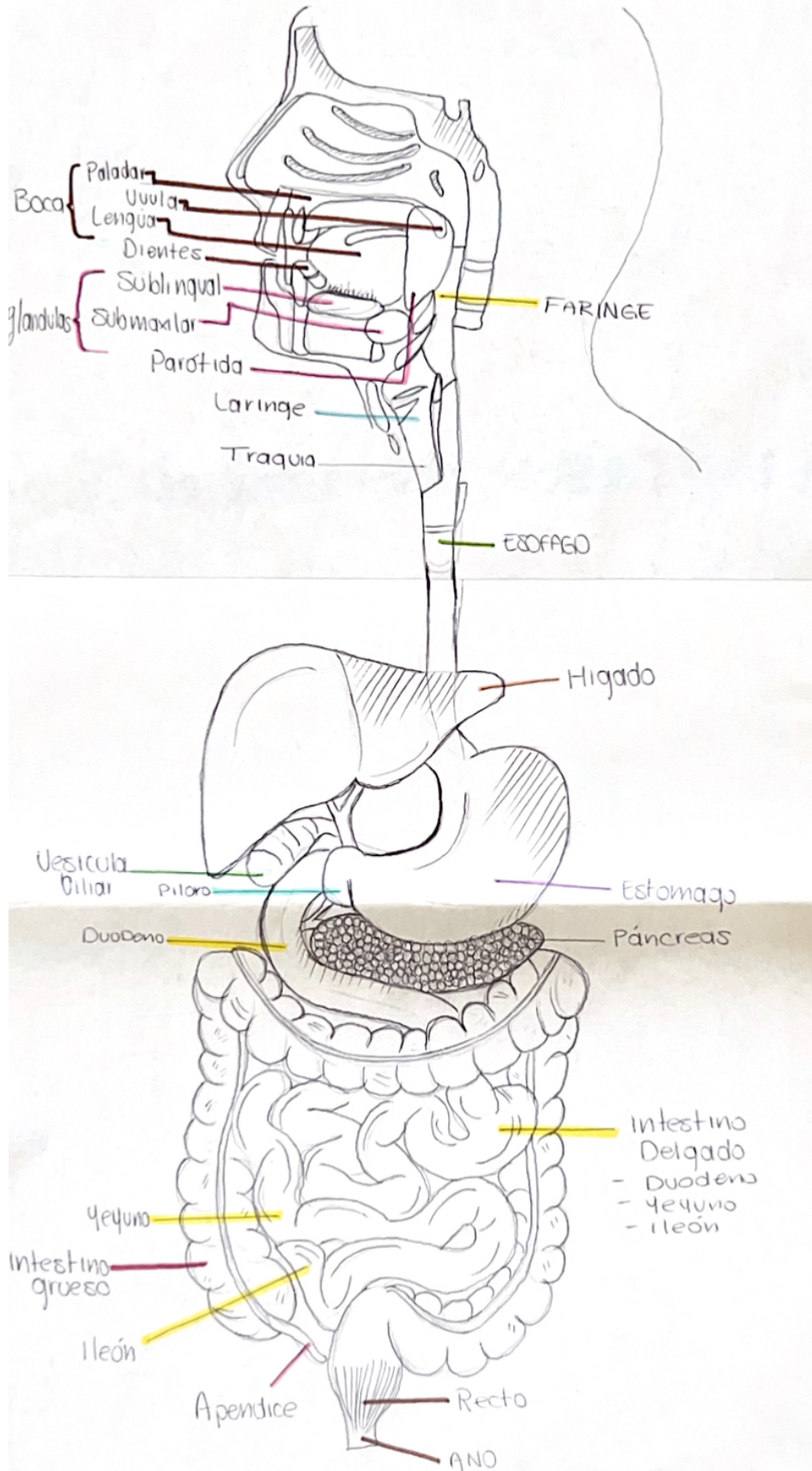
Dra. Rosvani Margine Morales Irecta

Medicina Humana

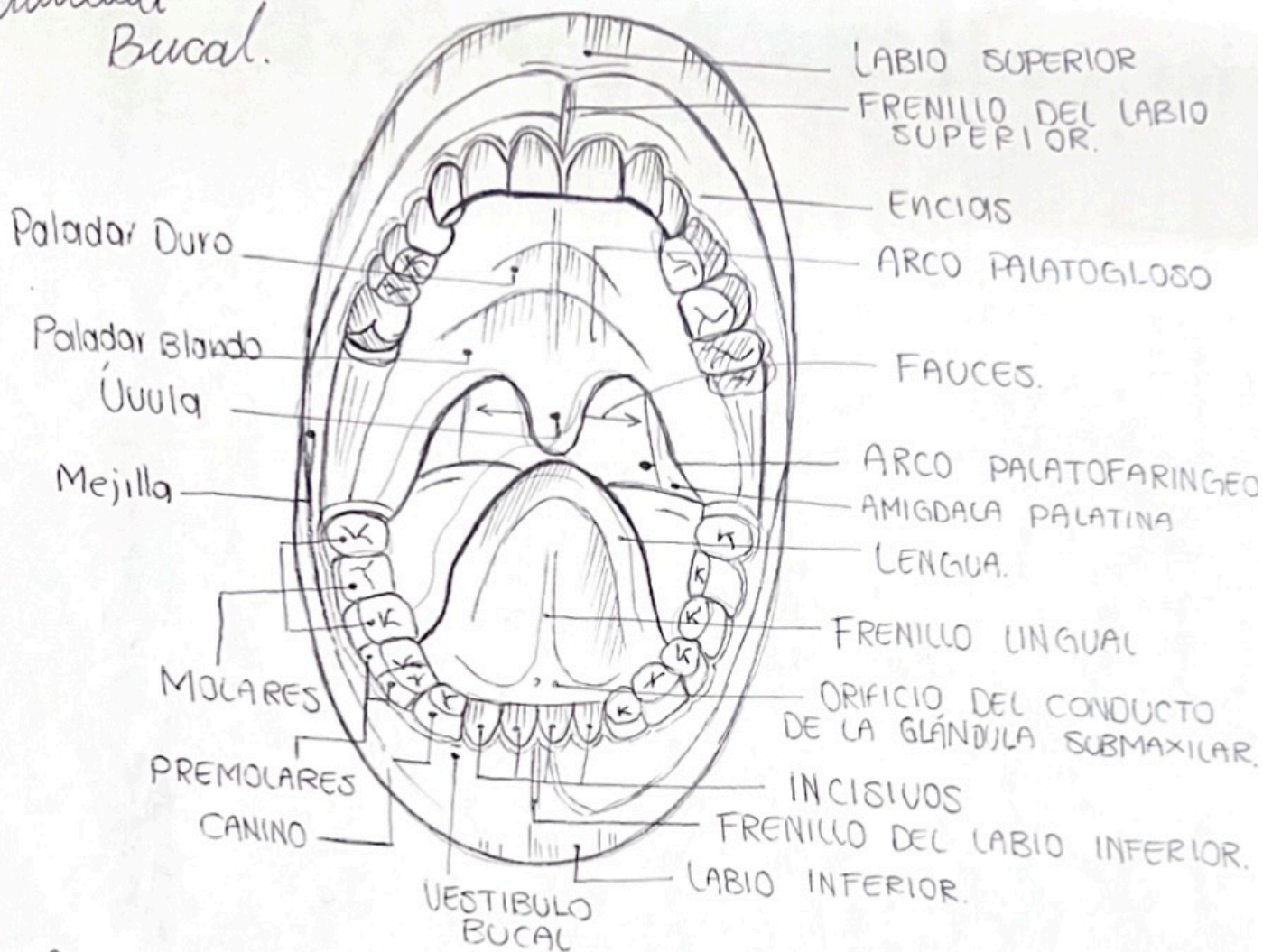
Primer Semestre

Comitán de Domínguez, Chiapas a 17 de Noviembre del 2023.

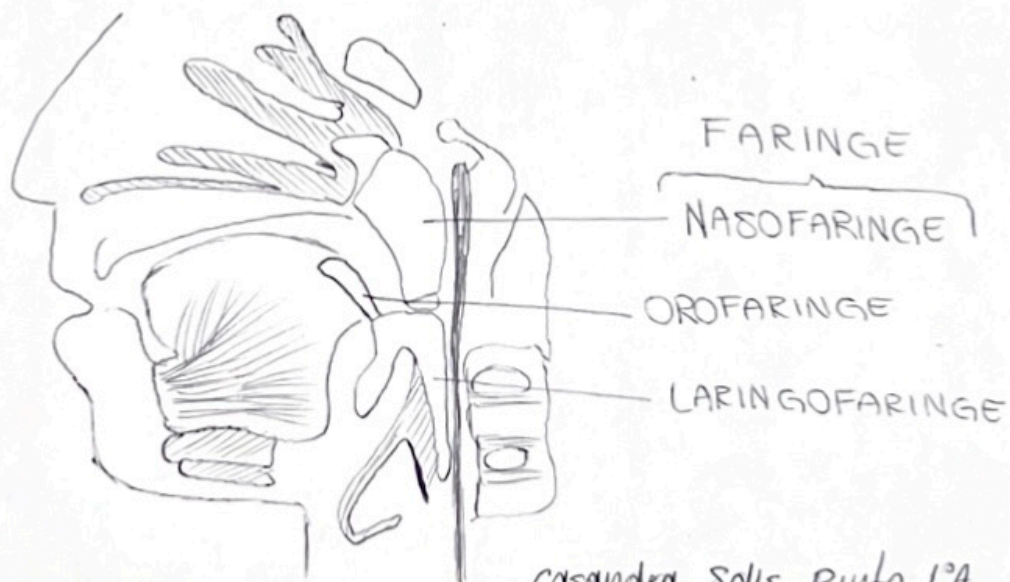
Aparato Digestivo



Cavidad Bucal.

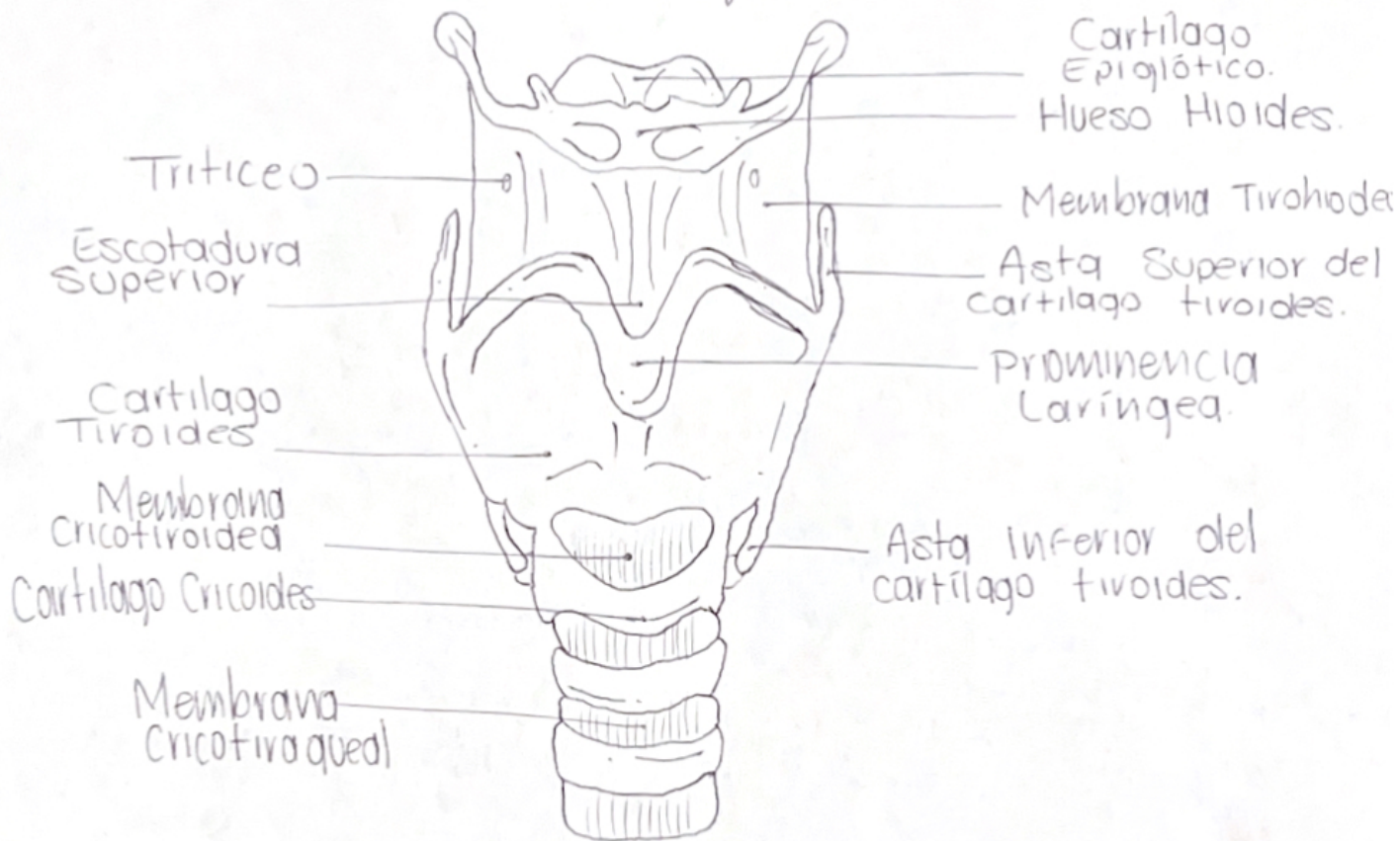


faringe

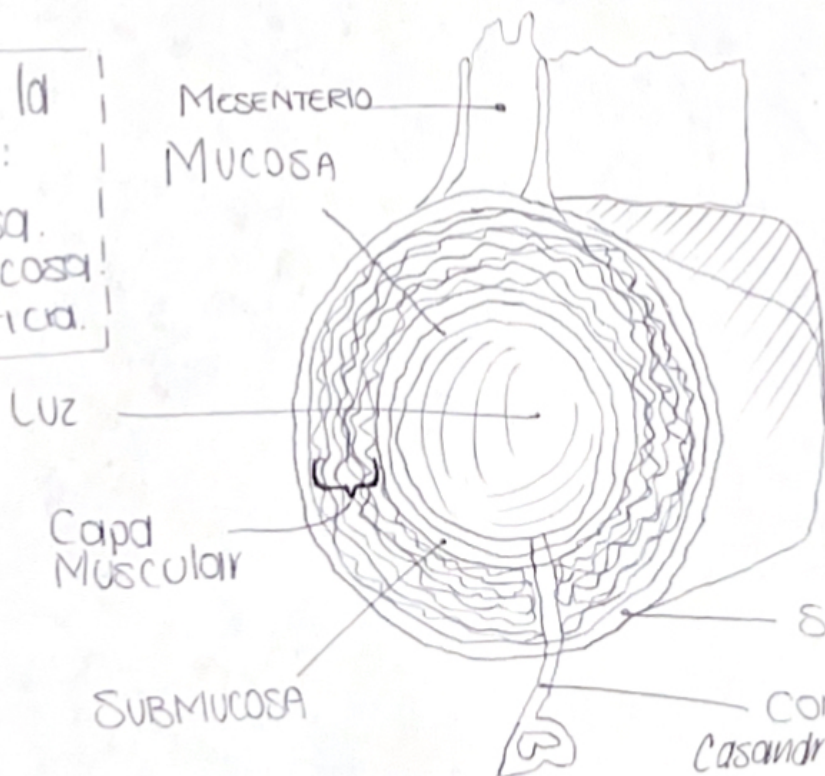


casandra Solis Pinto 1ª

Anatomía de la laringe



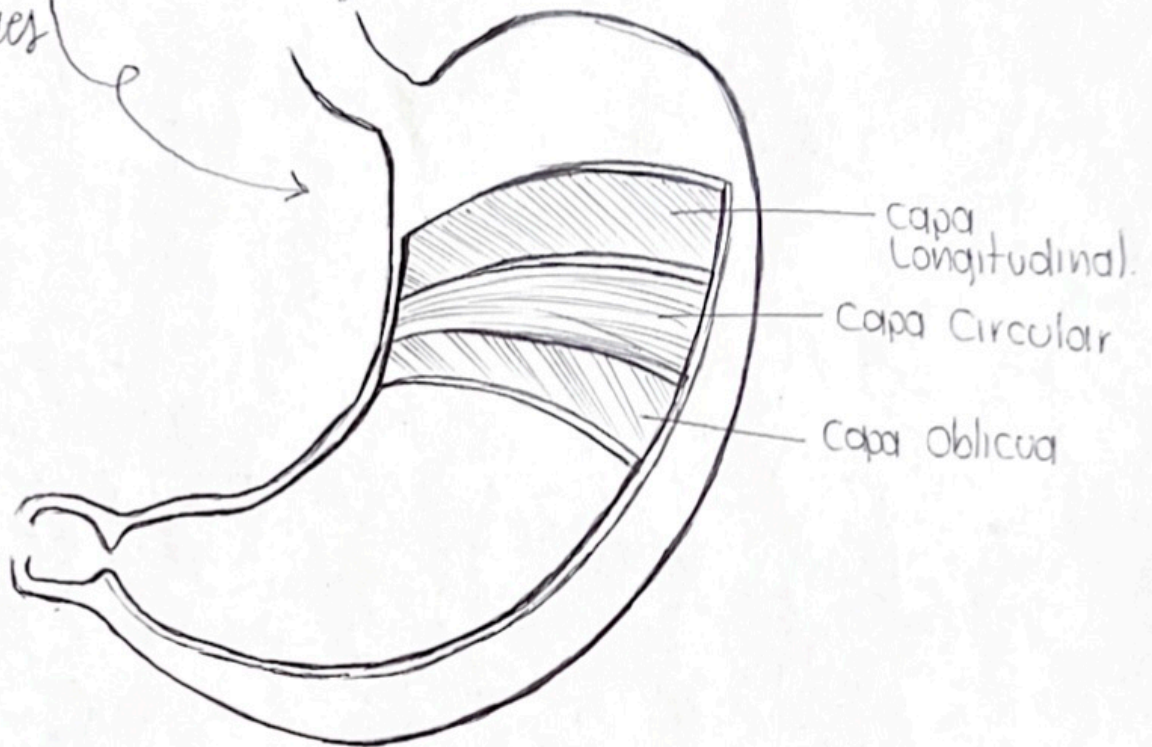
Capas de la laringe:
- Mucosa.
- Submucosa.
- Adventicia.



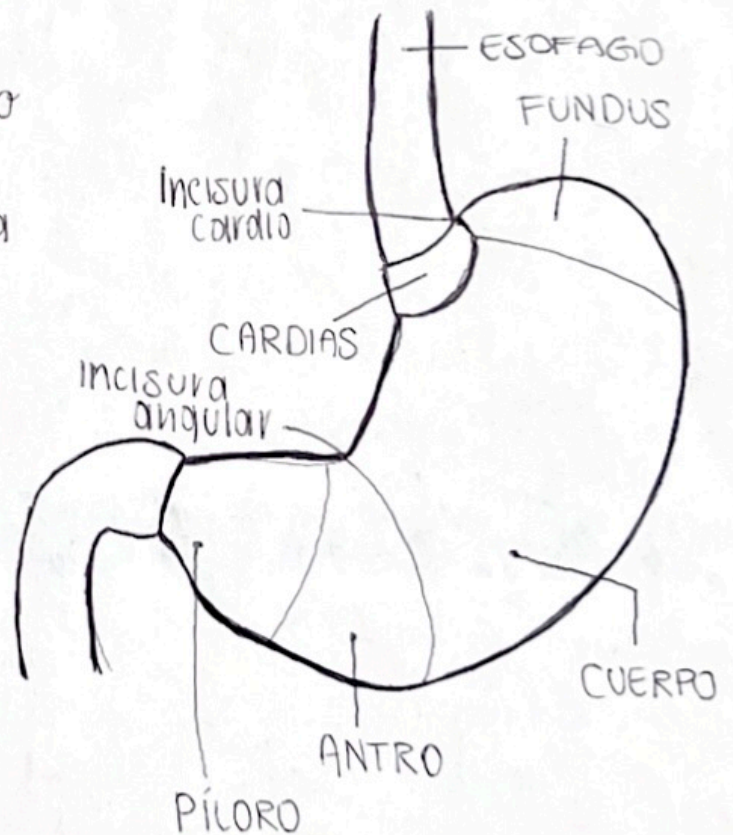
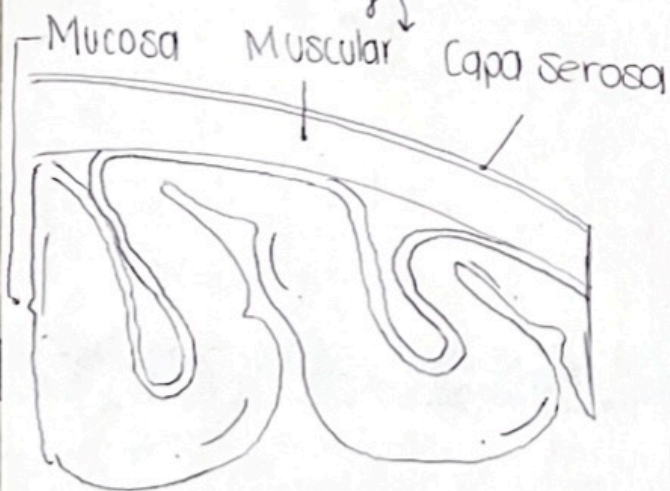Capas del Esófago

CONDUCTO
Casandra Solis Piuto 1ª

Capas del estomago
musculares



Capas del estomago



Higado

Cara diafragmática del lóbulo derecho.

Ligamento coronario.

Cara diafragmática del lóbulo izquierdo.

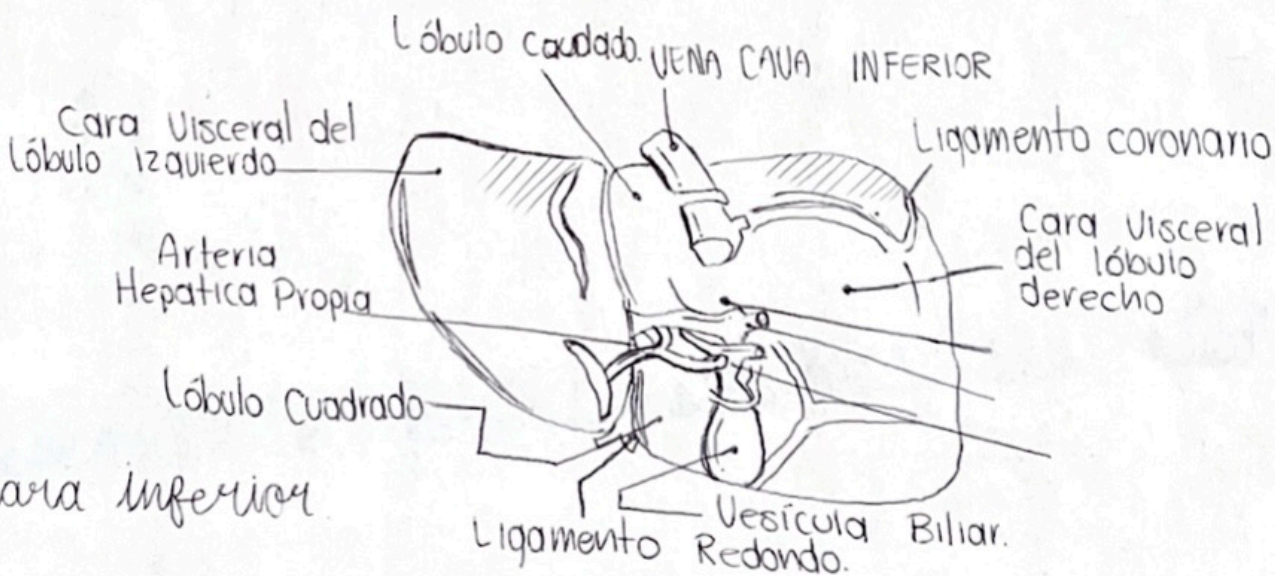
Ligamento falciforme.

Ligamento Redondo

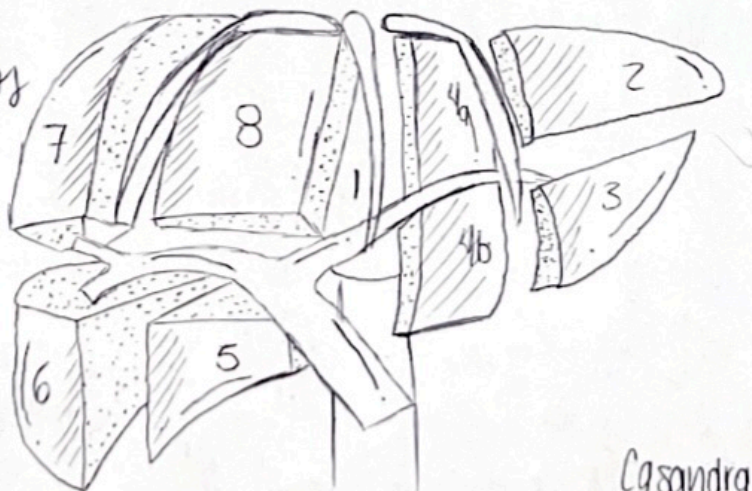
Vesícula BILIAR.

Borde inferior.

Cara anterior

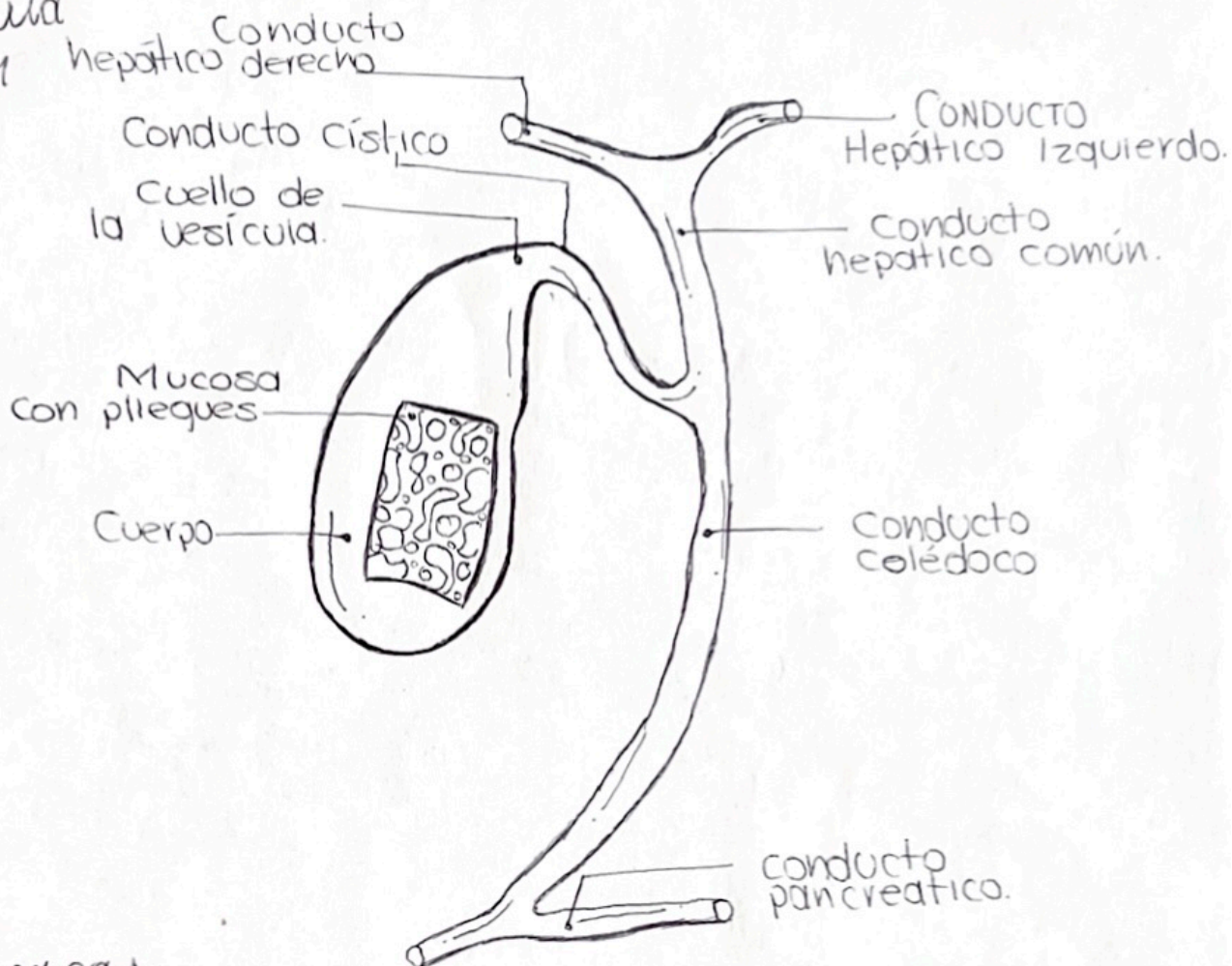


Segmentos

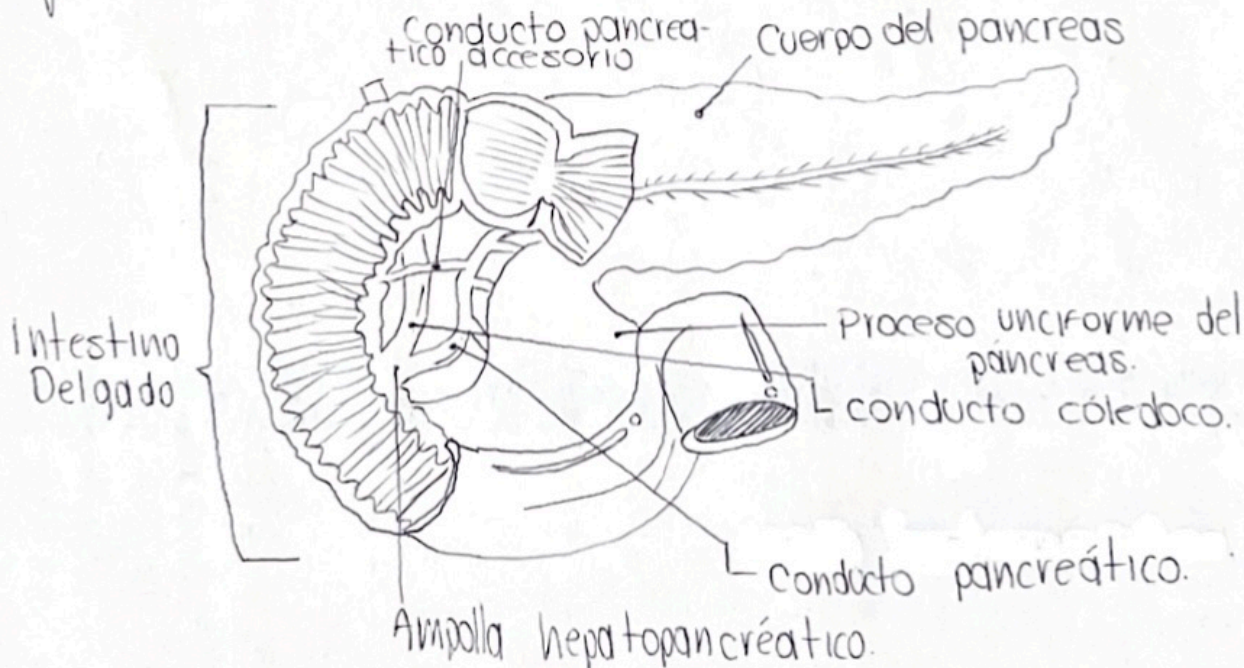


Cassandra Solis Pinto 1ª

Vesícula Biliar



pancreas

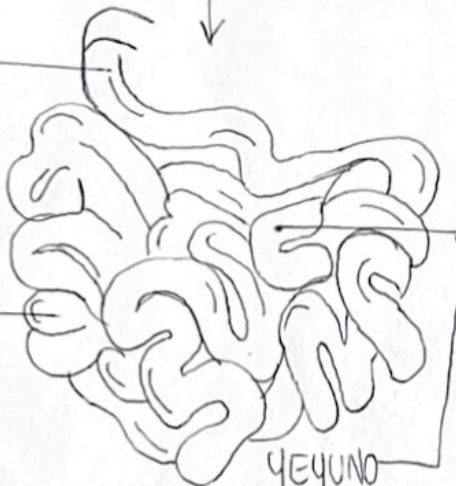


Tramos del intestino delgado:

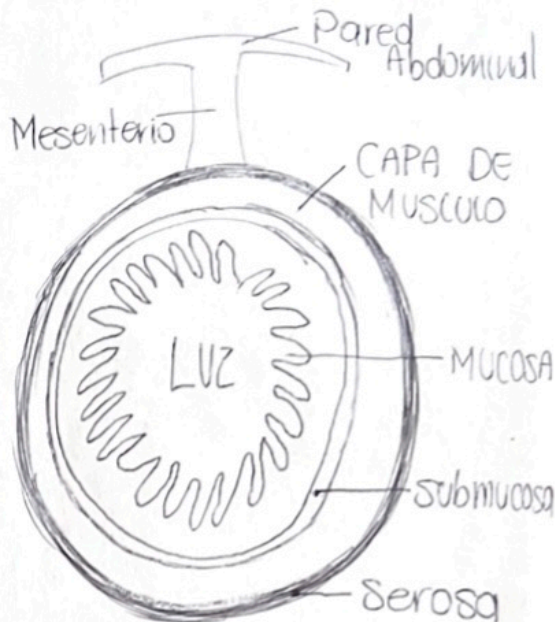
DUODENO

ÍLEON

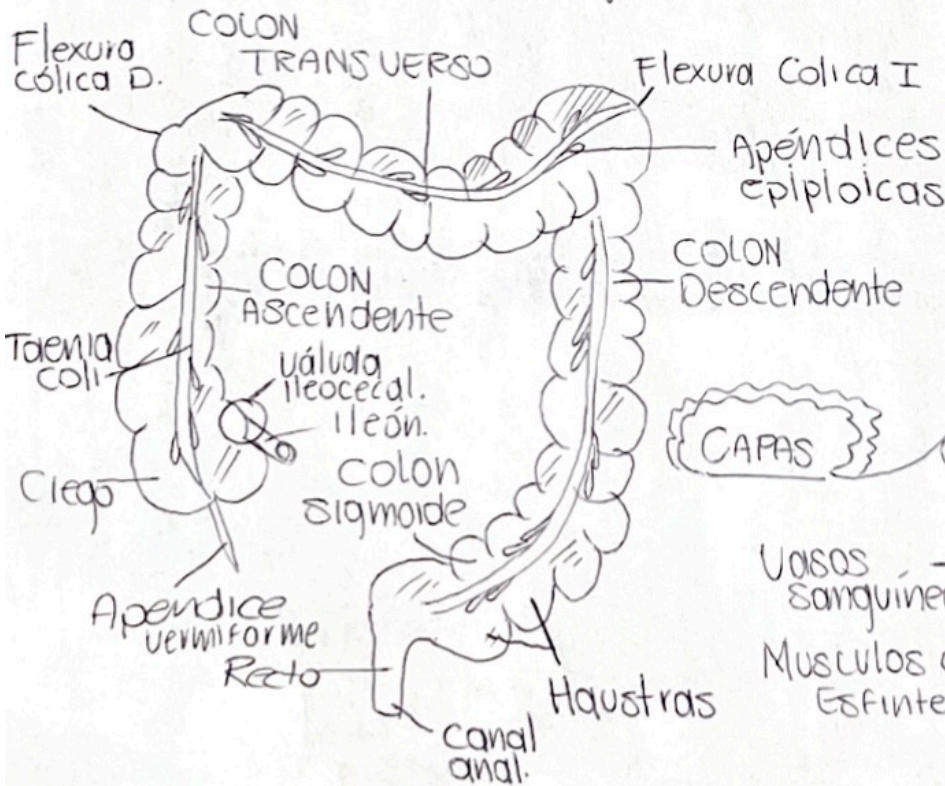
YEYUNO



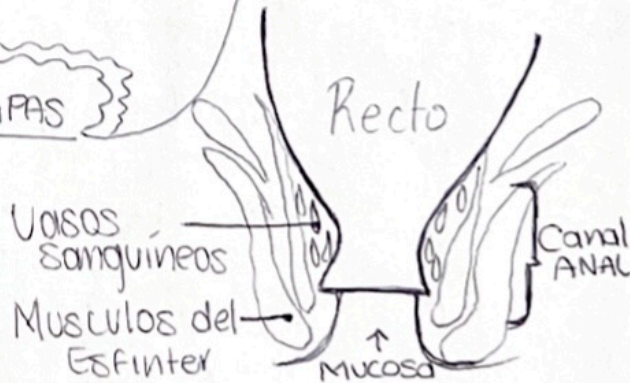
Capas:



Anatomía del intestino grueso



Anatomía del Recto



Referencia:

Moore, K. L., Dalley, A. F., II, & Agur, A. M. R. (2018). *Anatomía con orientación clínica*.

LWW.