

APARATO DIGESTIVO

~~Carla Sofía Alfaro Domínguez~~

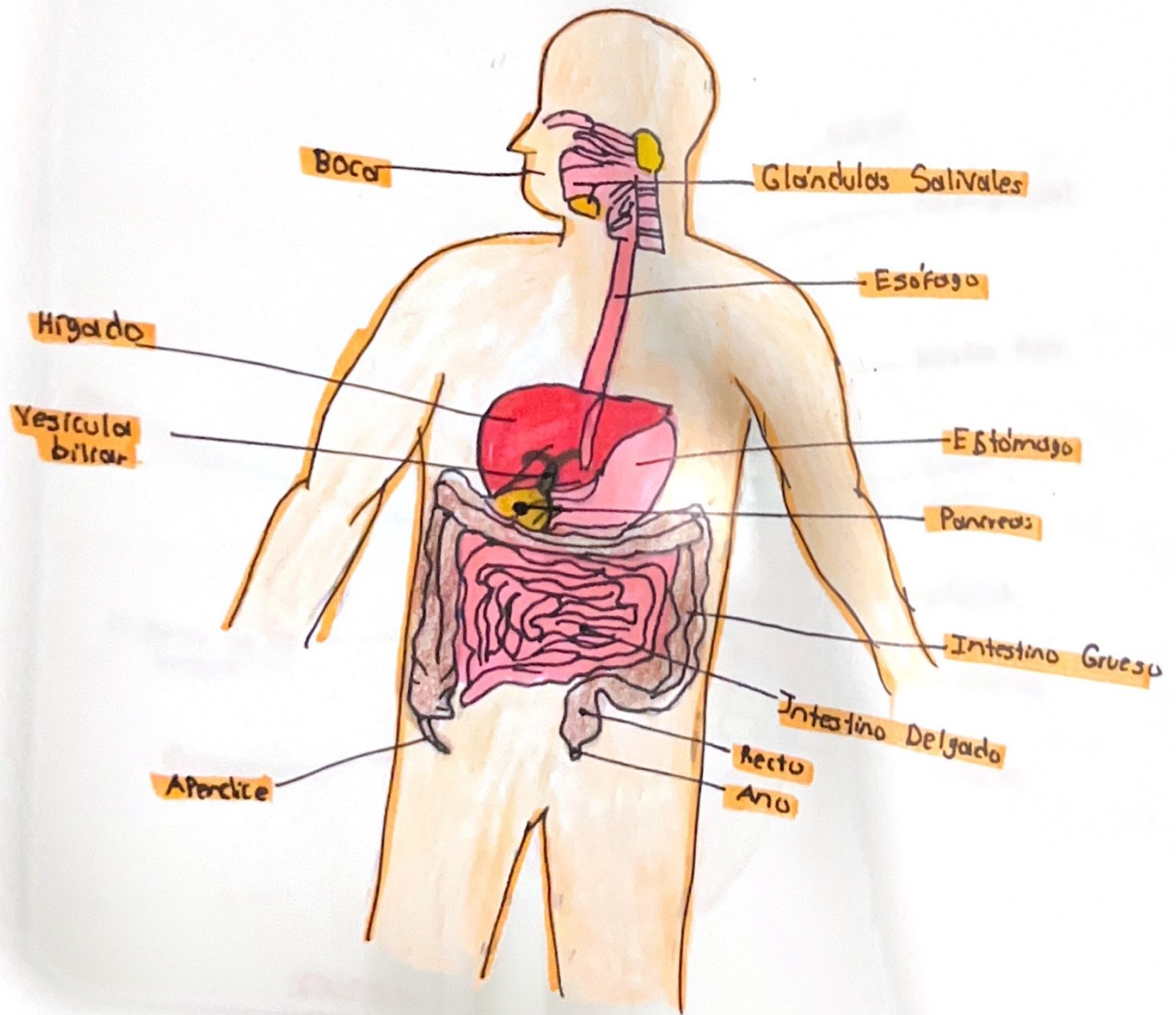
~~Dra. Rosvani M. Morales Irecto~~

~~Morfología~~

~~Parcial I~~

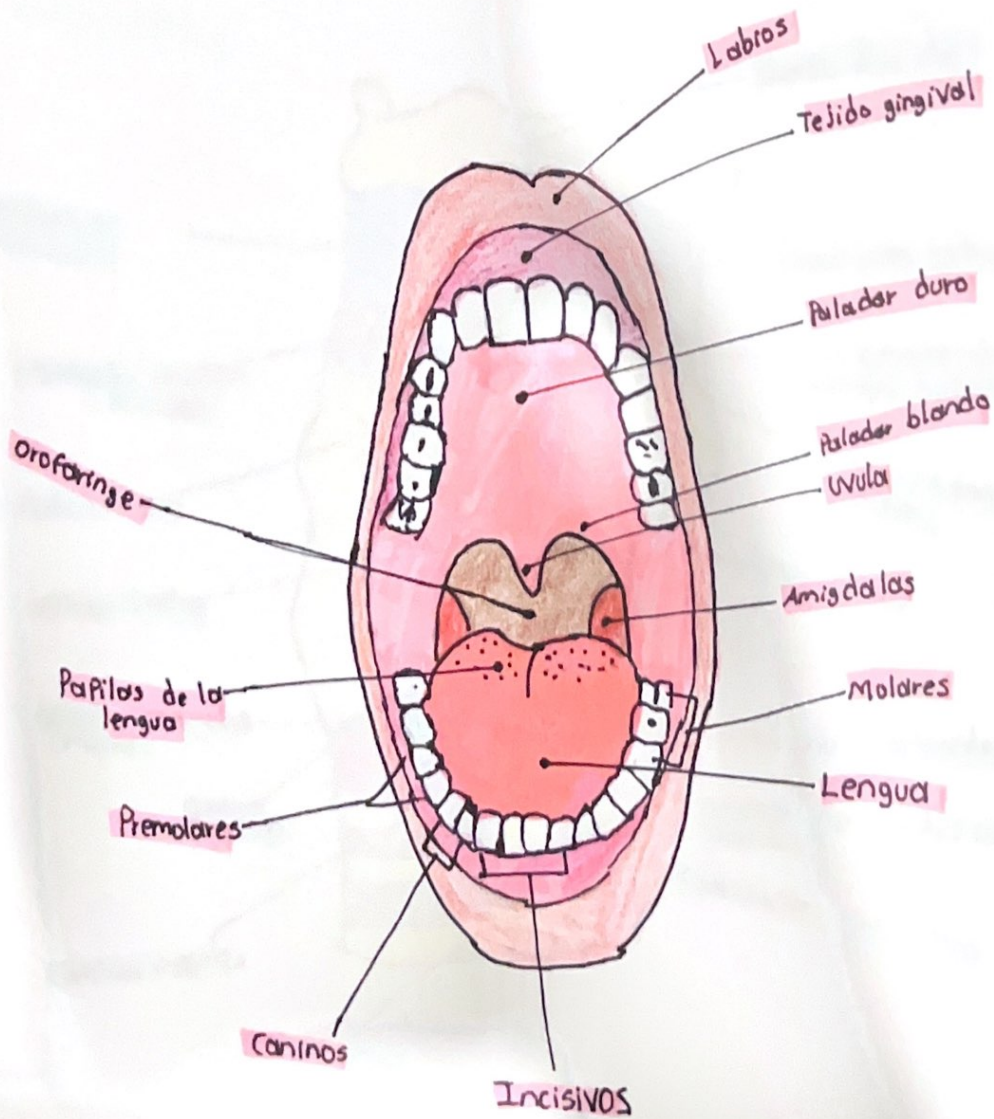
~~1-A~~

Aparato Digestivo



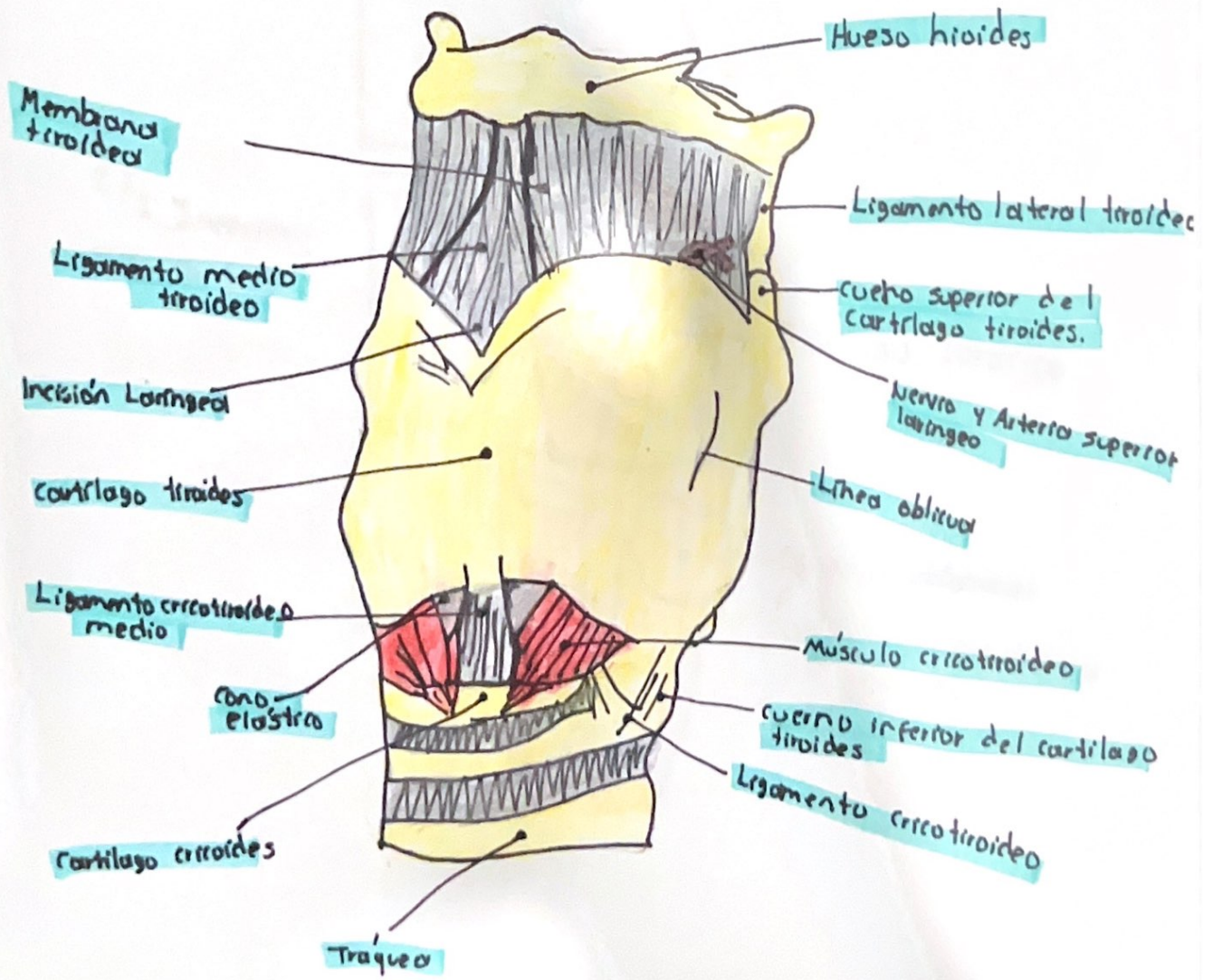
BOCA

cavidad oral.



13/10/23

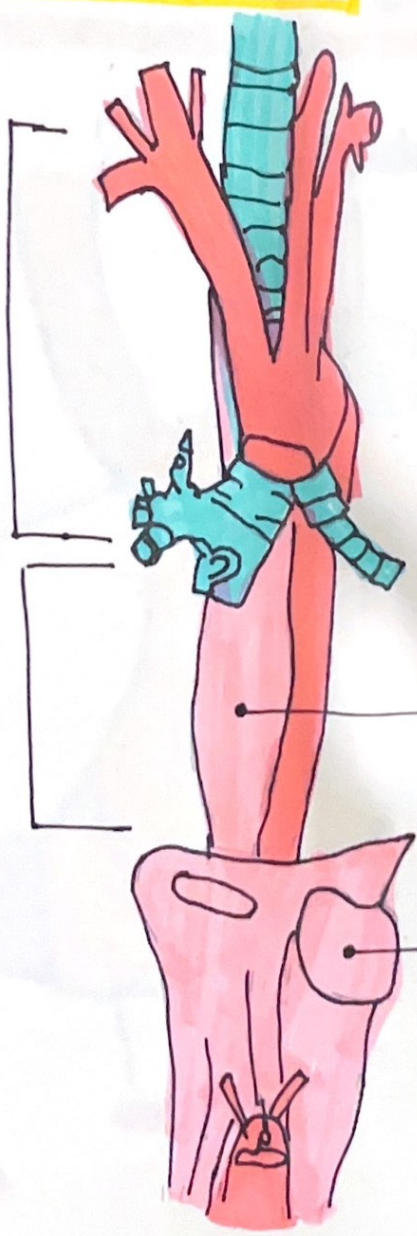
LARINGE



ESOFAGO

$\frac{1}{3}$
superior:
músculo estriado

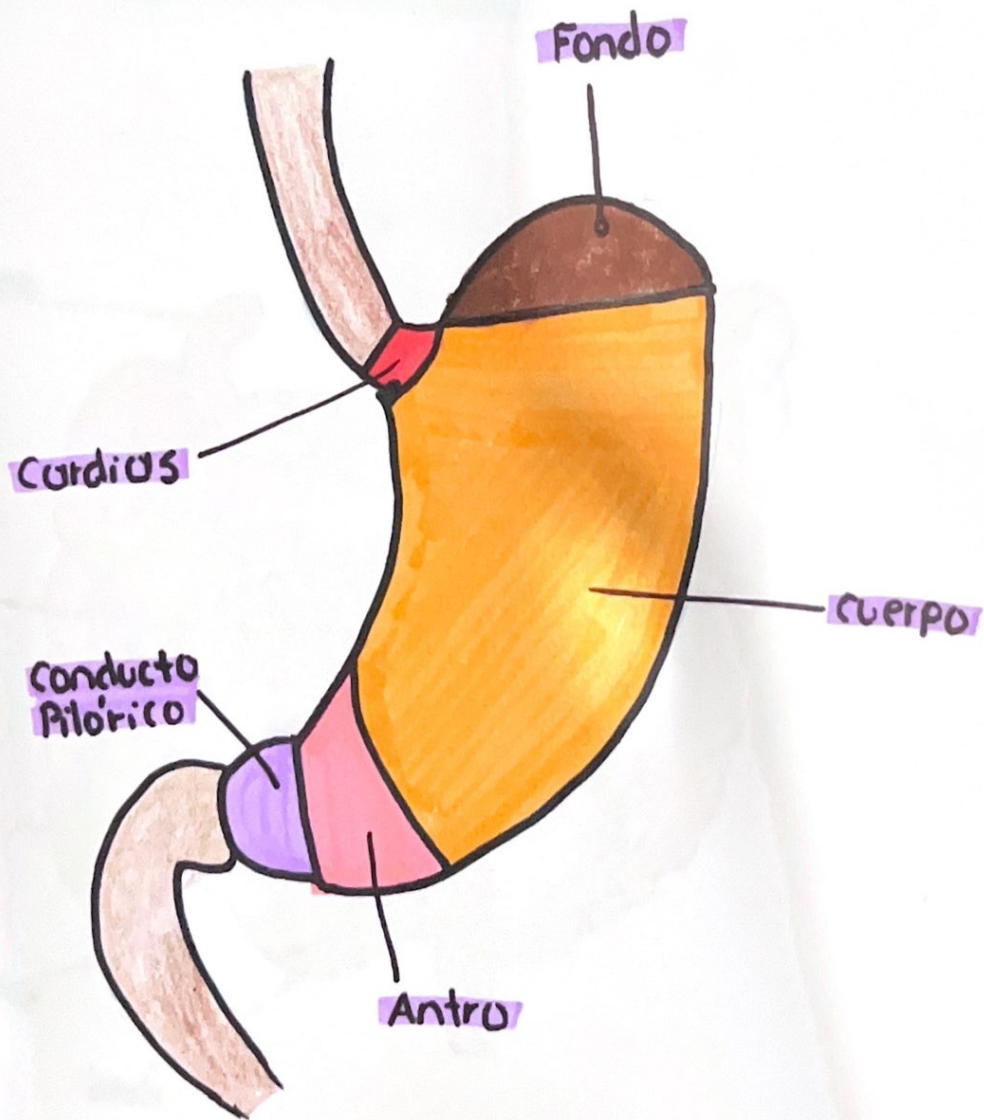
$\frac{2}{3}$ Inferior:
músculo liso



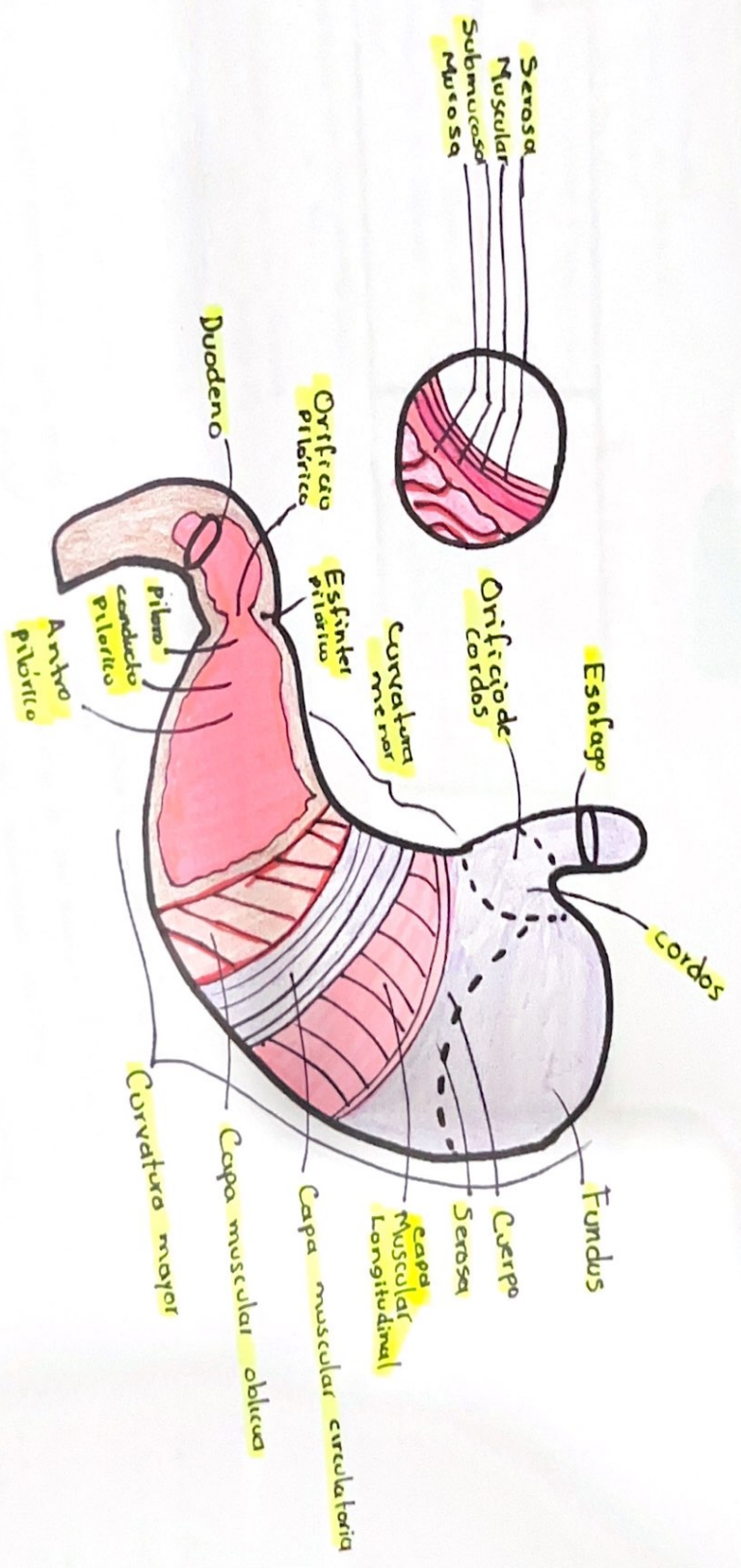
Esófago Torácico

Esófago abdominal
(única parte del esófago
con serosa)

ESTÓMAGO

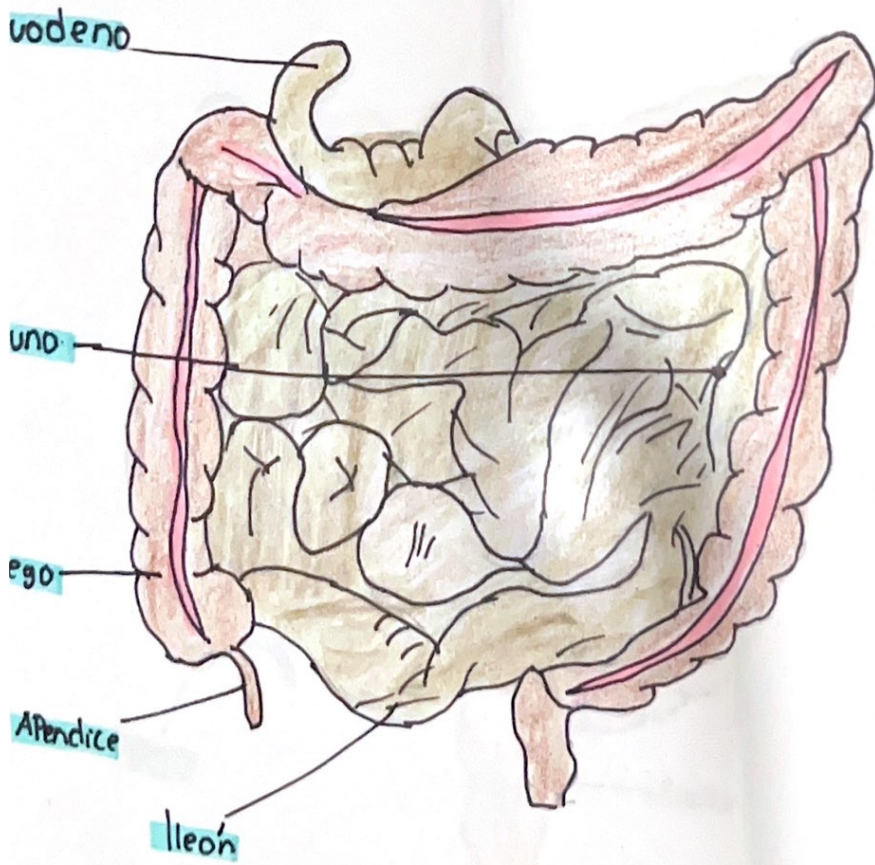


ESTÓMAGO

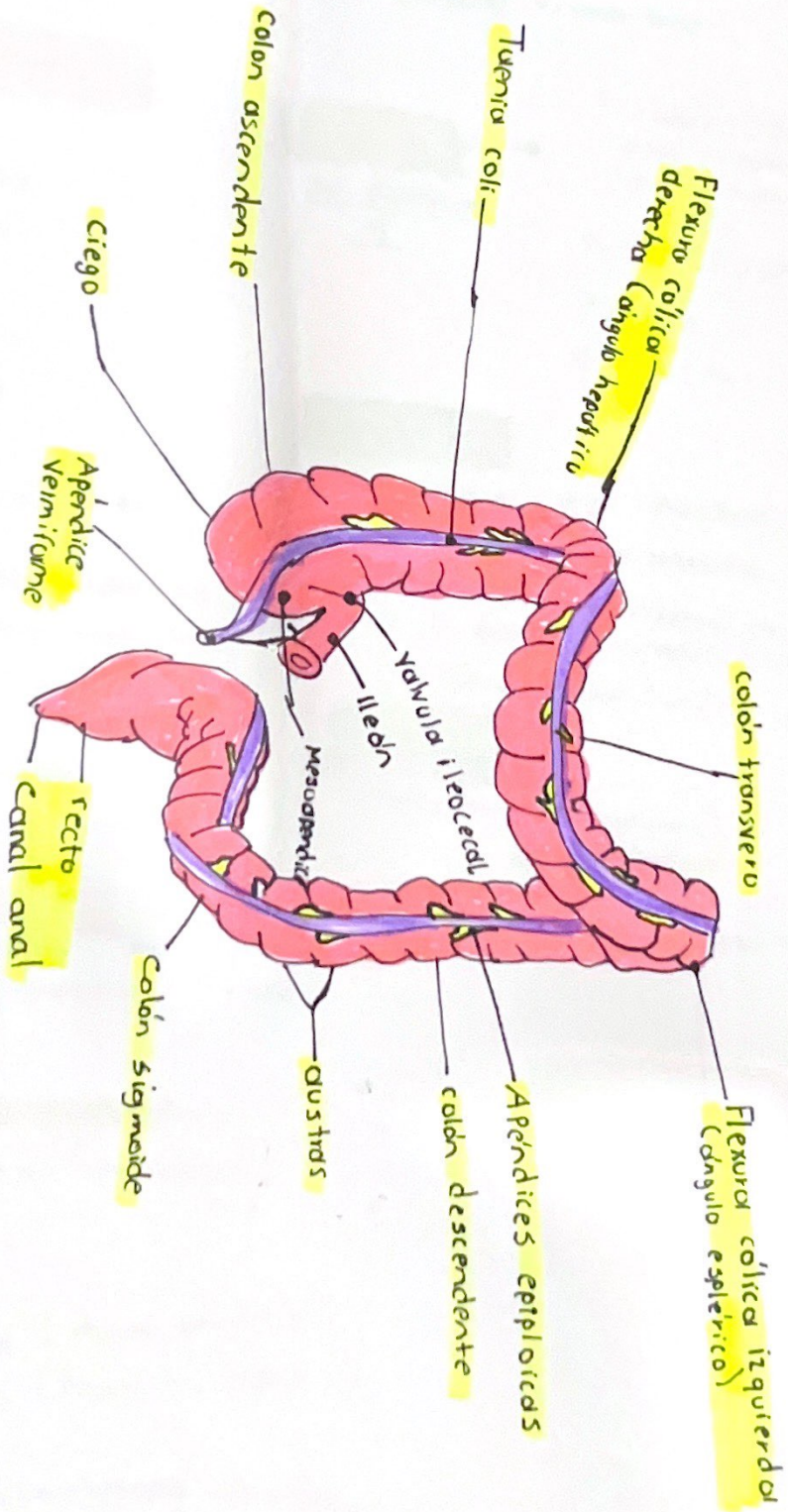


- 1.
- 2.
- 3.

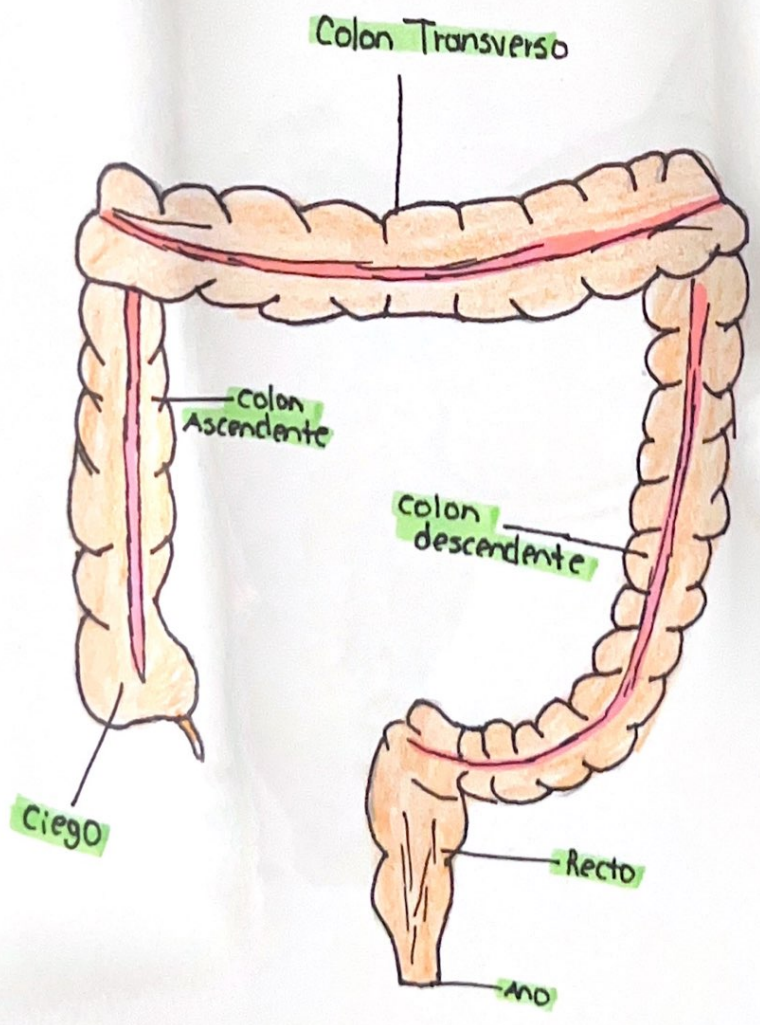
INTESTINO DELGADO



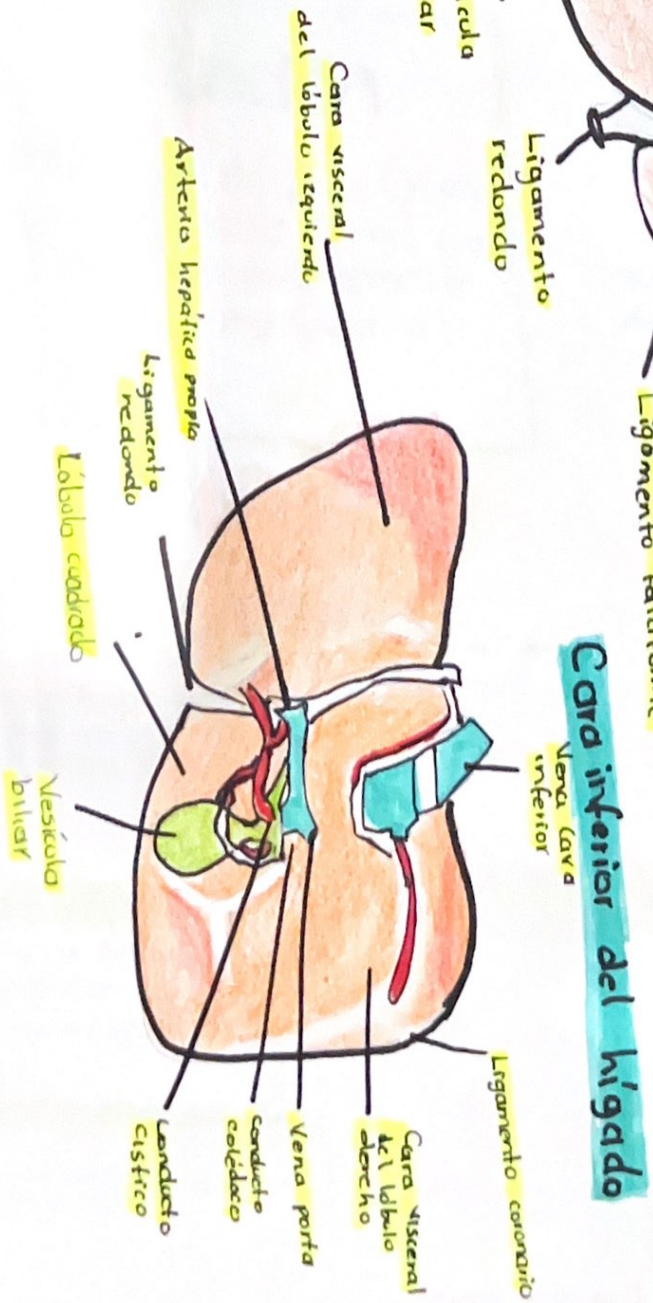
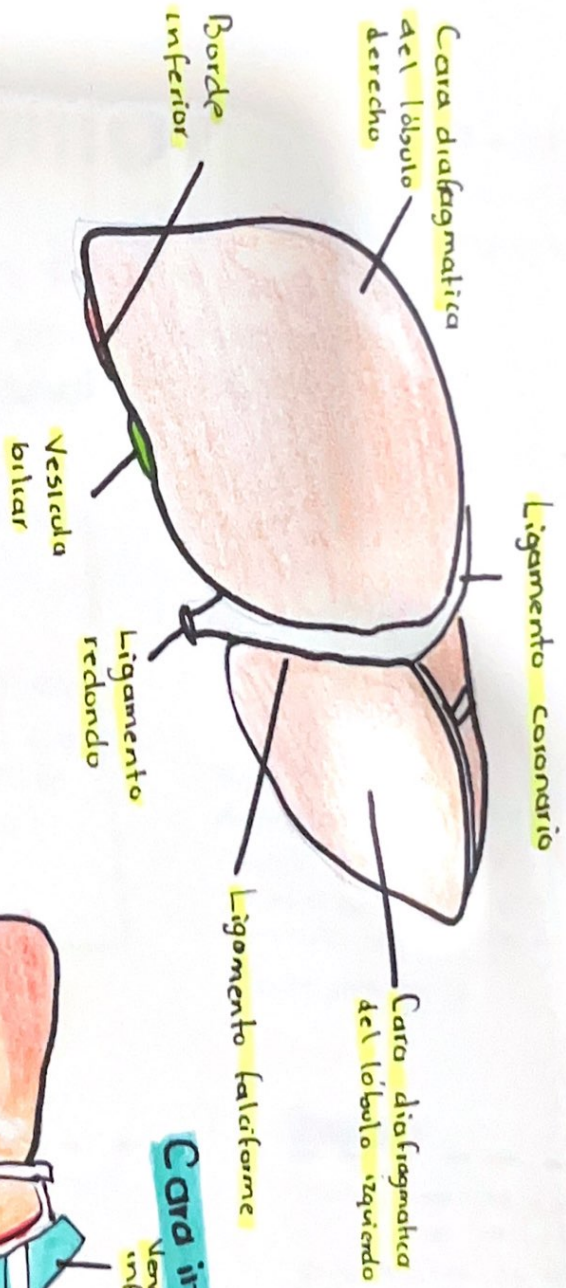
INTESTINO GUESO



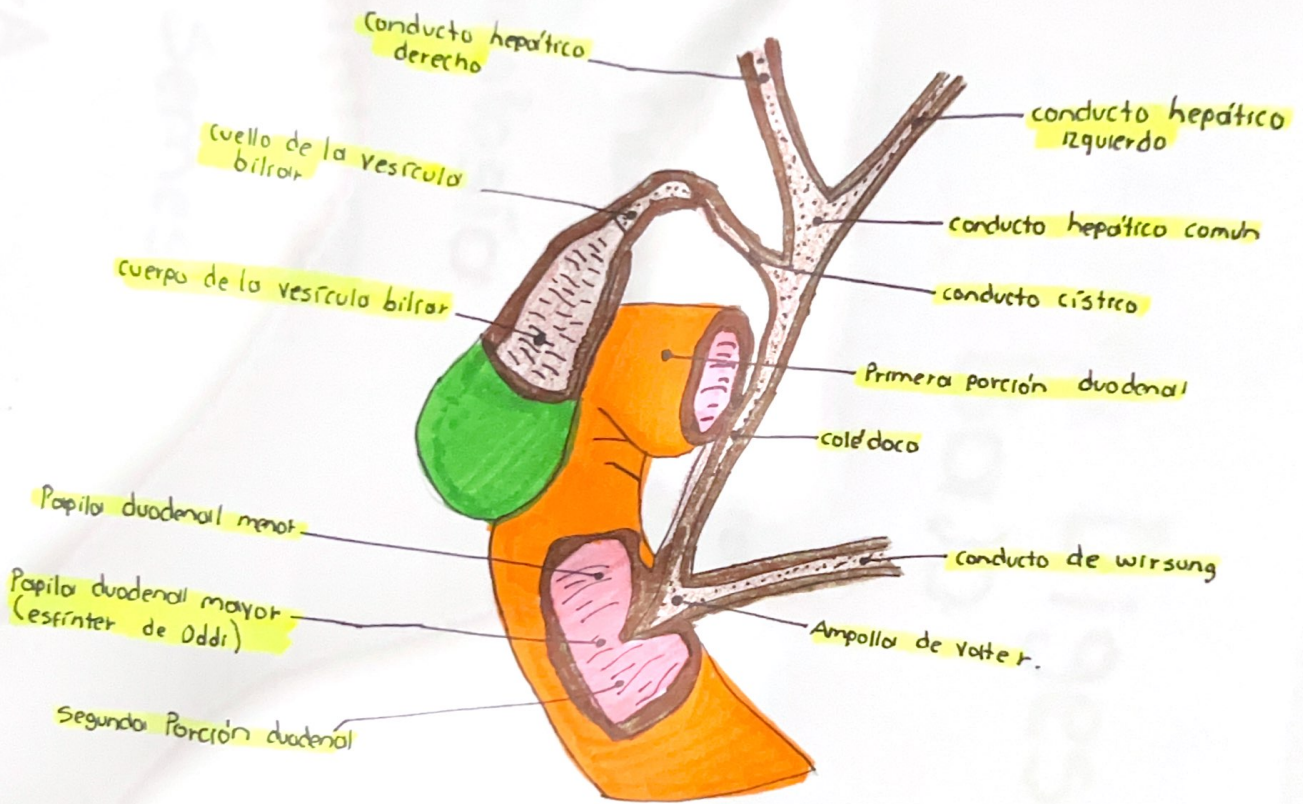
INTESTINO GRUESO



HIGADO



Vías biliares



RECTO Y ANO

