



**Mi Universidad**

## **Siguiendo con Anatomía**

*Cristian Josué Valdez Gómez*

*Siguiendo con Anatomía*

*Parcial III*

*Morfología*

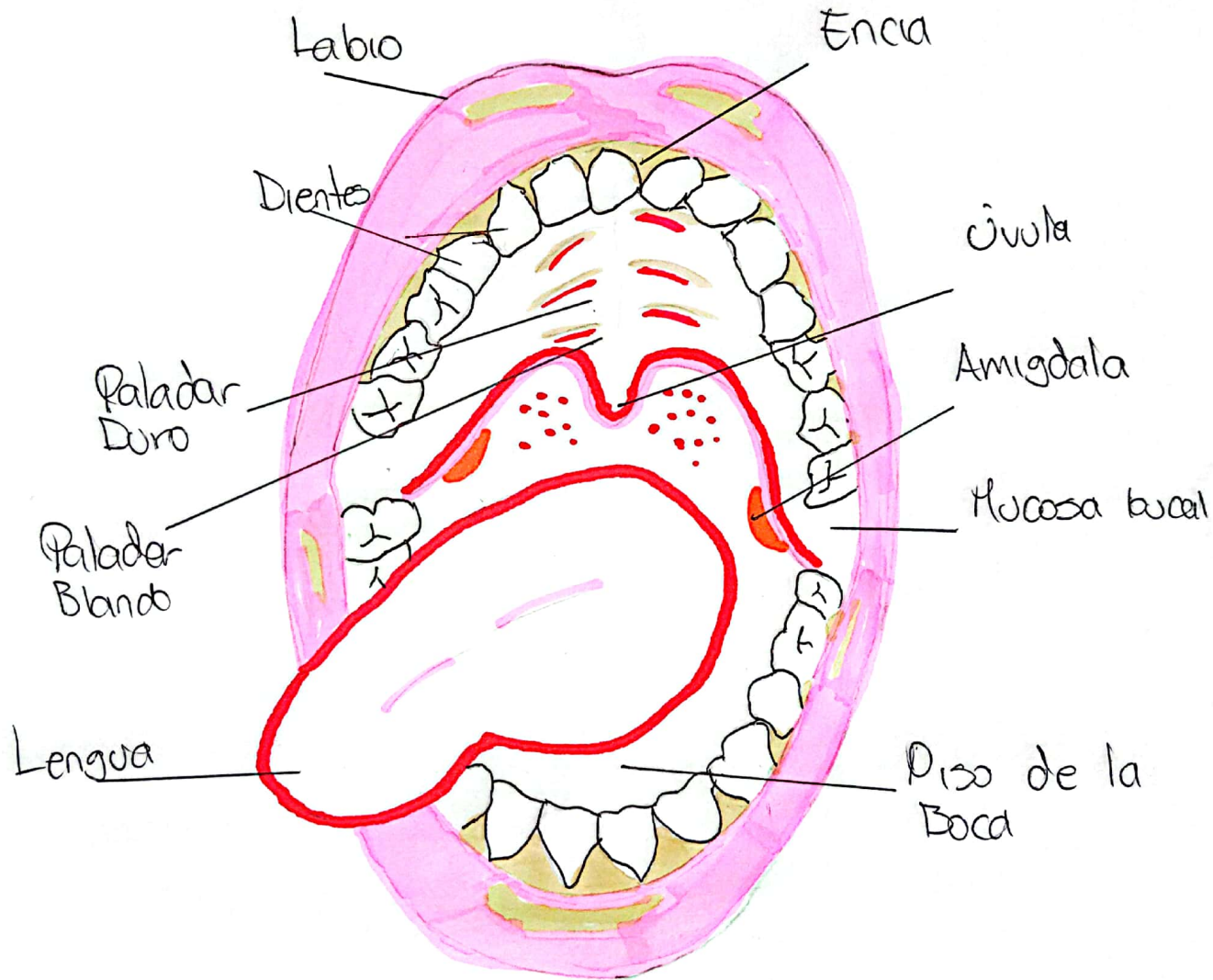
*Dr. Rosvani Margine Morales Irecta*

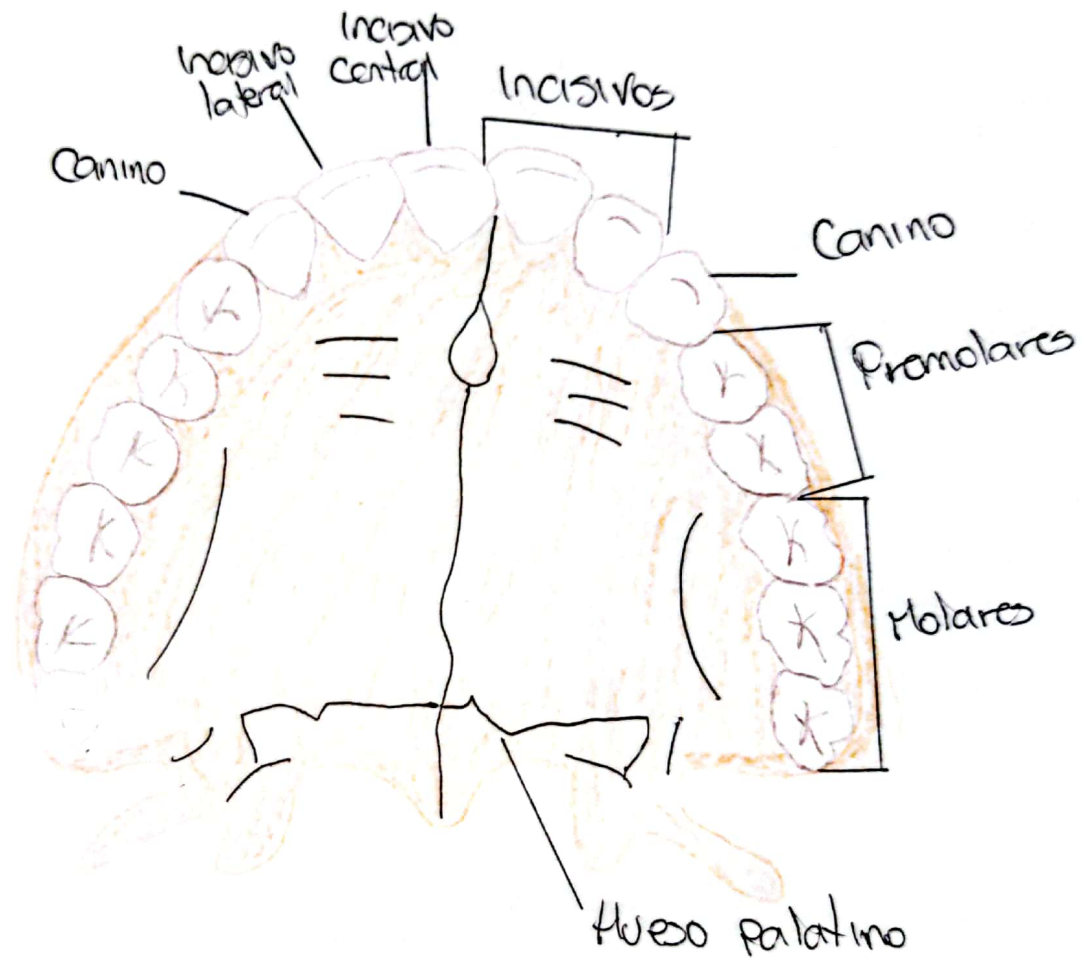
*Medicina Humana*

*Primer Semestre*

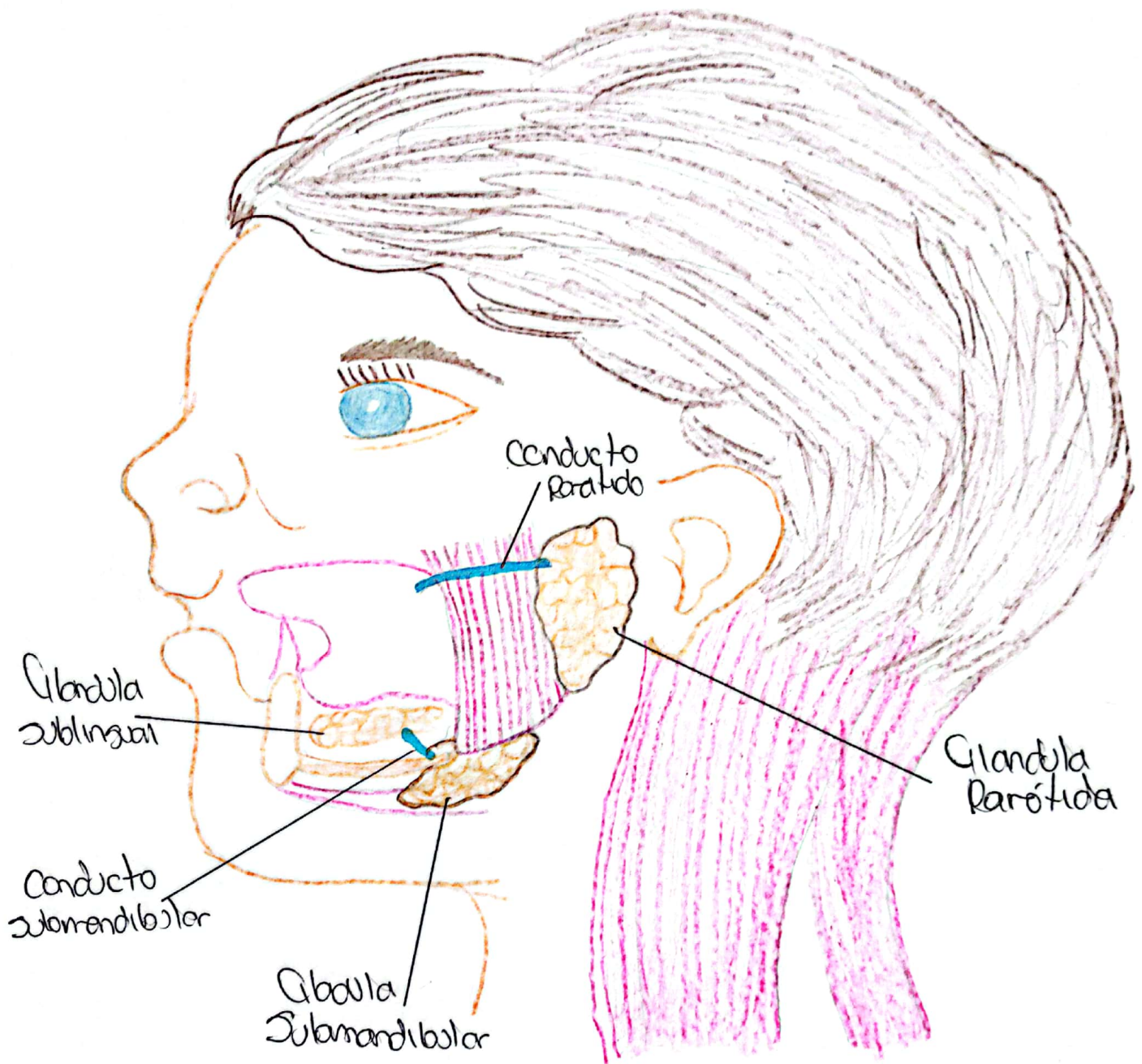
*Comitán de Domínguez, Chiapas a 17 de Noviembre de 2023*

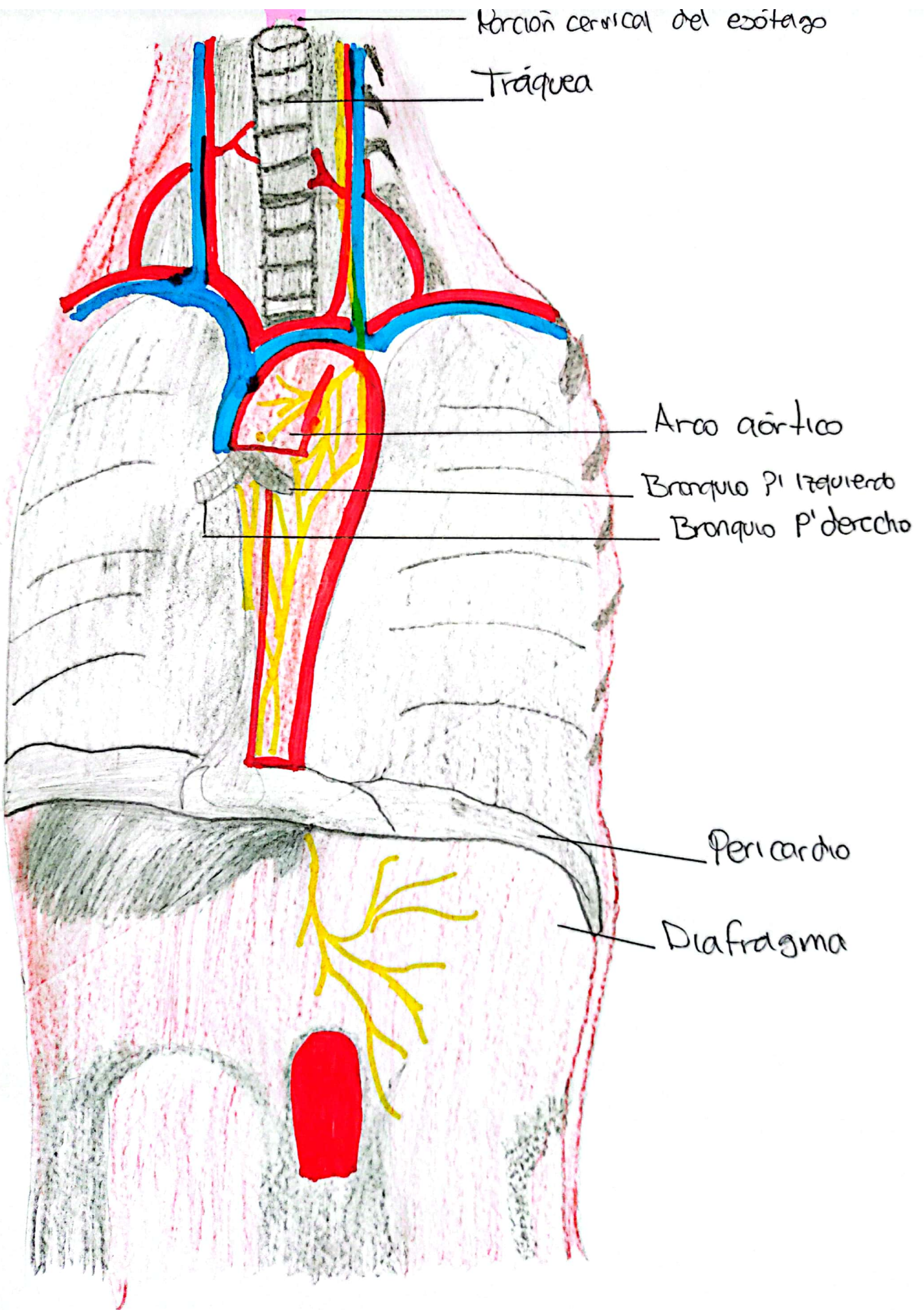
# Cavidad Oral



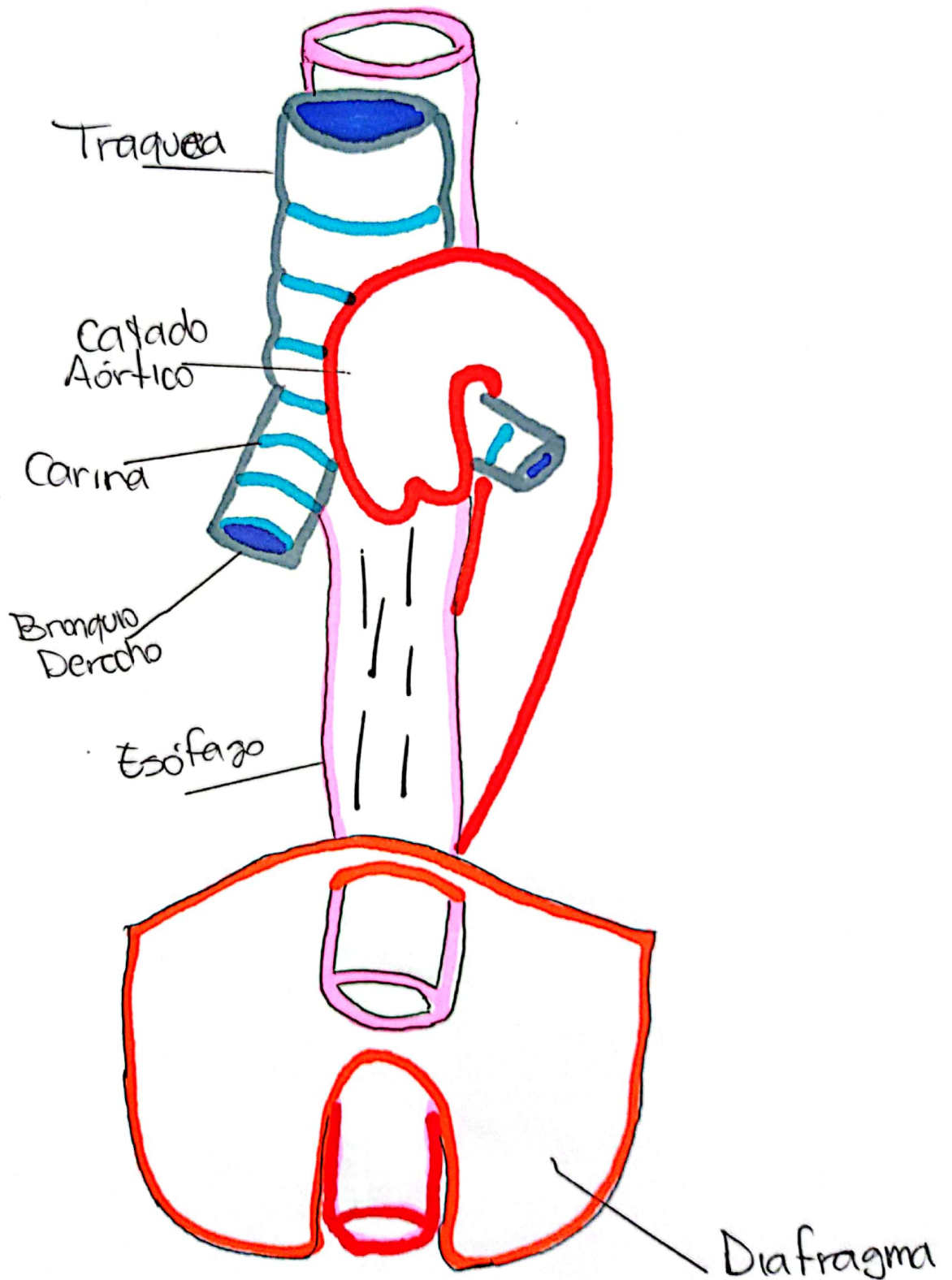


# Dientes

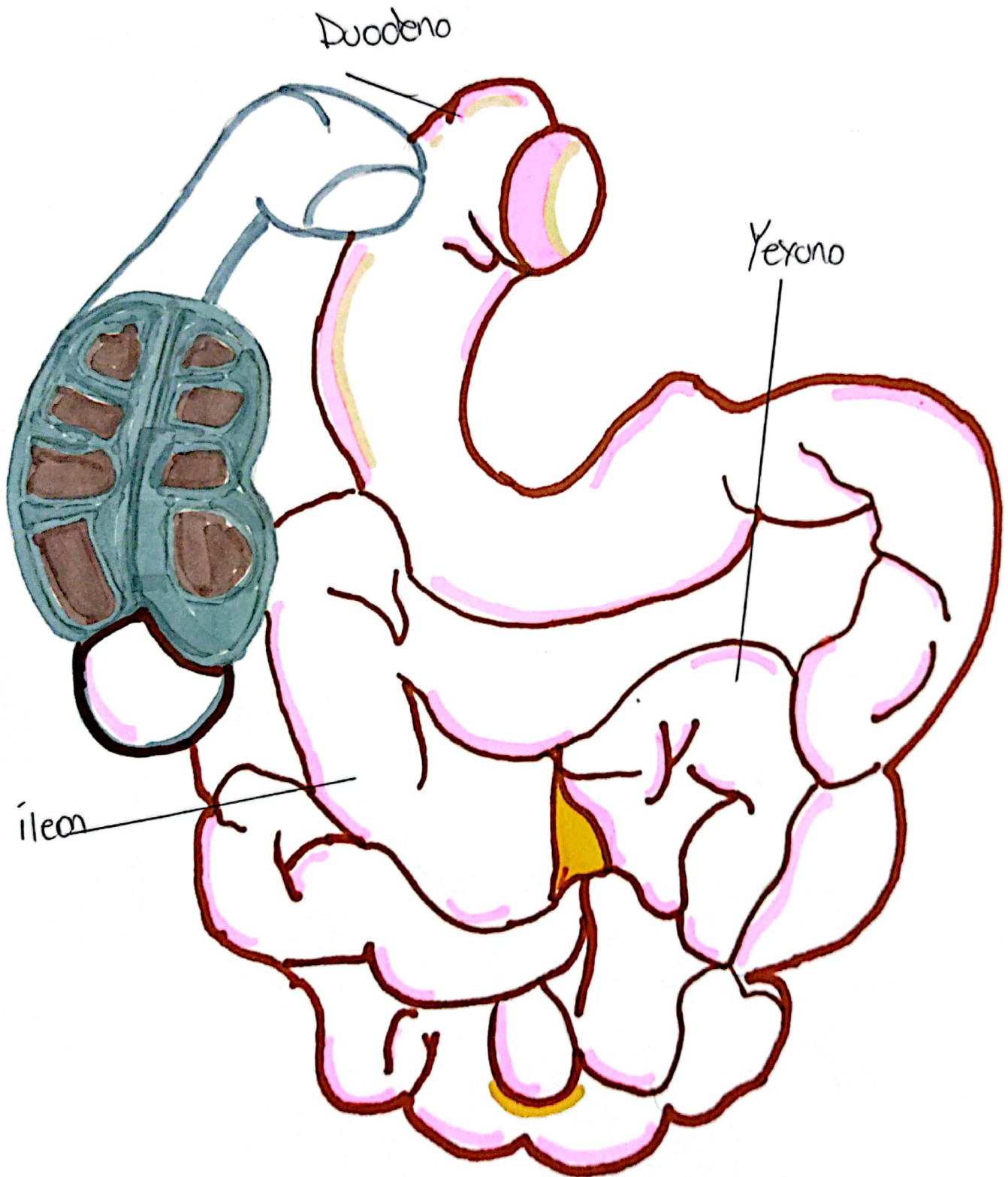




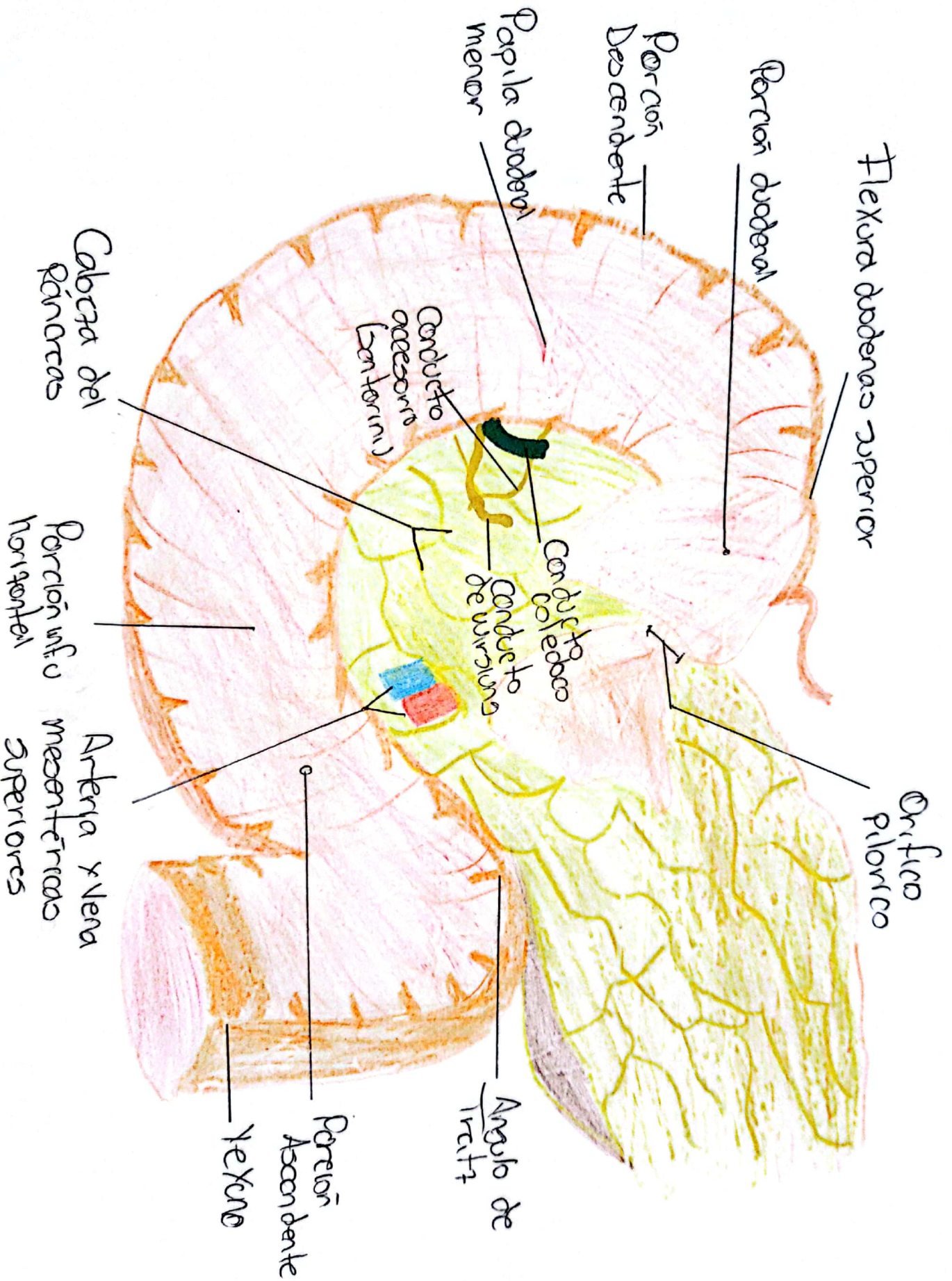
# Esófago



# Intestino Delgado

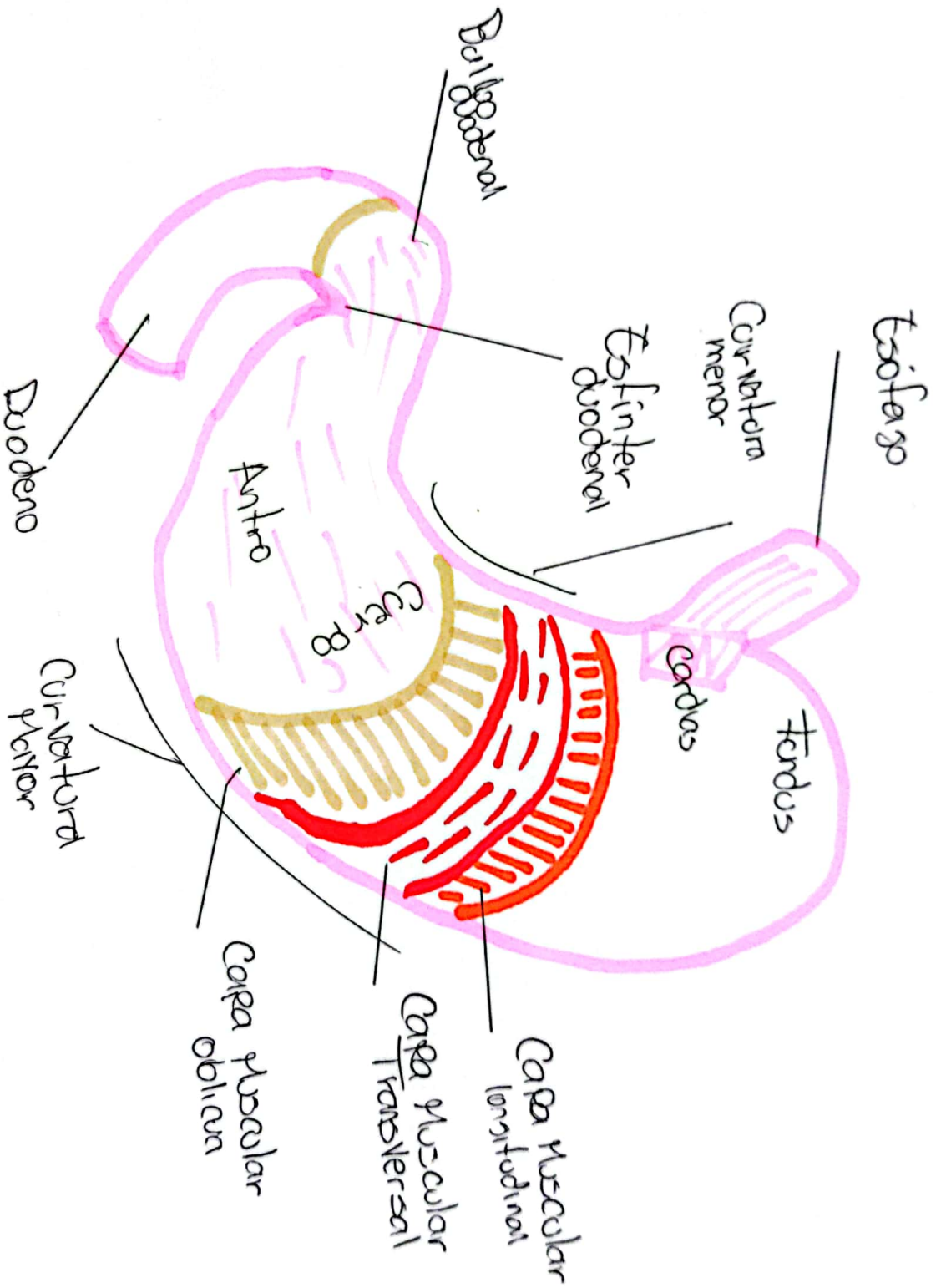


# Duodeno

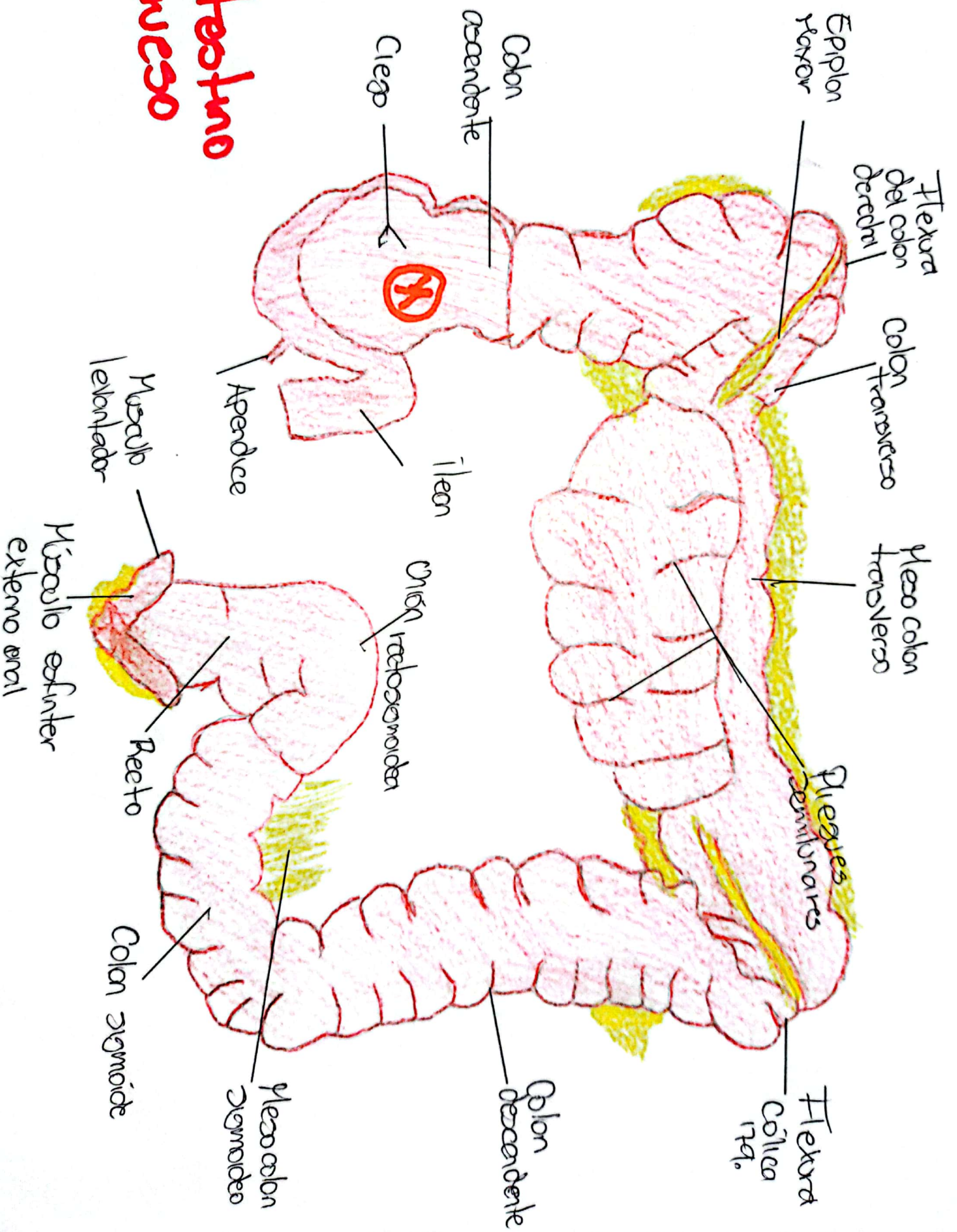




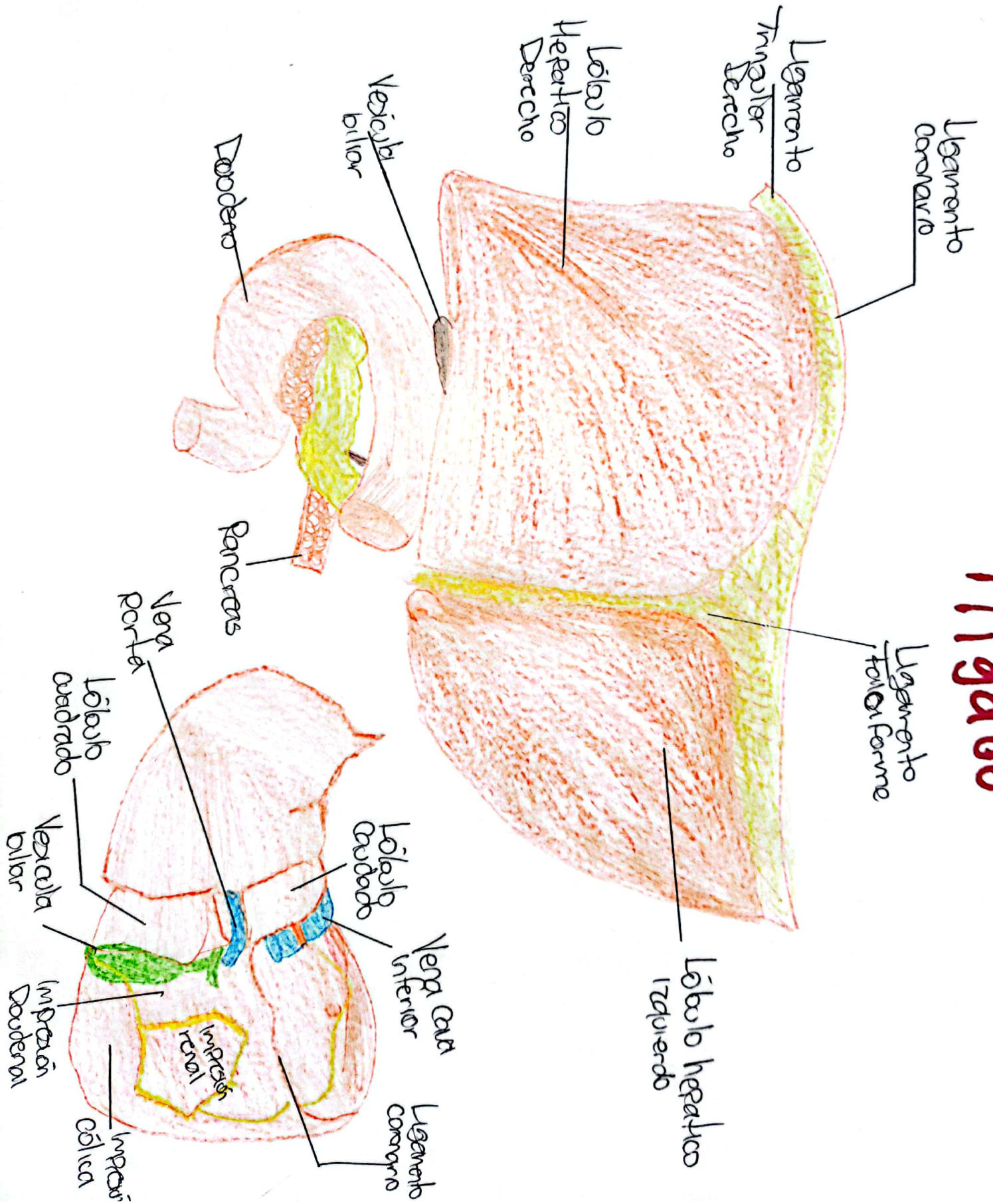
# Estômago



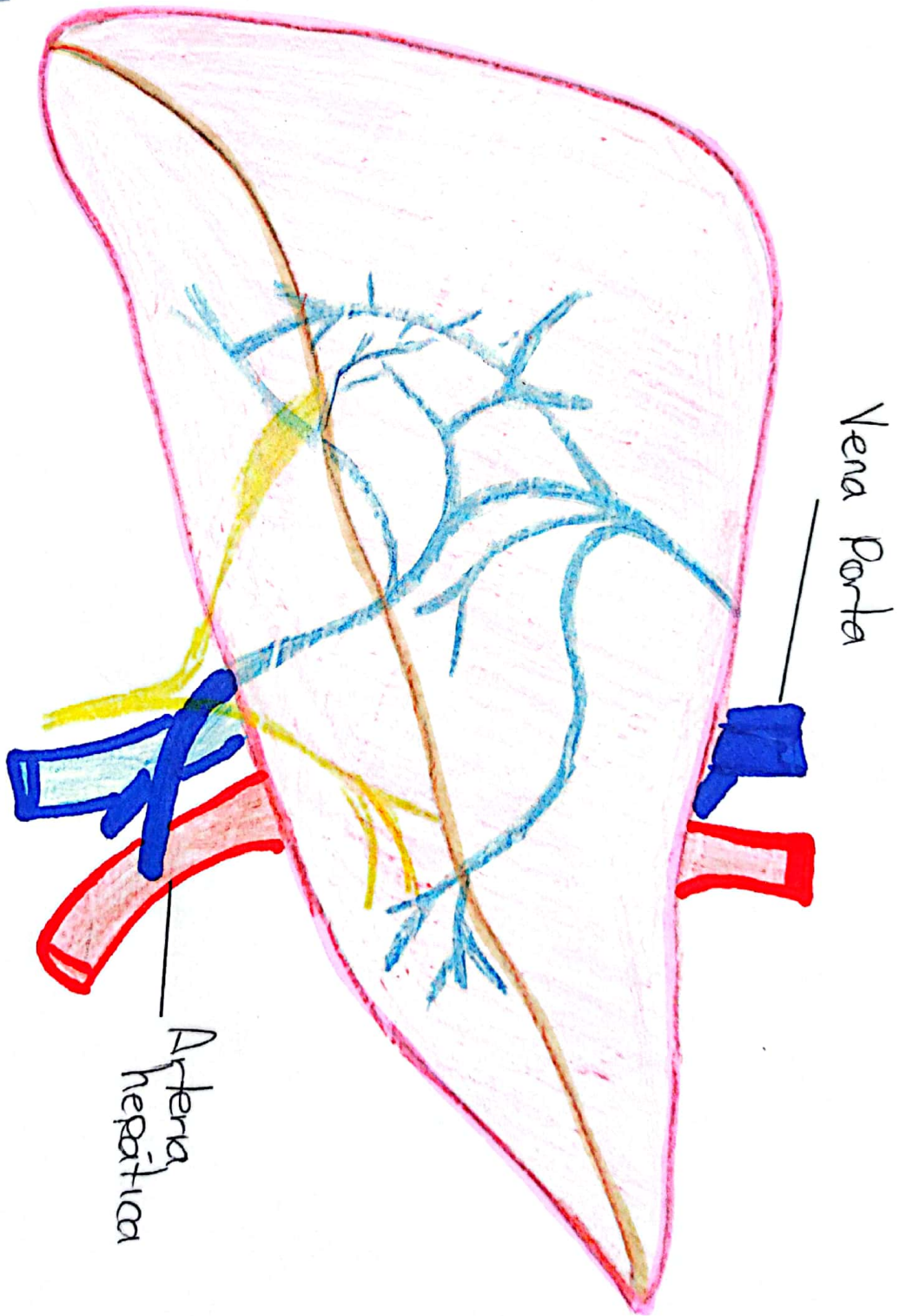
# Intestino grueso



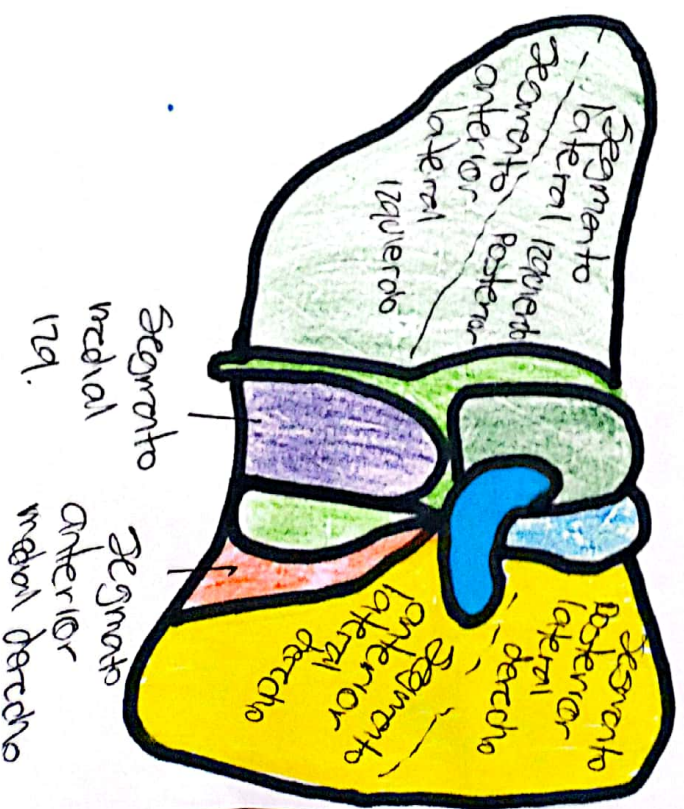

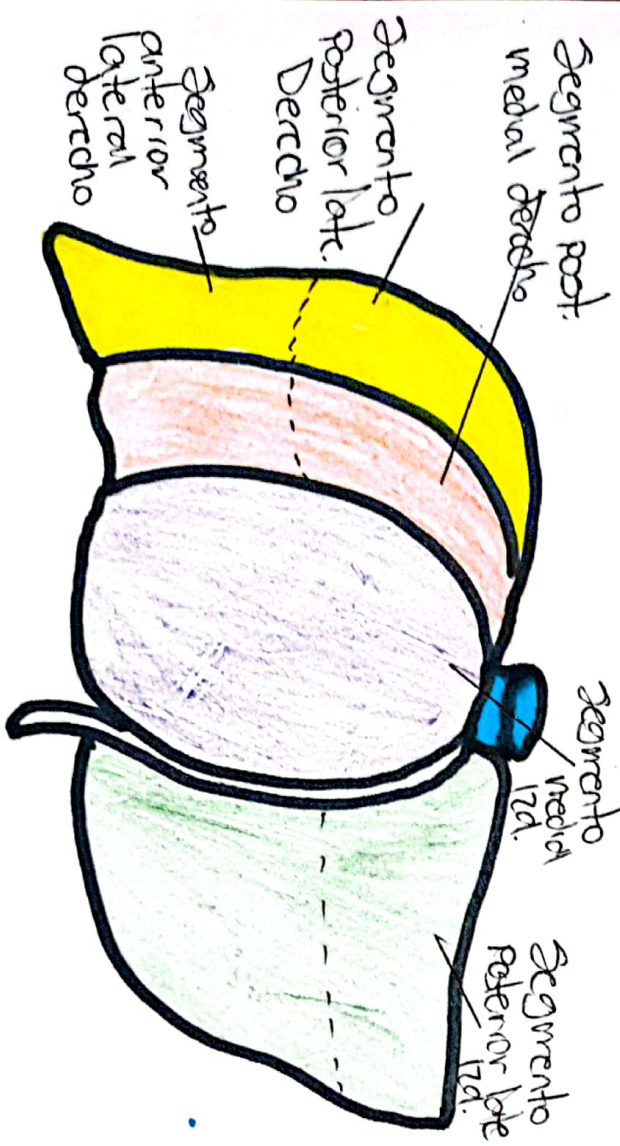

# Hígado

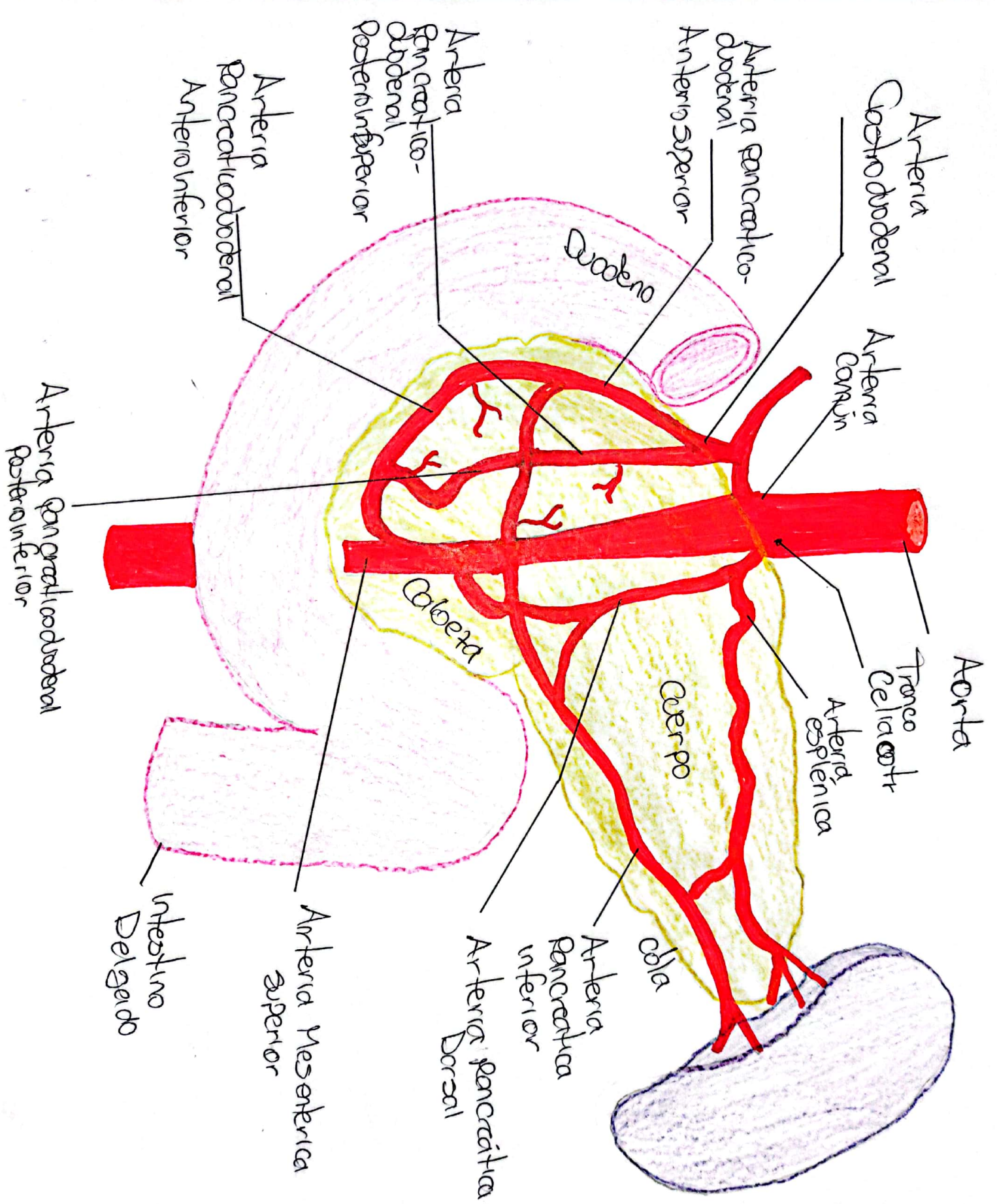


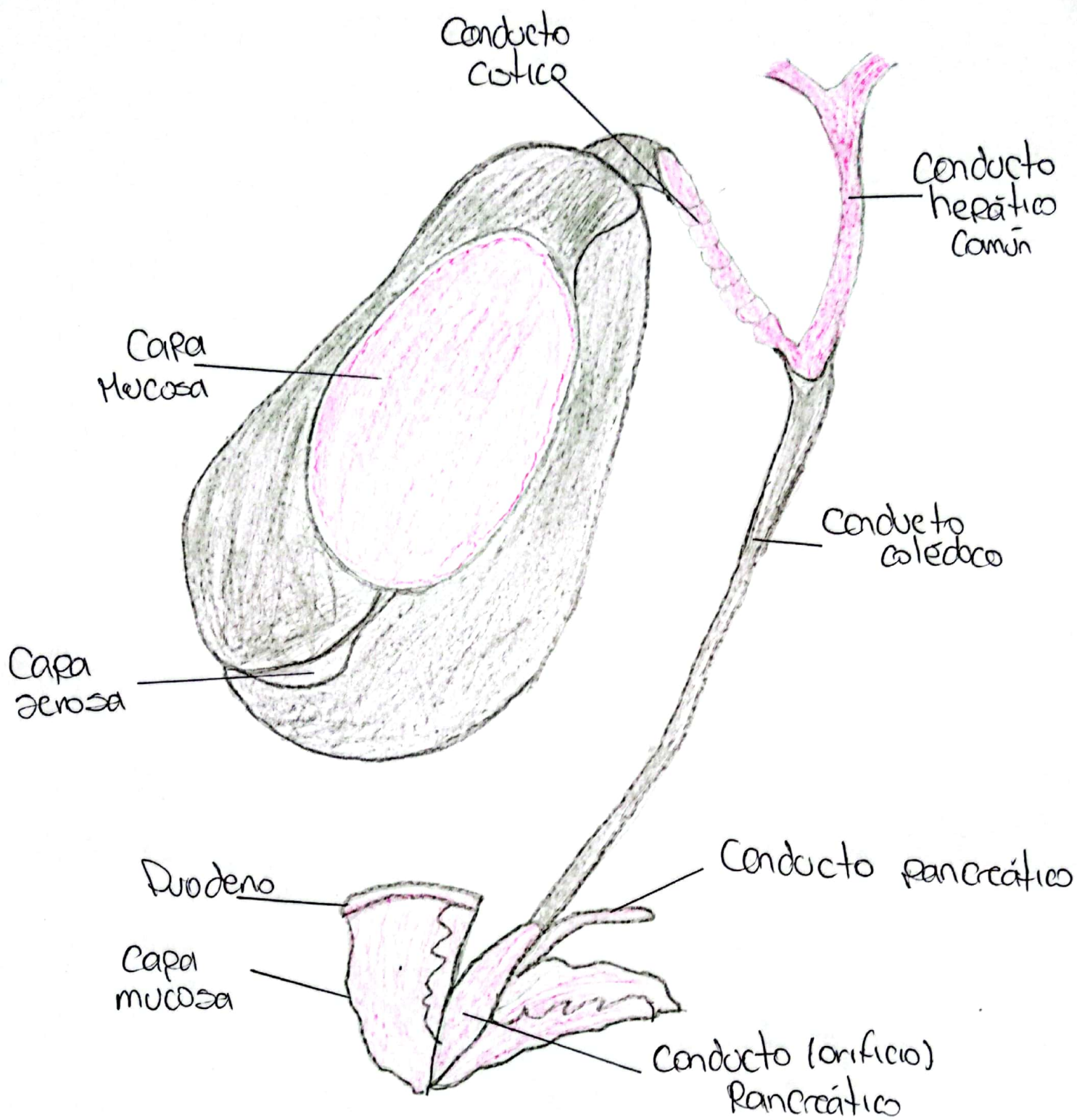
# Higado Parte II



Porción hepática derecha  
 División lateral derecha  
 División medial derecha  
 División medial izquierda  
 División lateral izquierda

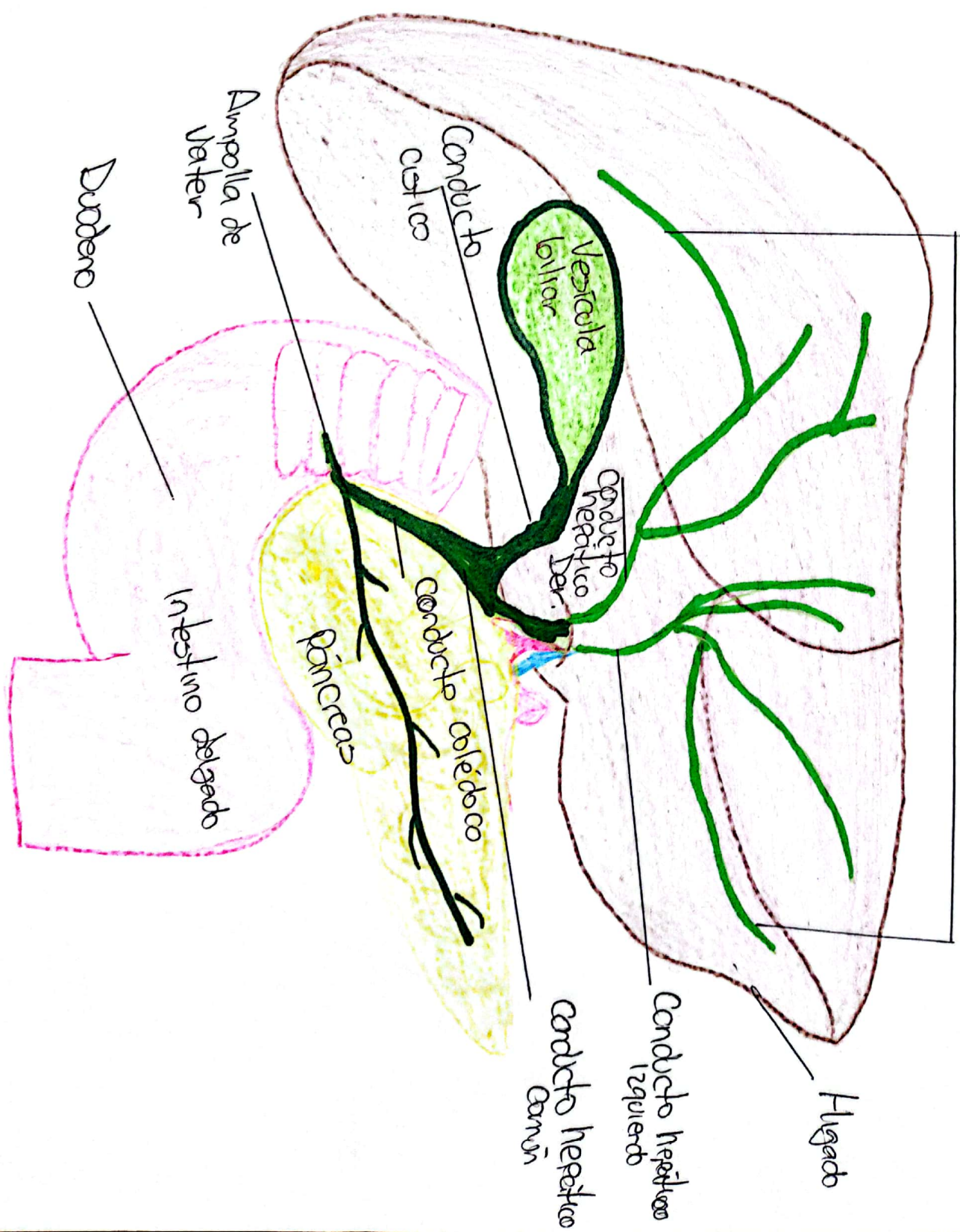




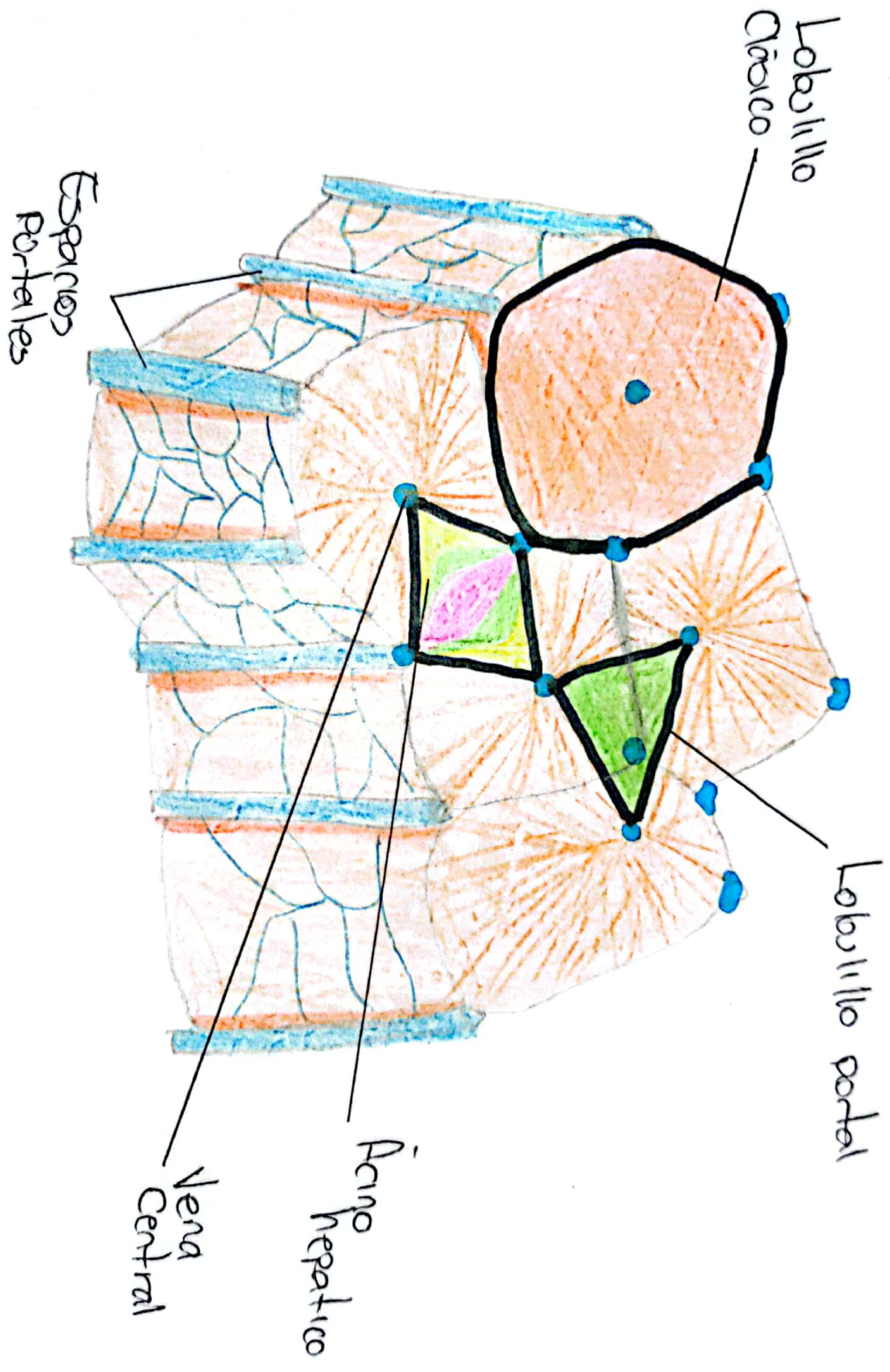


# Vesícula Biliar

Vías biliares intrahepáticas







## **Bibliografías:**

L. MOORE, KEITH, (2017), ANATOMÍA CON ORIENTACIÓN CLÍNICA. 8° EDICIÓN  
NETTER, Frank H... Atlas de anatomía humana. 2ª edición Porto Alegre: Artmed.  
2000.