



Mireya Perez Sebastian

Aparato Digestivo Superior/Inferior

Parcial III

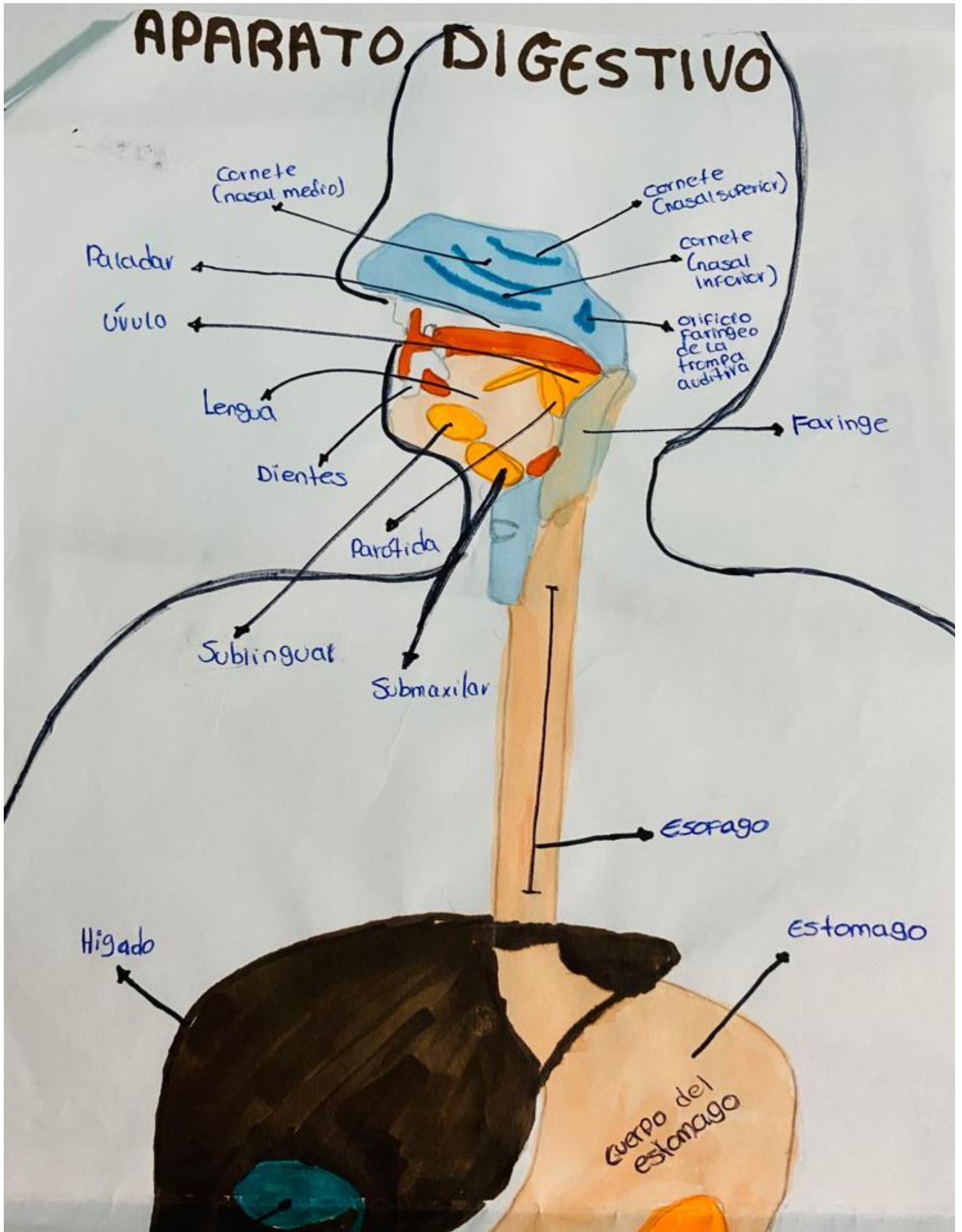
Morfología

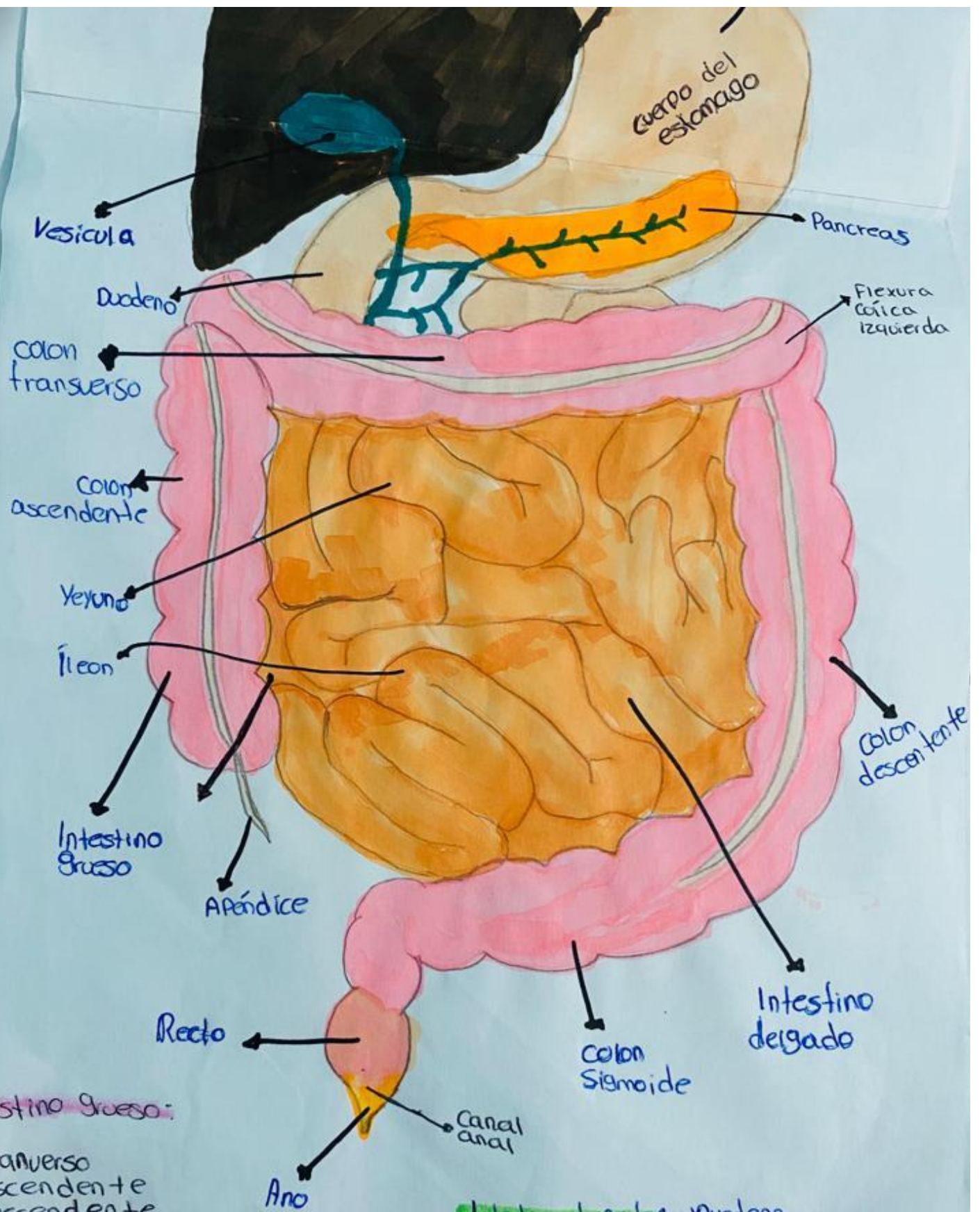
Dra. Morales Ireta Rosvani Margine

Medicina Humana

Primer Semestre.

APARATO DIGESTIVO





Intestino grueso:

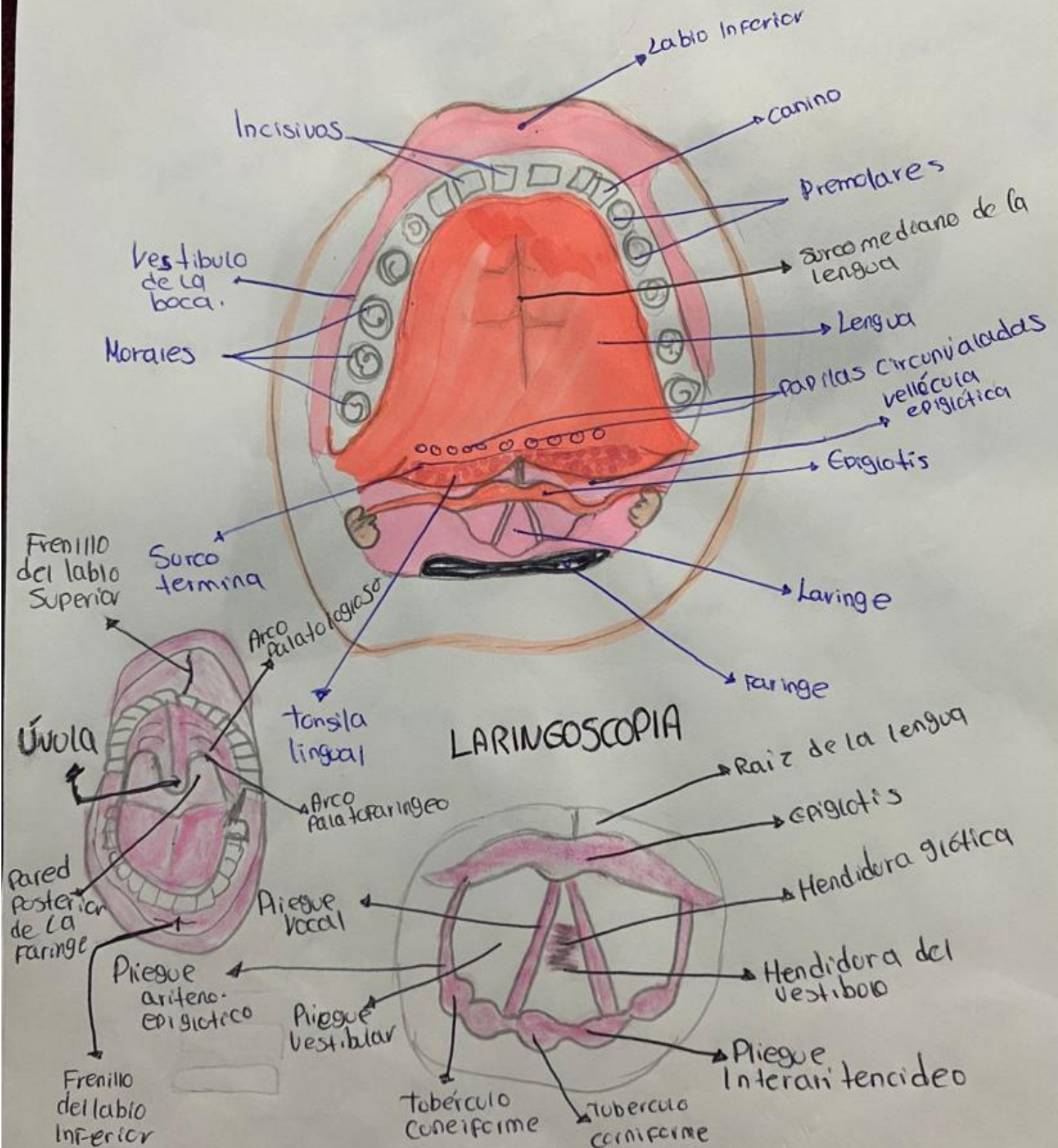
- transverso
- ascendente
- descendente
- sigmoide

Intestino delgado:

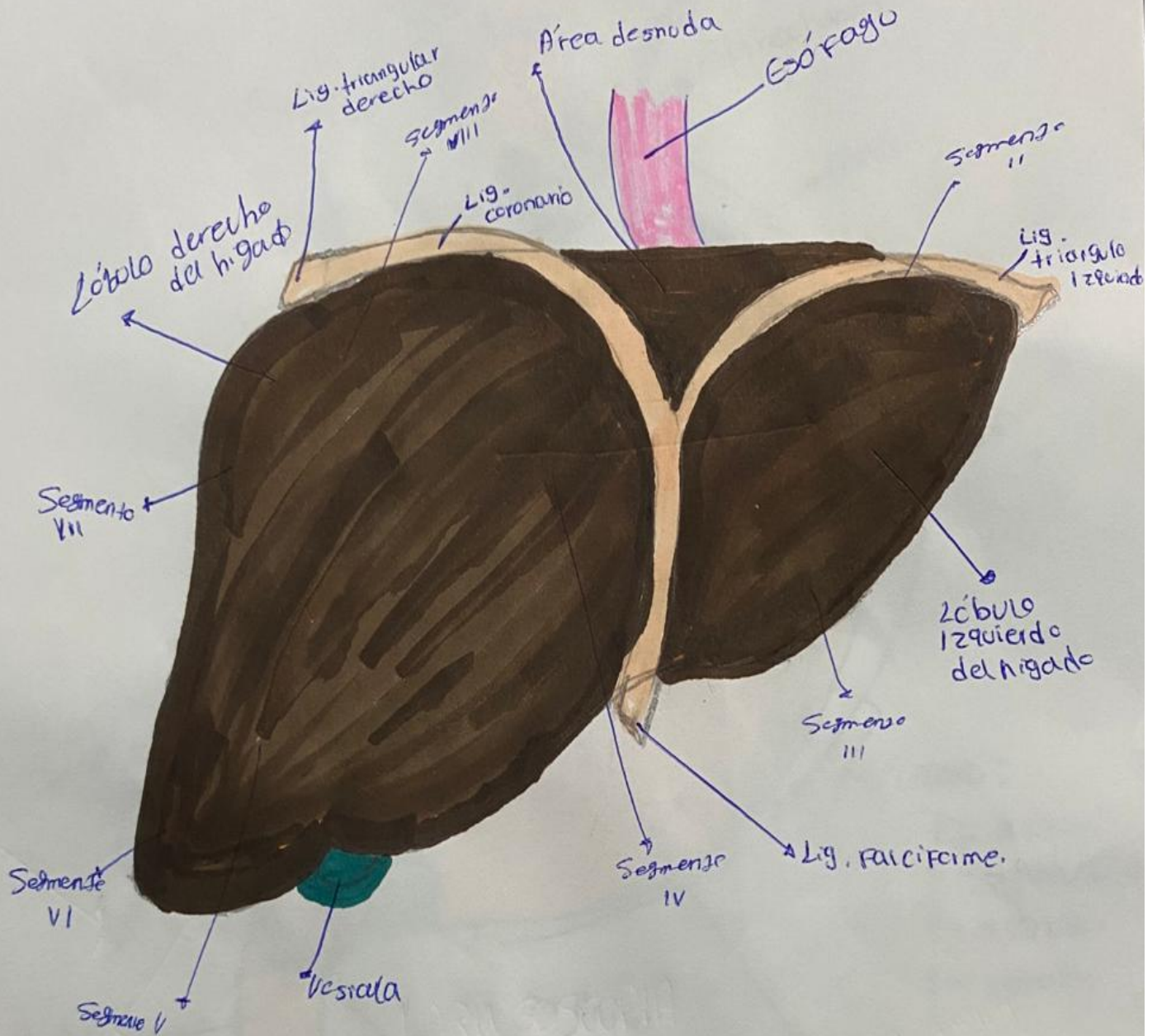
- Dudeno
- Yeyuno
- Íleon

13/11/23

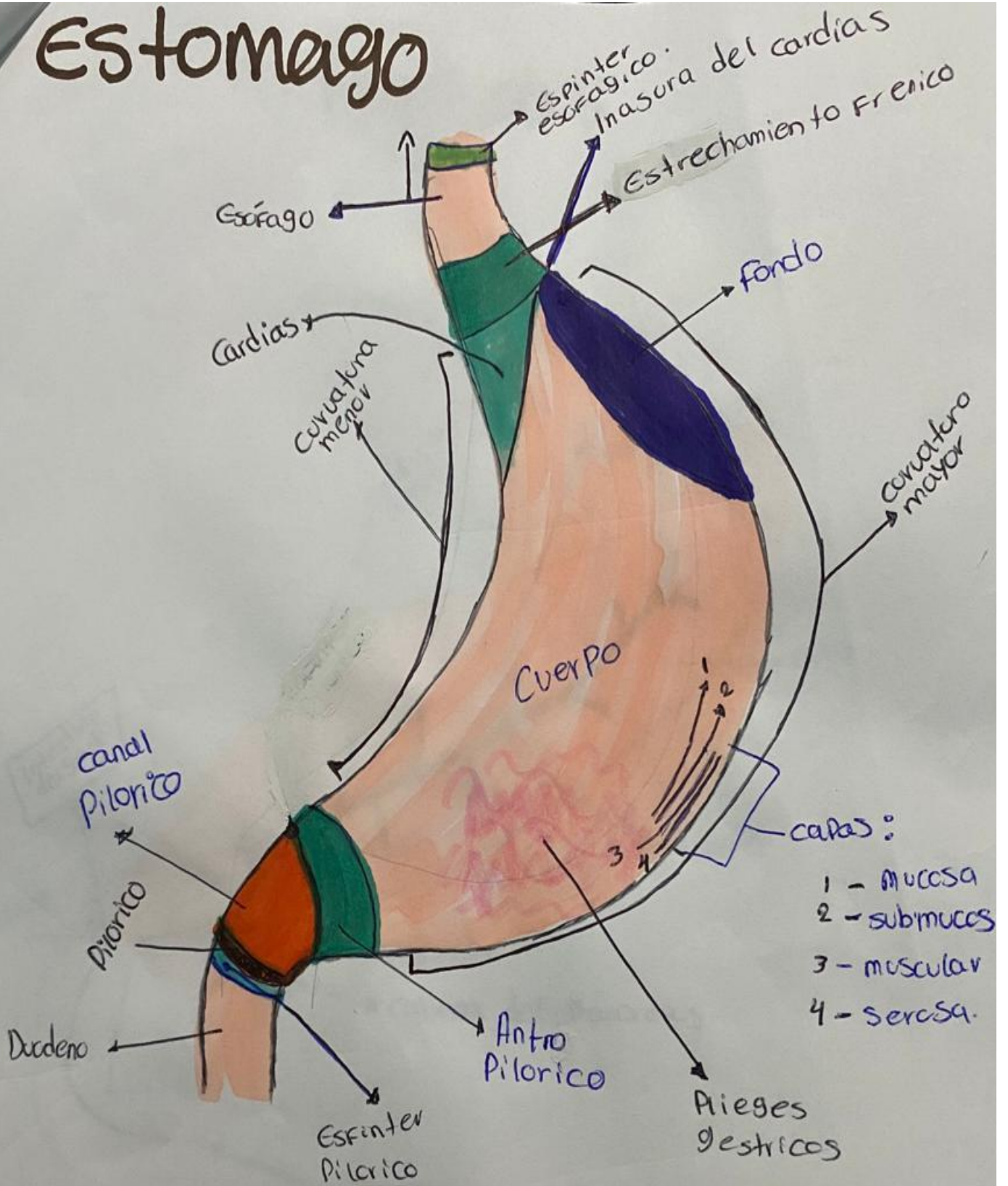
Cavidad Oral



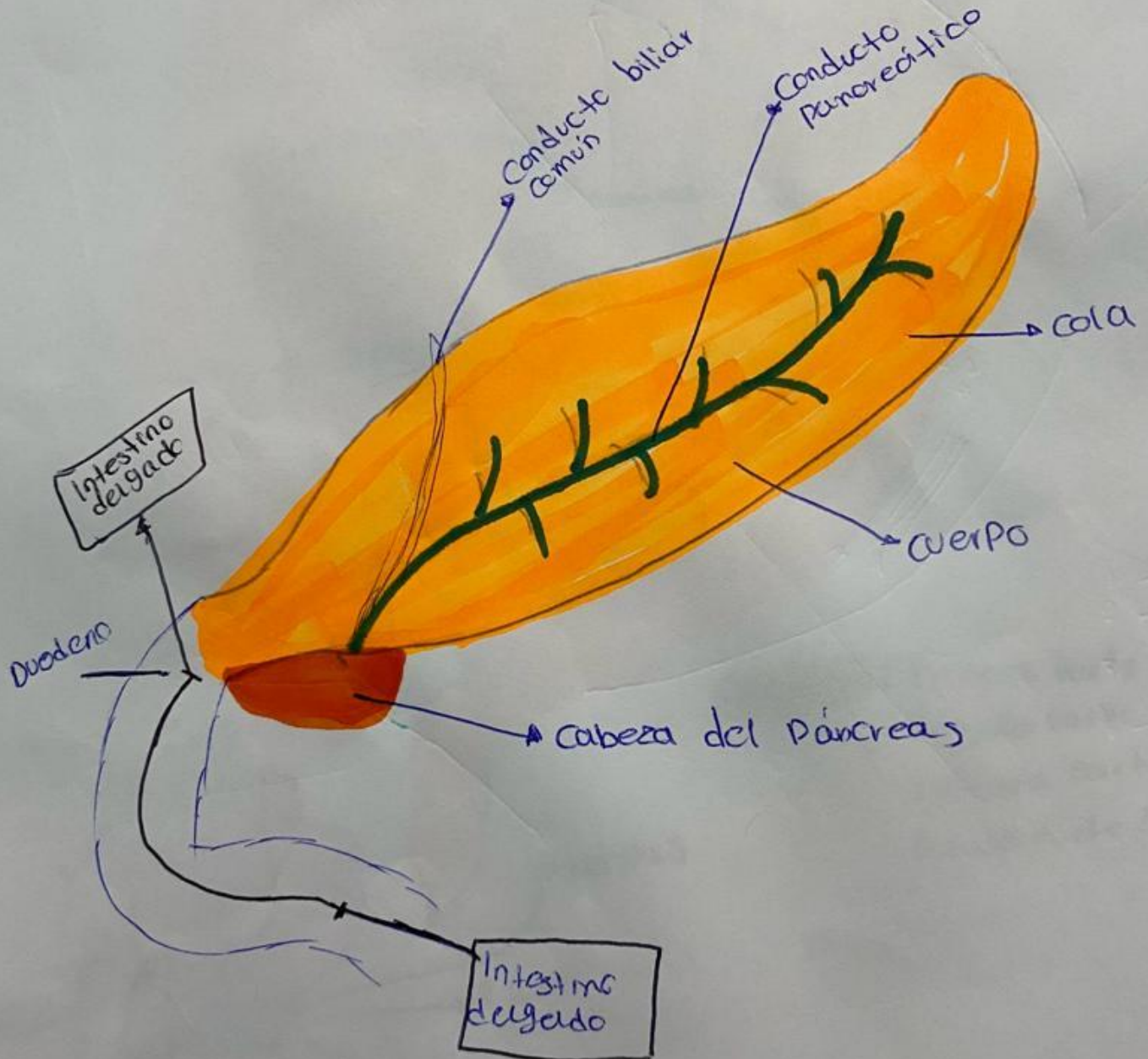
Higado



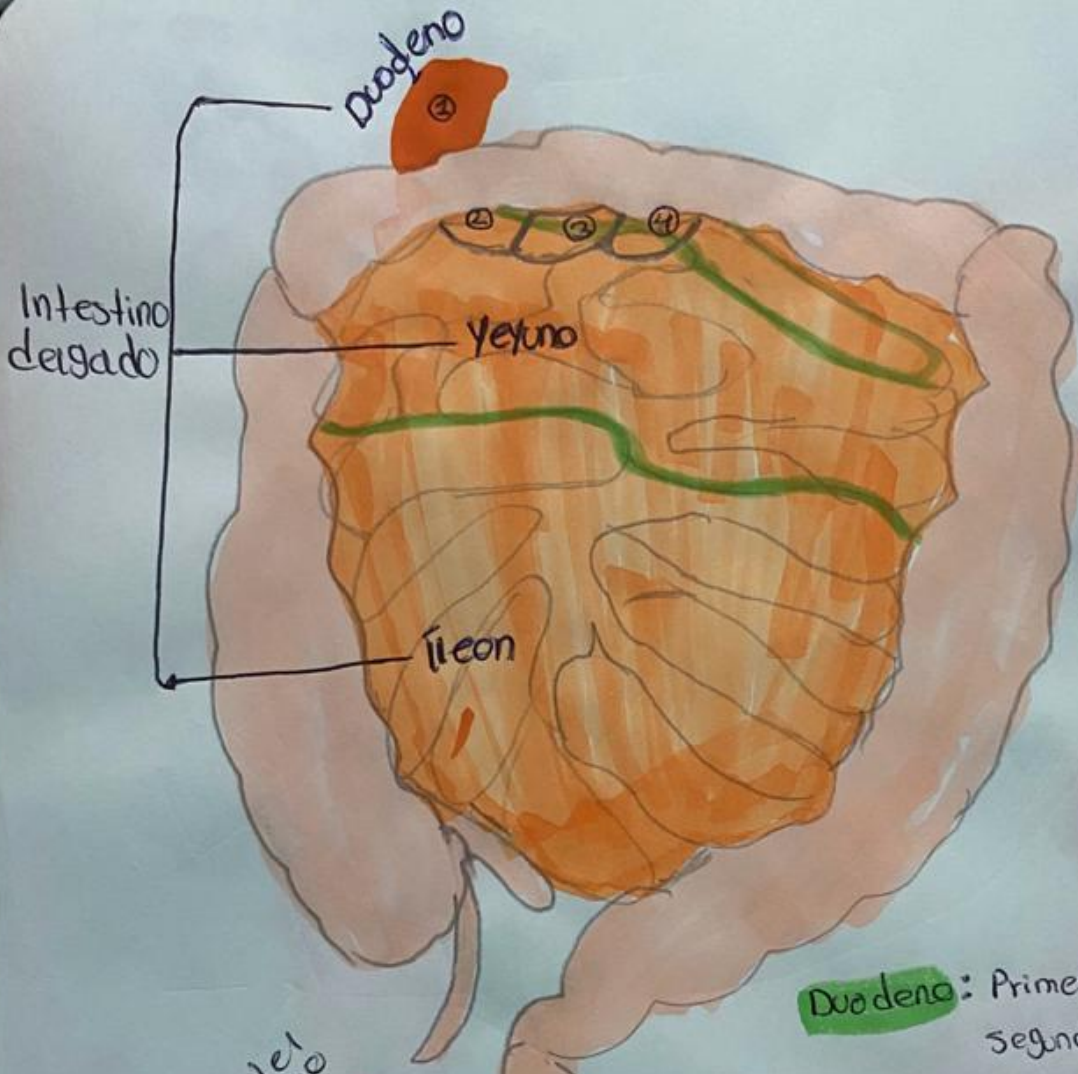
Estomago



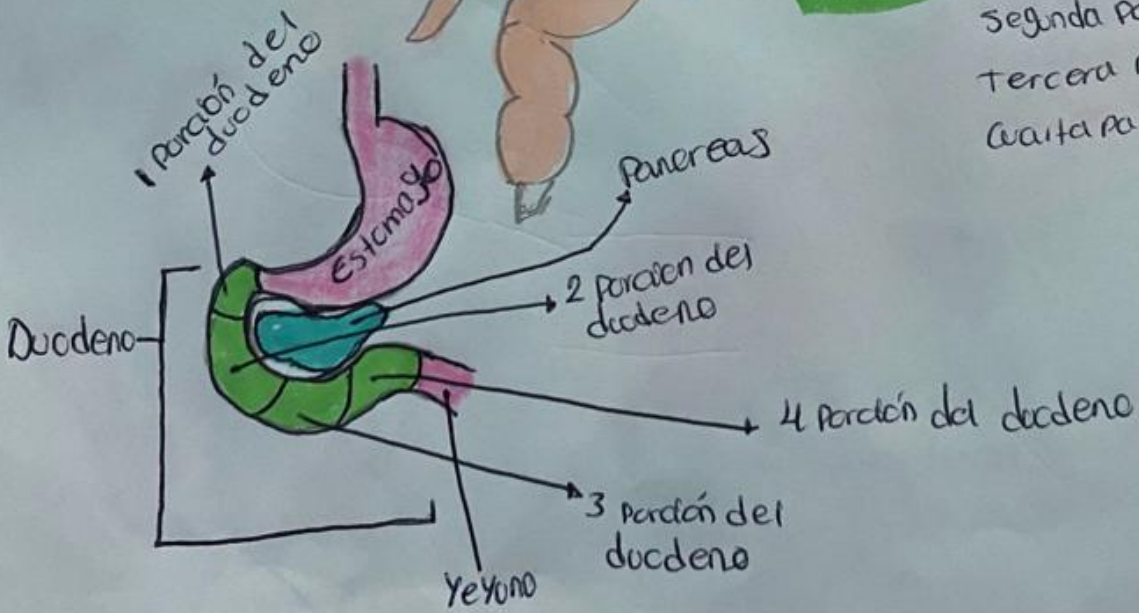
Pancreas



Intestino delgado

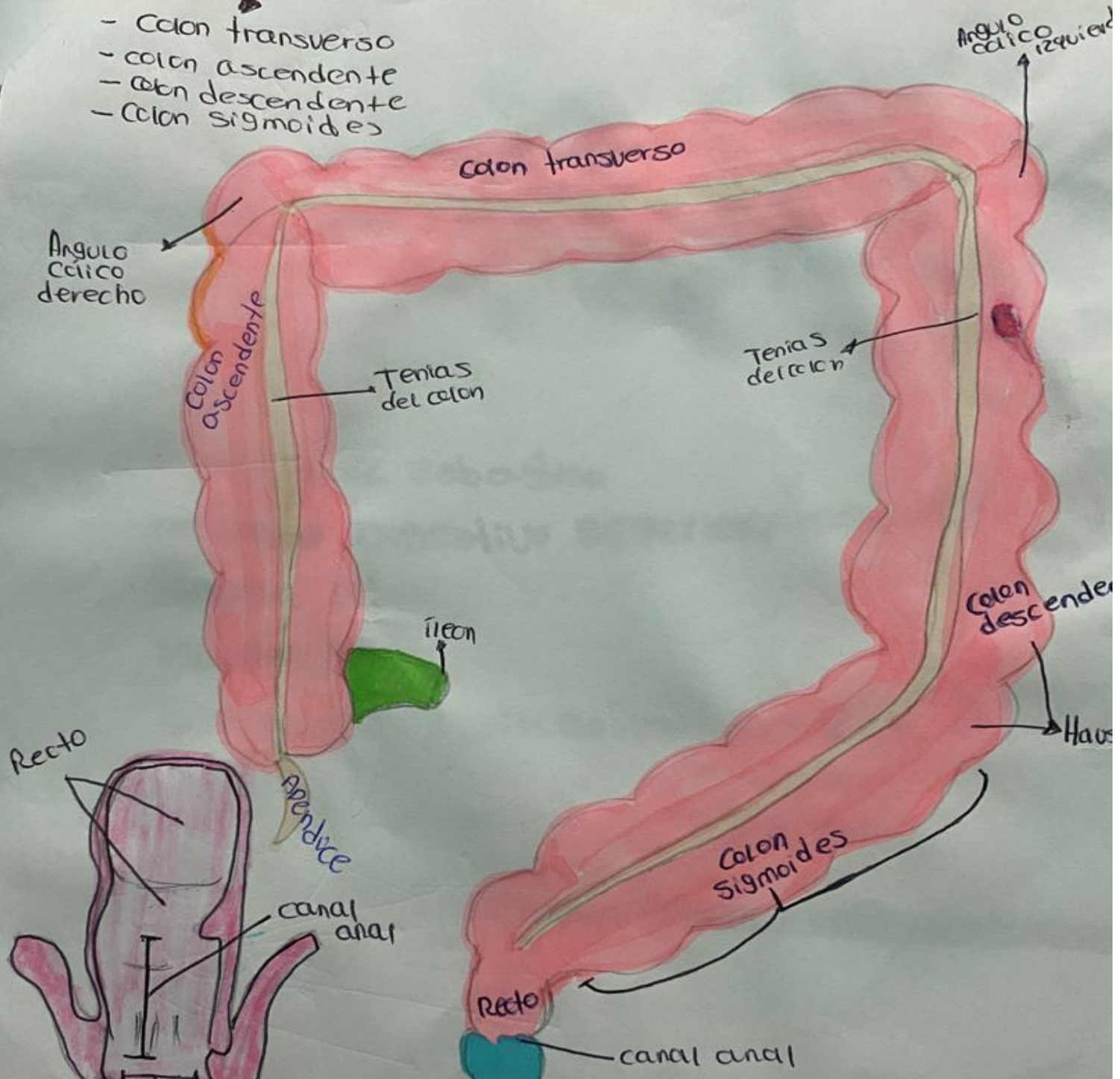


Duodeno: Primera parte mide 5 cm
Segunda parte mide 7-10 cm
Tercera parte mide 6-8 cm
Cuarta parte mide 5 cm



Intestino grueso

- Colon transverso
- colon ascendente
- colon descendente
- Colon sigmoides



REFERENCIA

Anatomía clínica/ Eduardo Pró; ilustrado por Ezequiel Martínez y Laura Vietto. -2ª ed.- Ciudad Autónoma de Buenos Aires.: Médica panamericana, 2014.