



UDRS

Mi Universidad

Moises Santiz Alvarez

Parcial III

Morfología

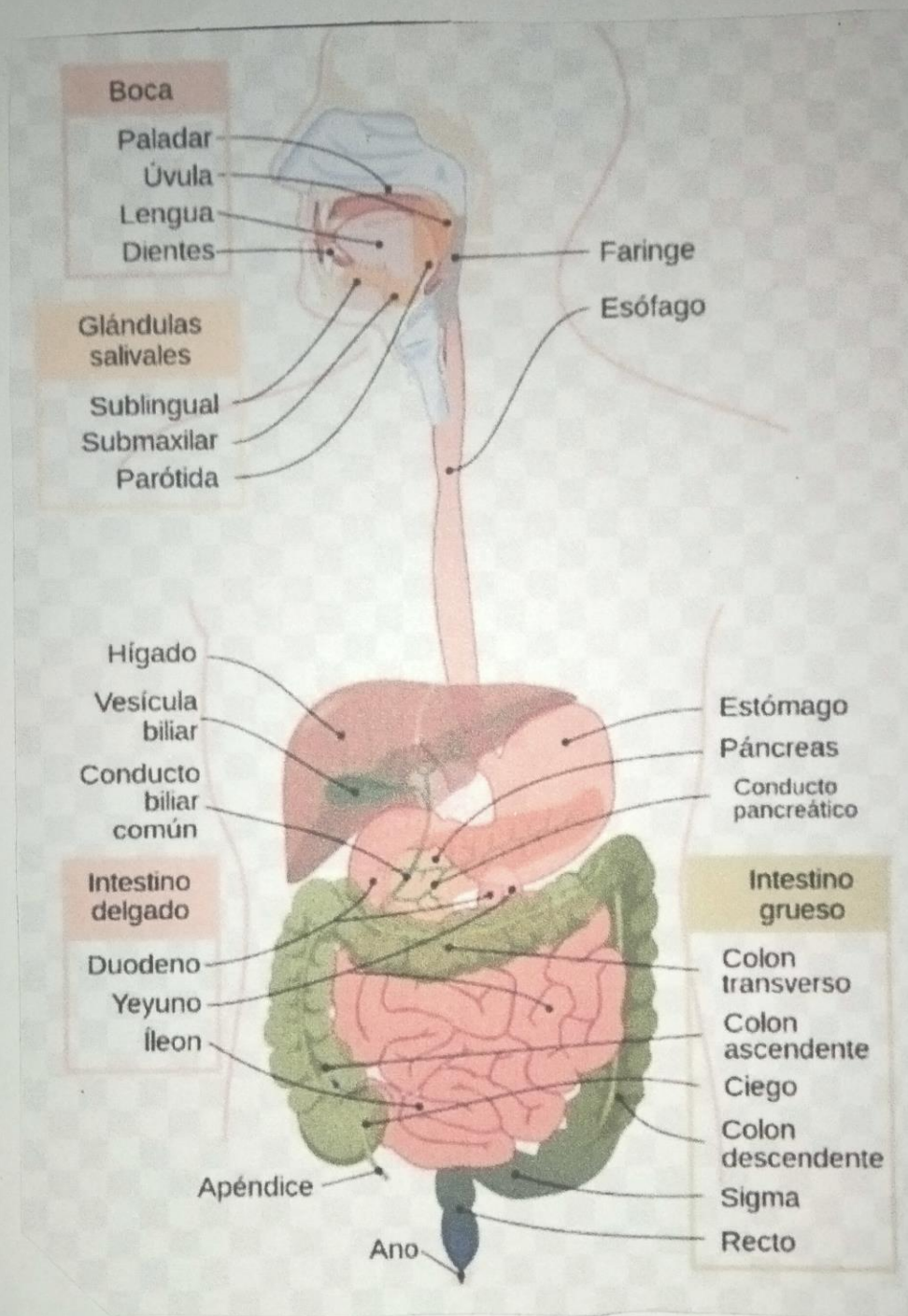
Dra. Rosvani Margine Morales Irecta

Medicina Humana

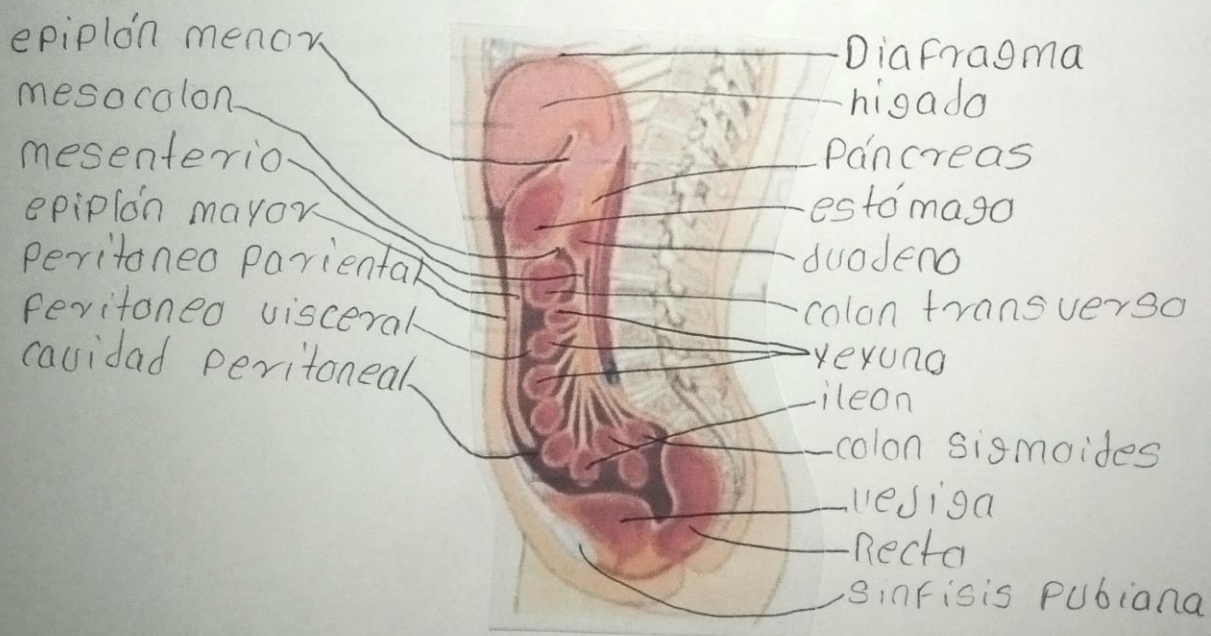
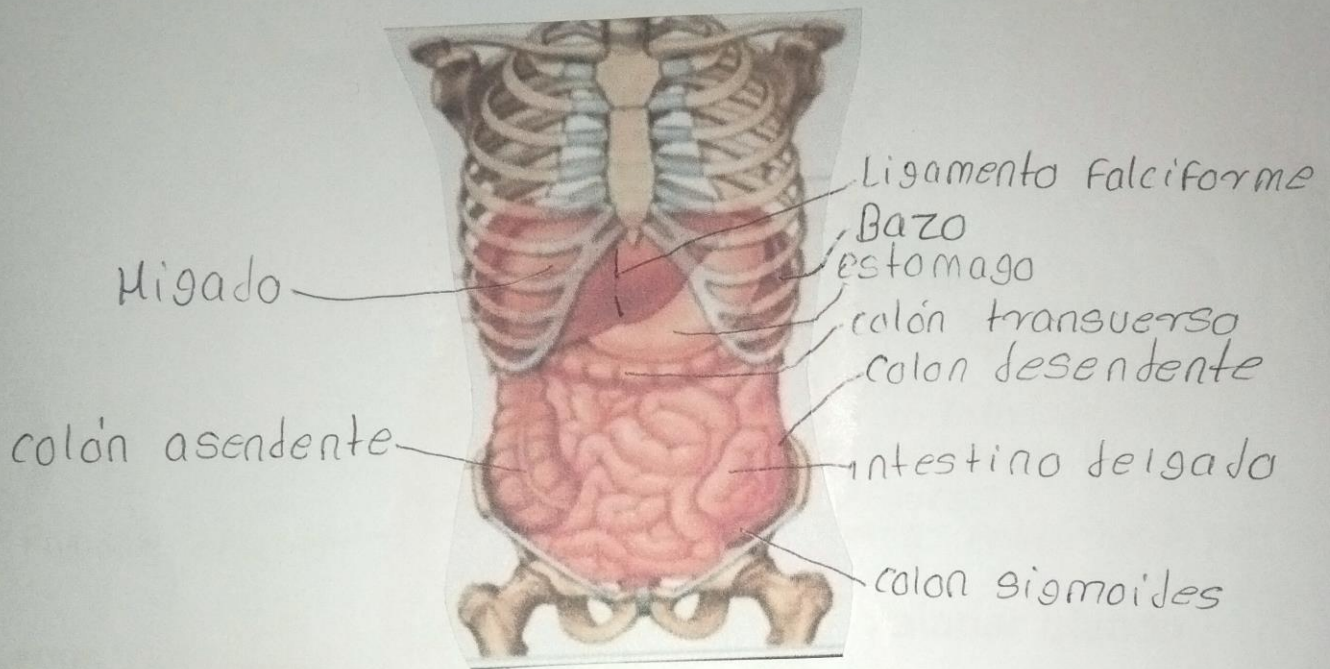
Primer Semestre

Comitán de Domínguez, Chiapas a 17 de noviembre de 2023

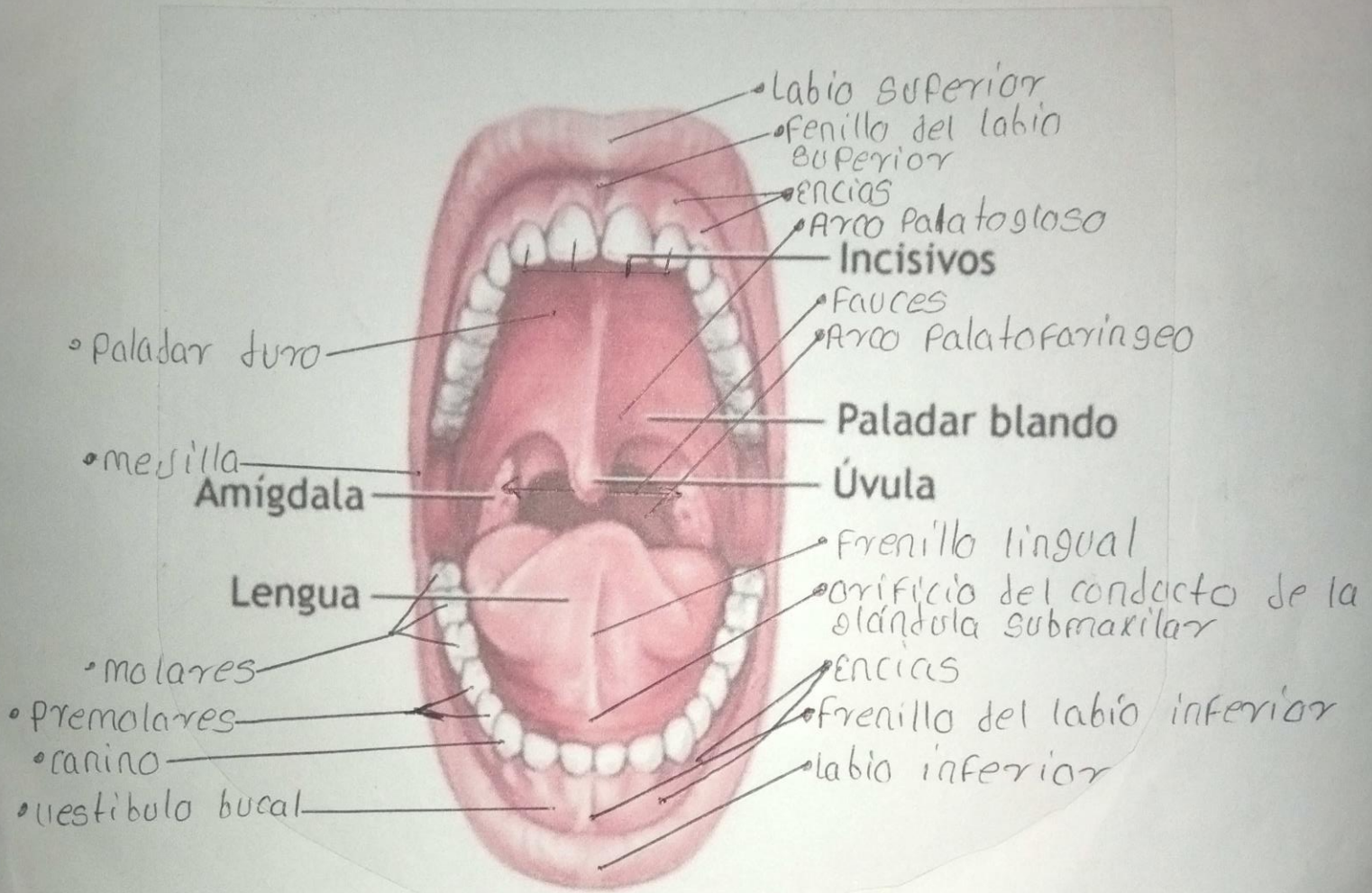
Aparato digestivo alto y bajo



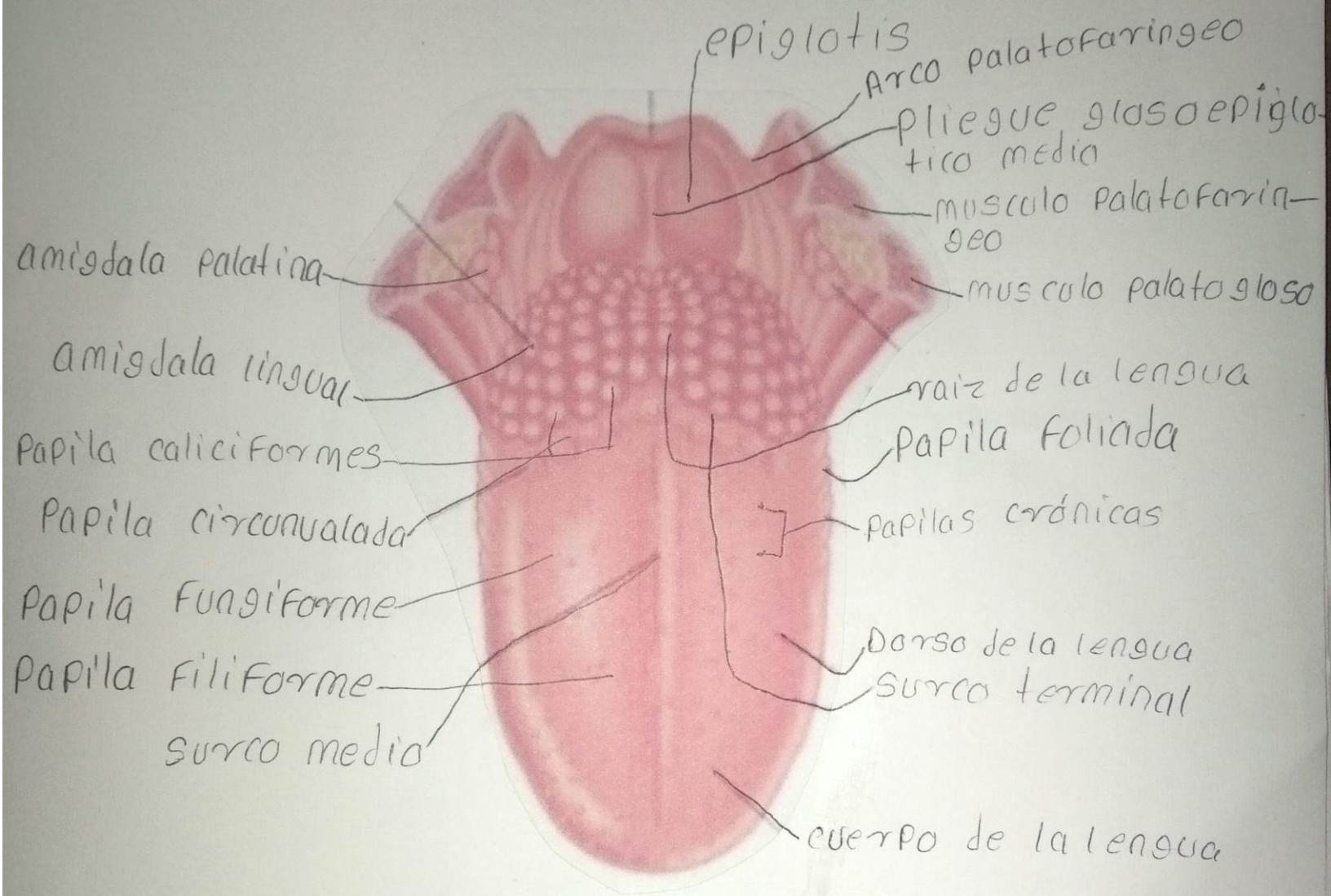
Peritoneo



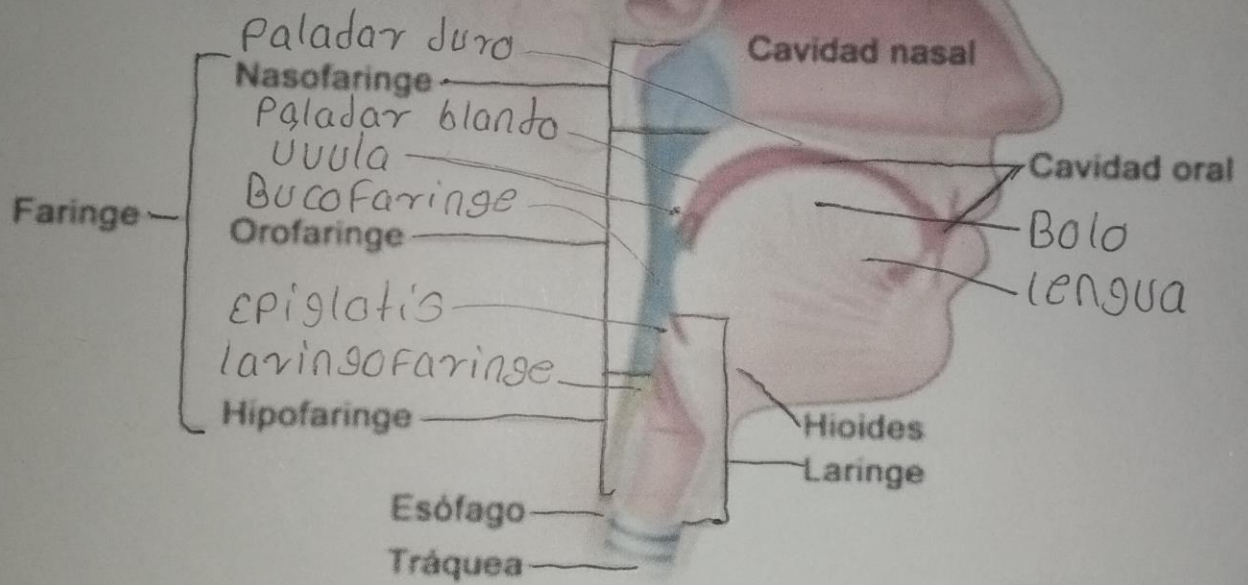
Boca: Paladar, Úvula, Lengua y Dientes



lengua



Fase faringea de la deglución



Glandulas salivales

Arco cigomatico
conducto parotideo

Orificio del
conducto para-
tideo

Ganglios
linfáticos

segundo molar
maxilar

Glándula
parótida

Lengua

frenillo lingual

conducto sublingu-
al menor

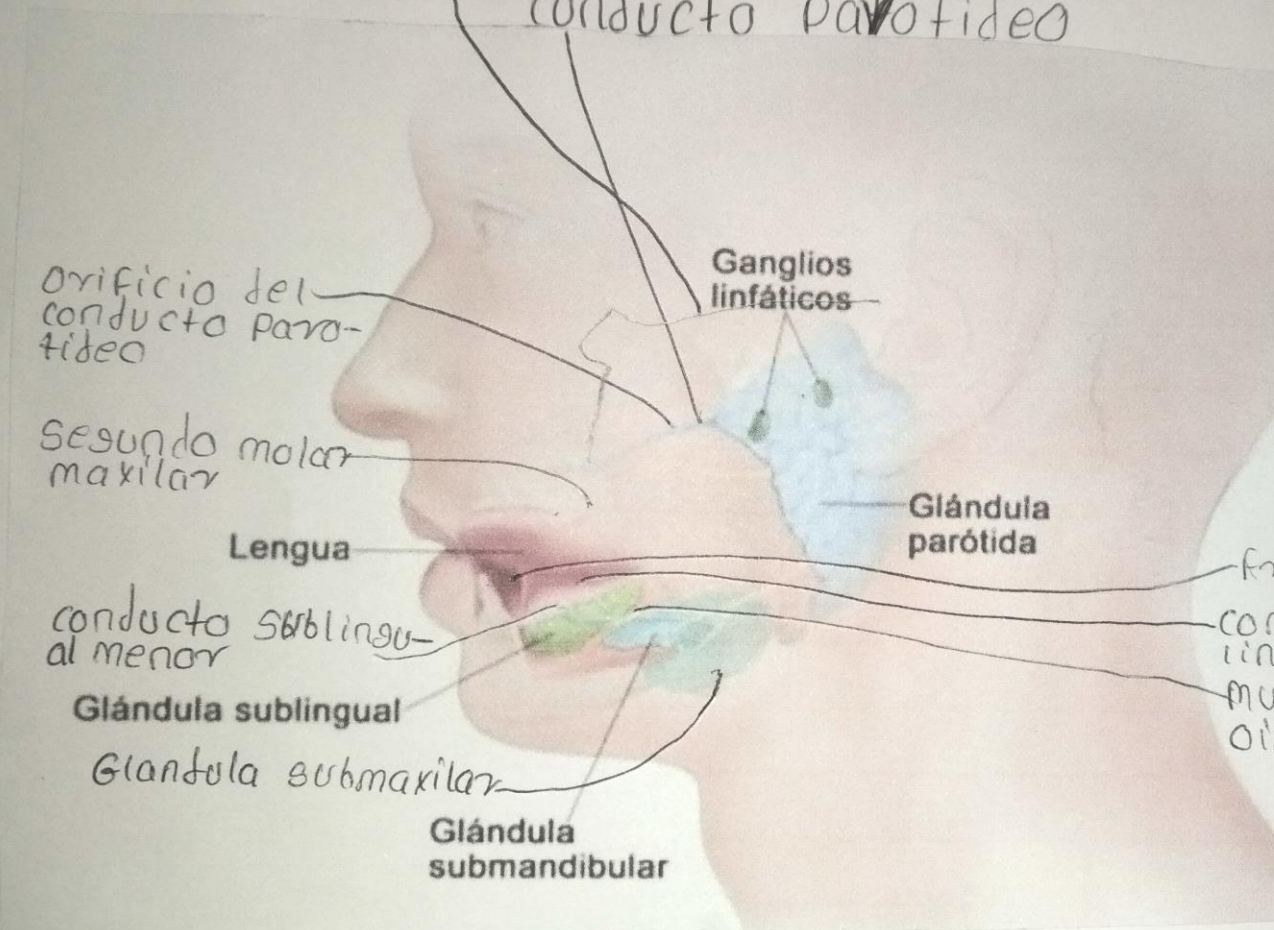
conductos sub-
linguales

Glándula sublingual

Musculo milohi-
oideo

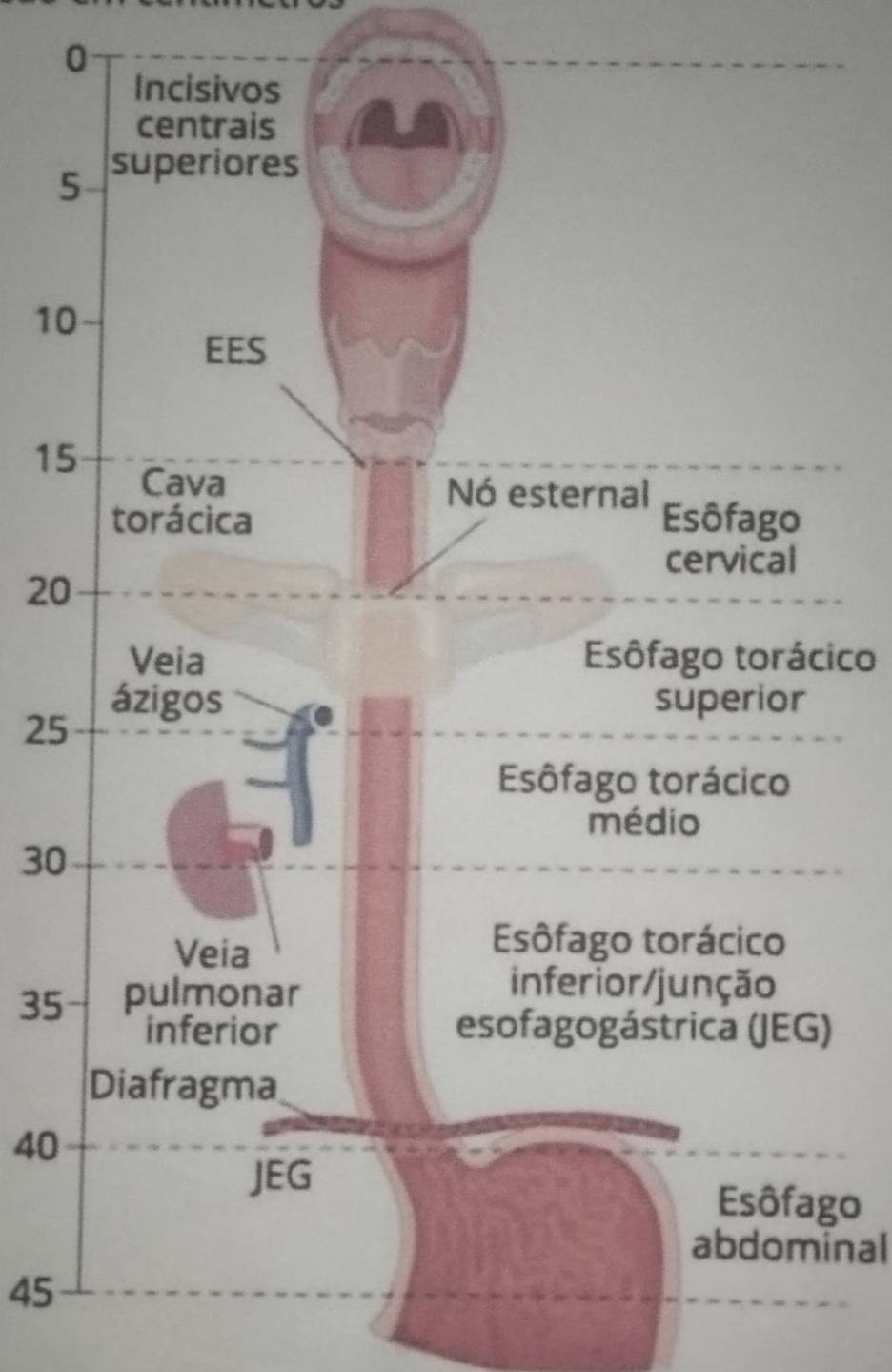
Glándula submaxilar

Glándula
submandibular

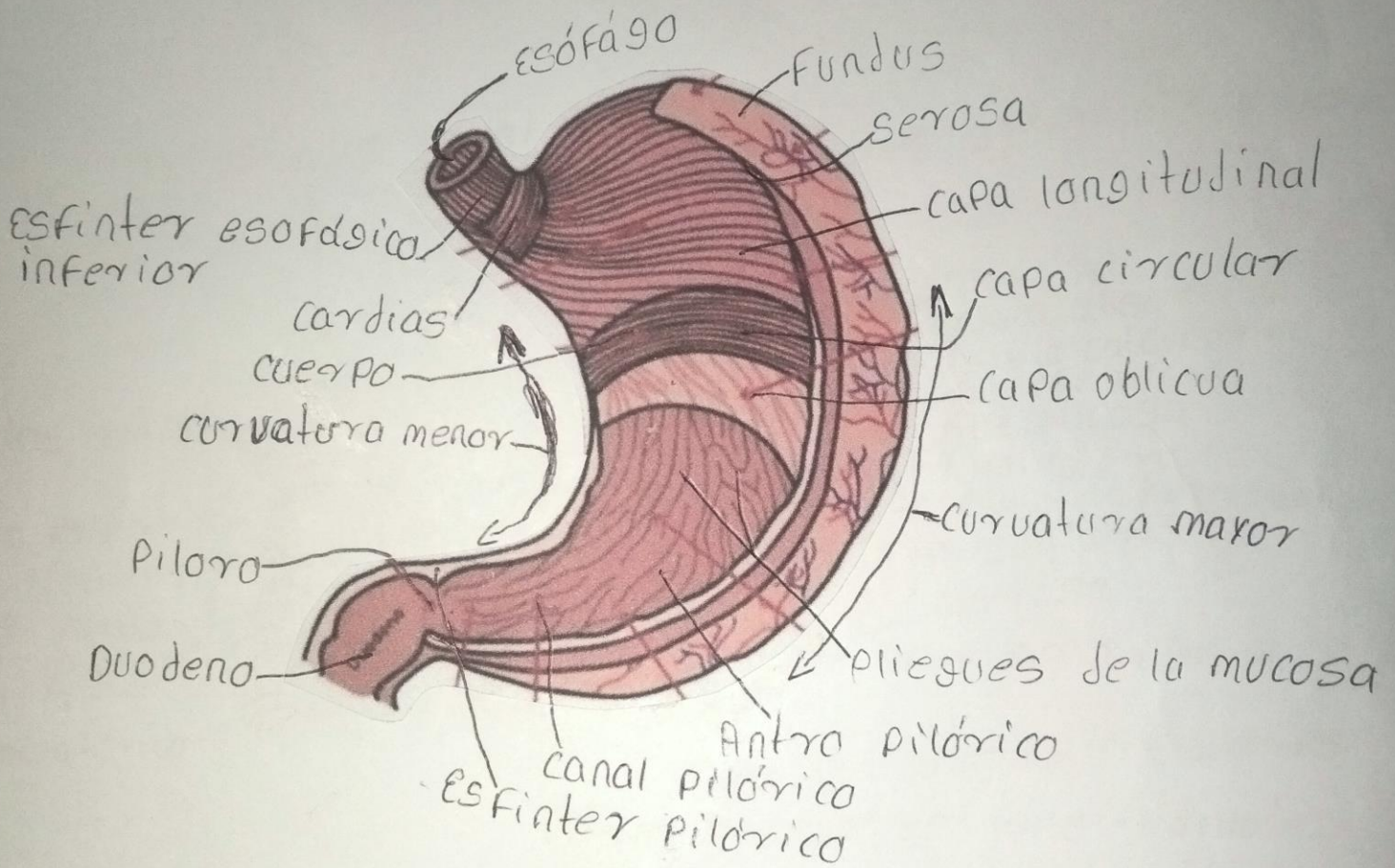


ESÓFAGO

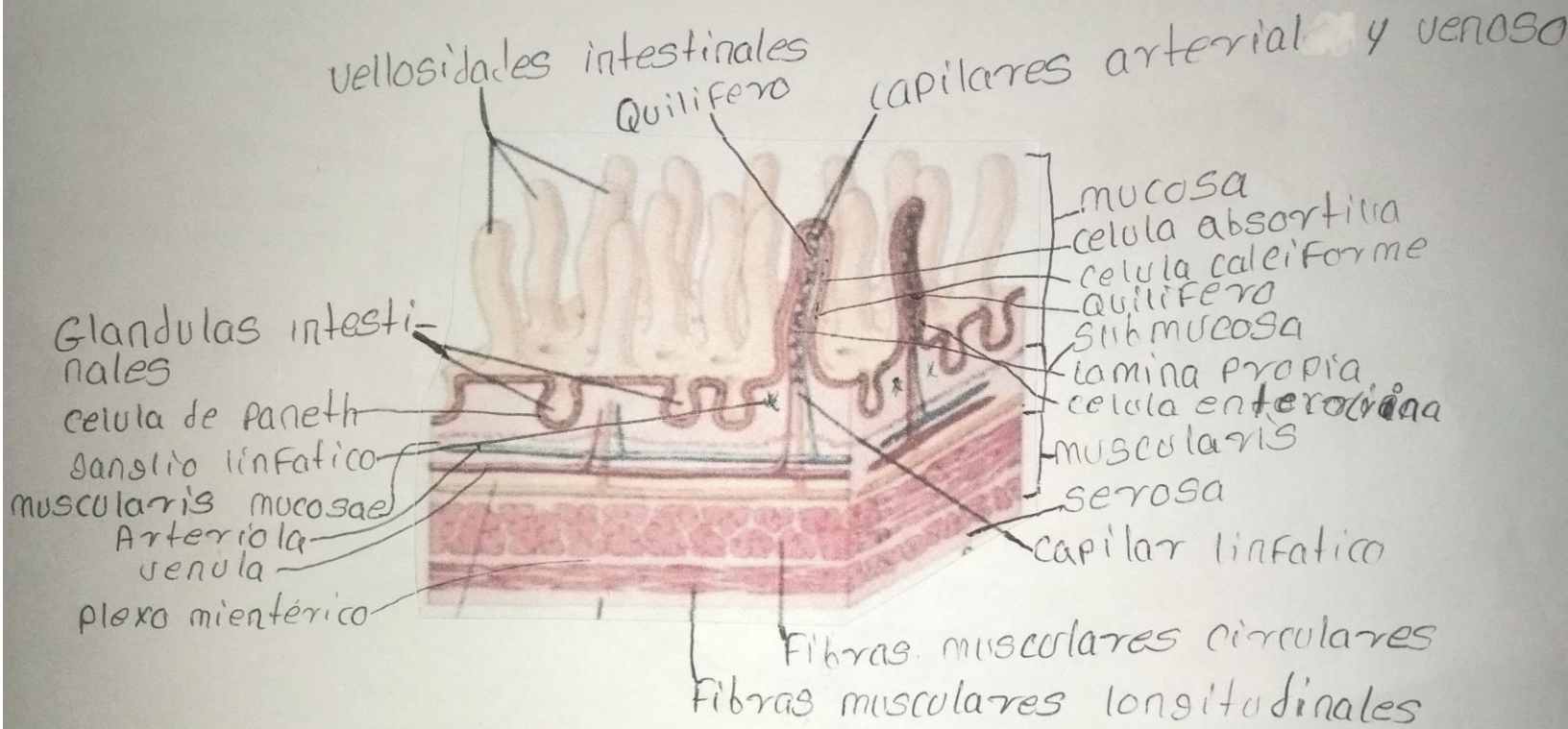
Extensão em centímetros



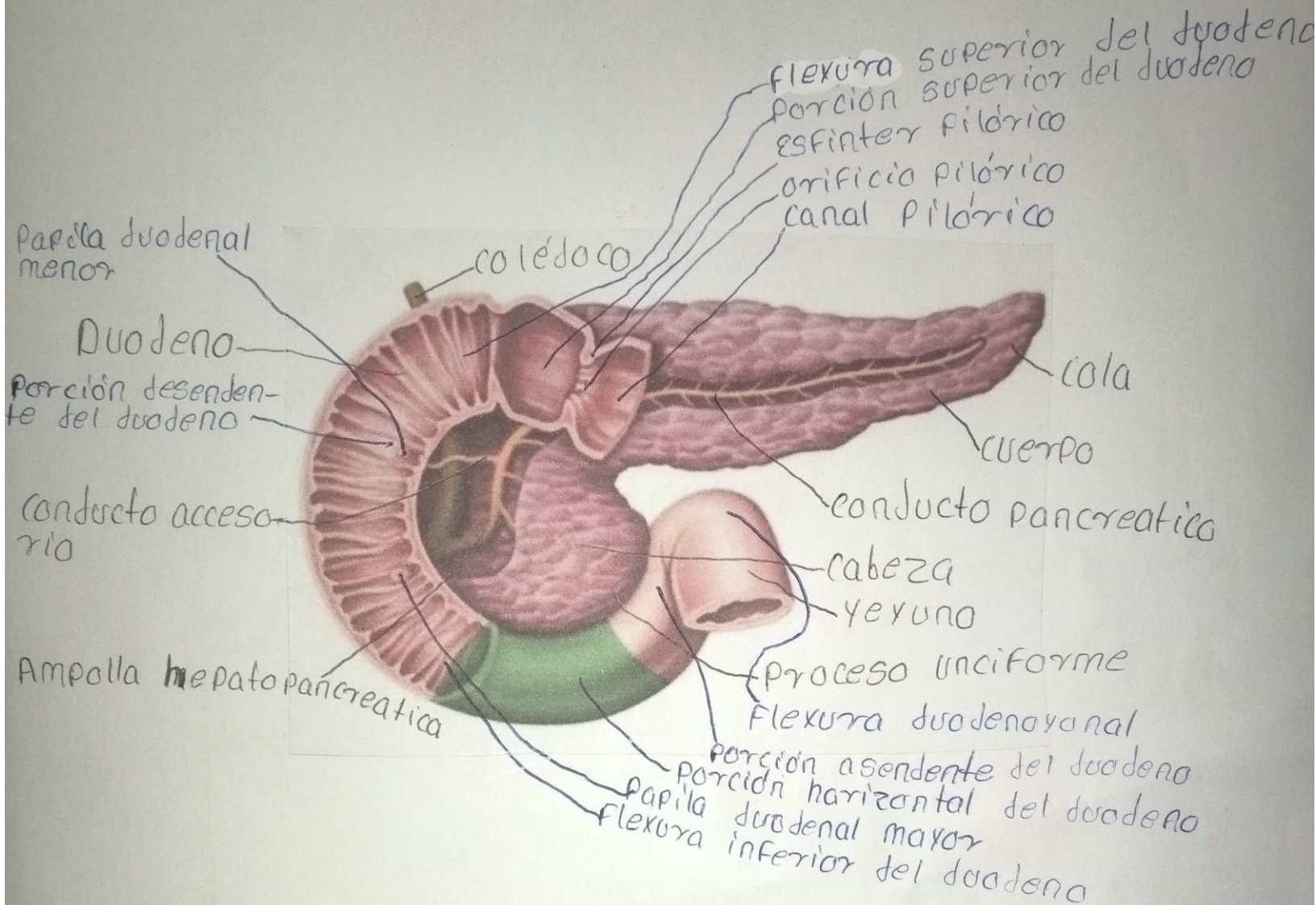
Estomago



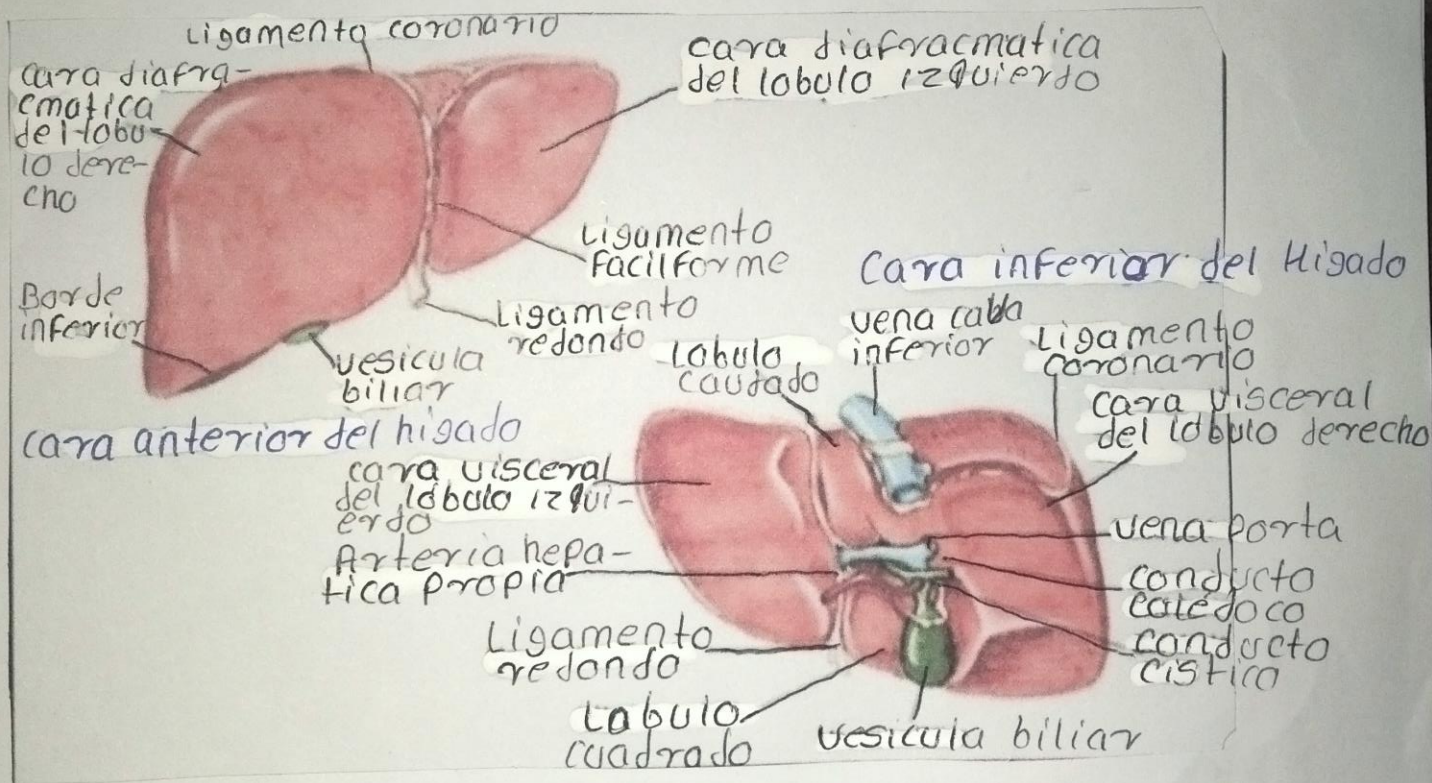
Vellosidades del intestino delgado



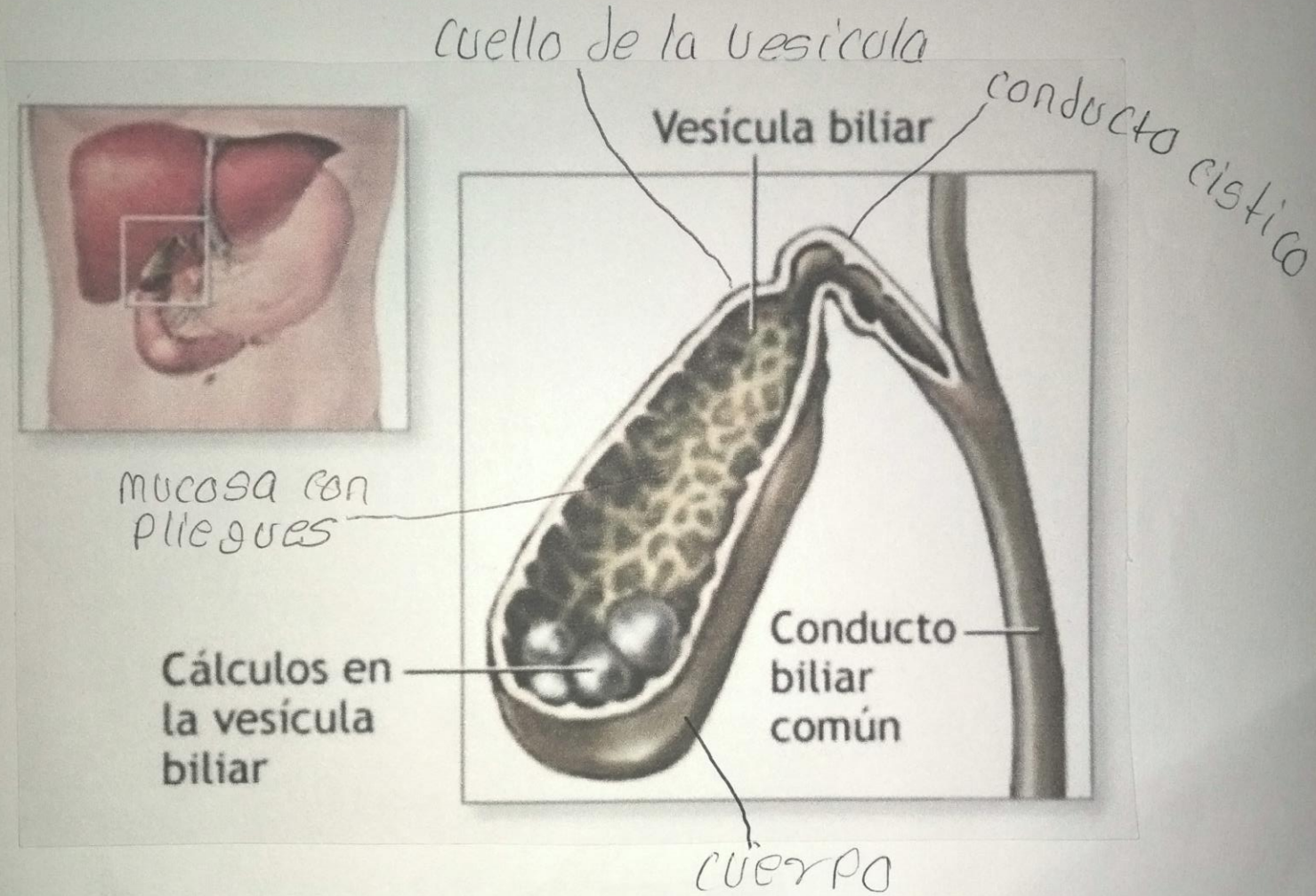
Pancreas



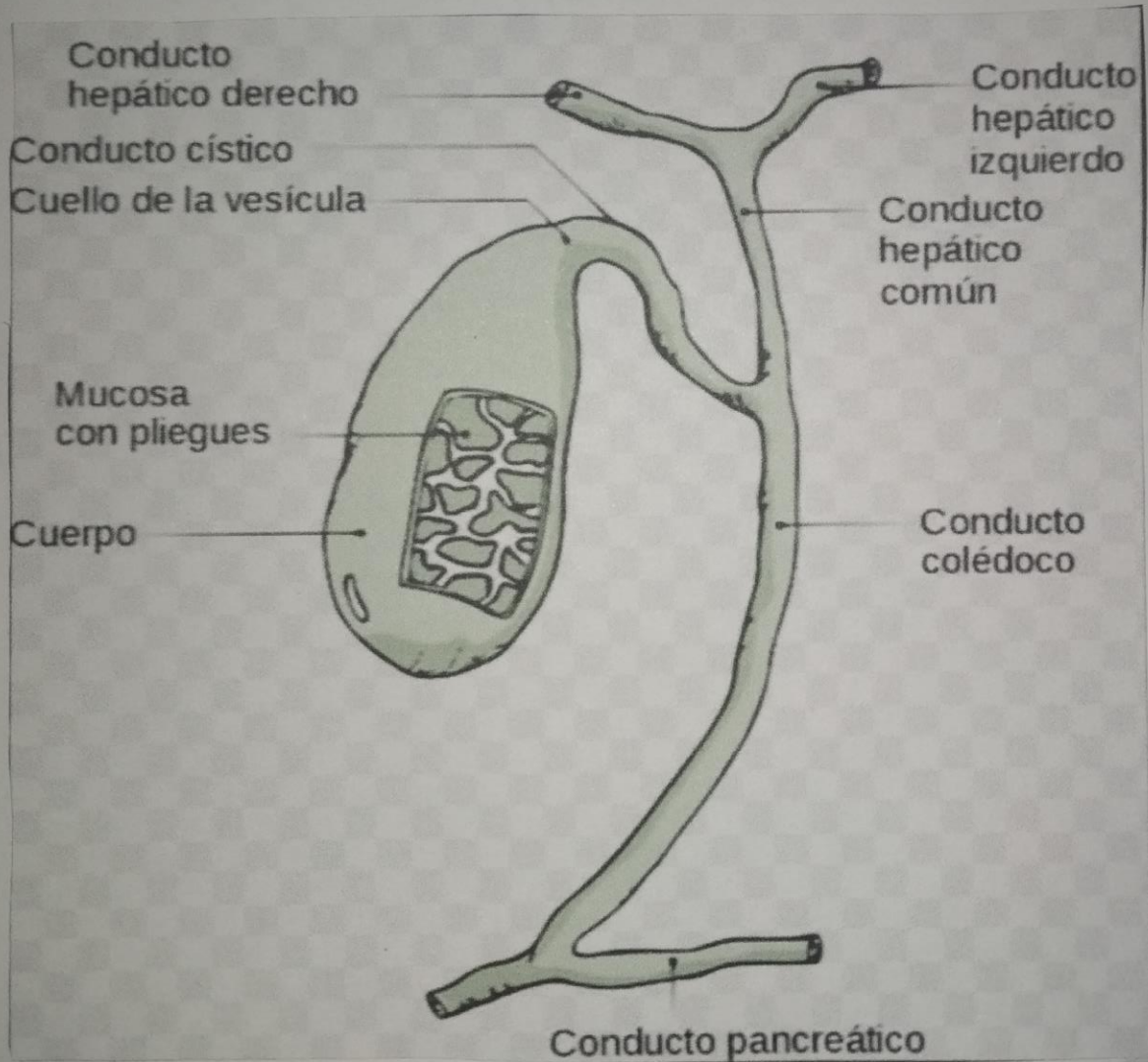
Migado



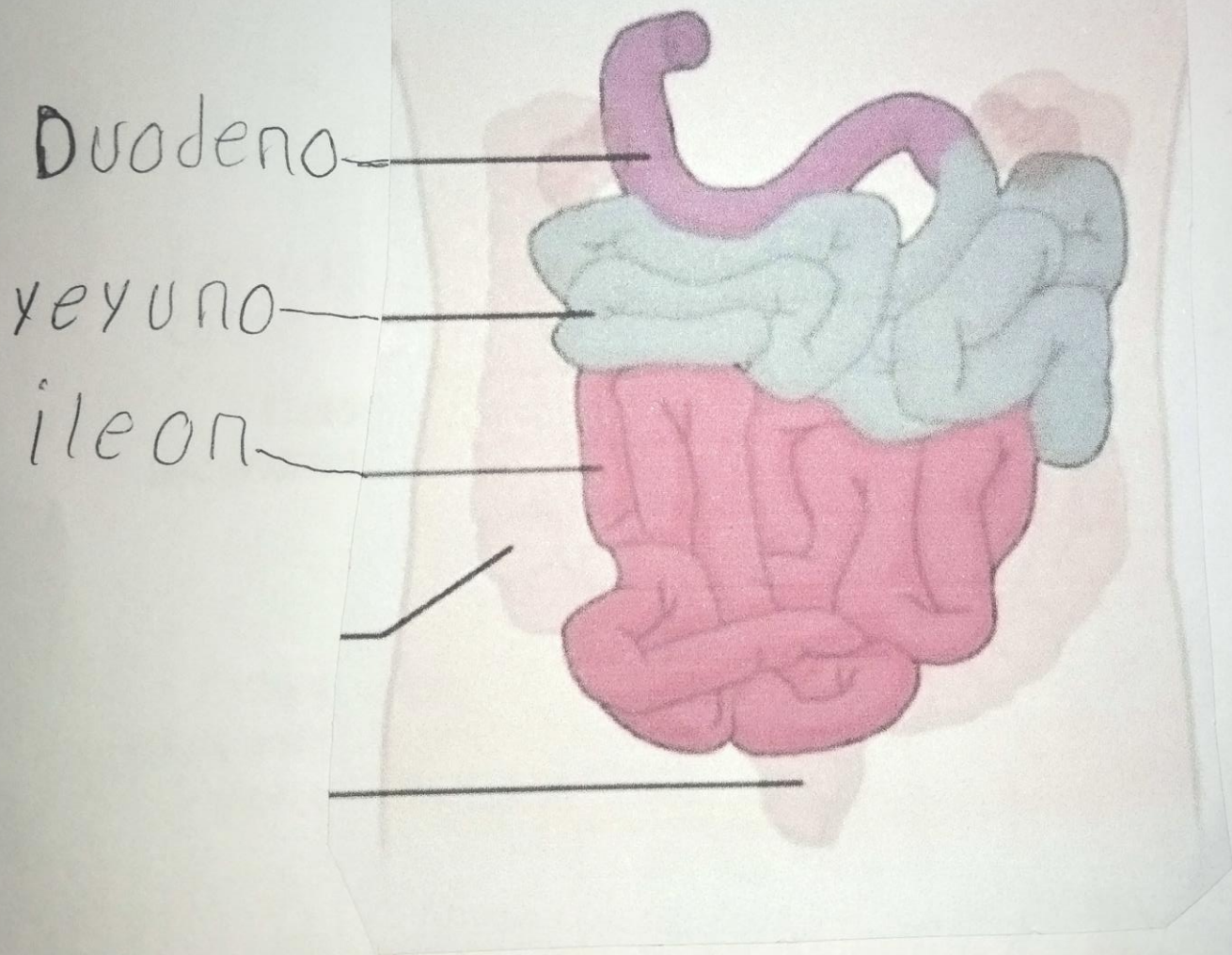
Vesícula biliar



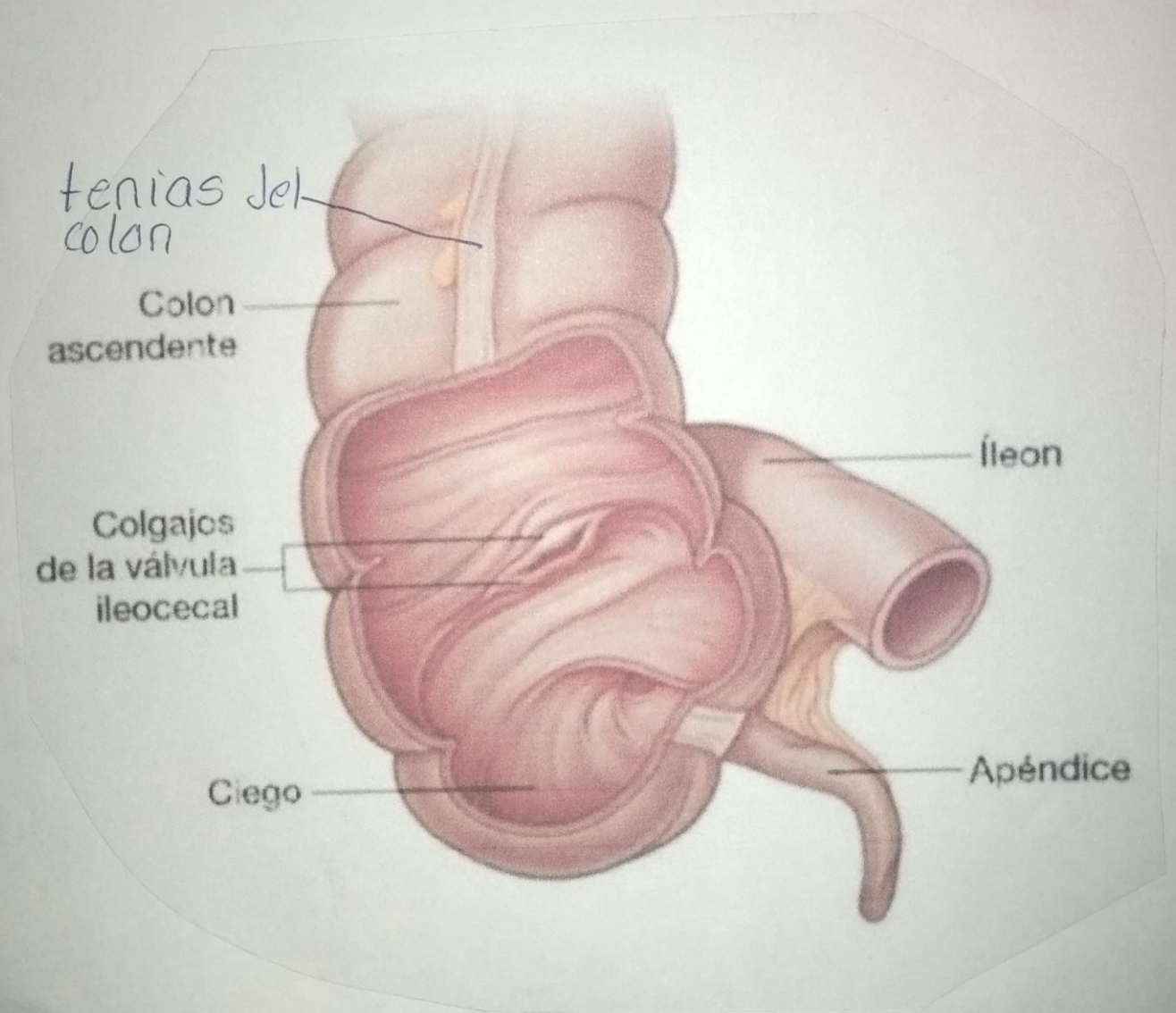
conducto biliar



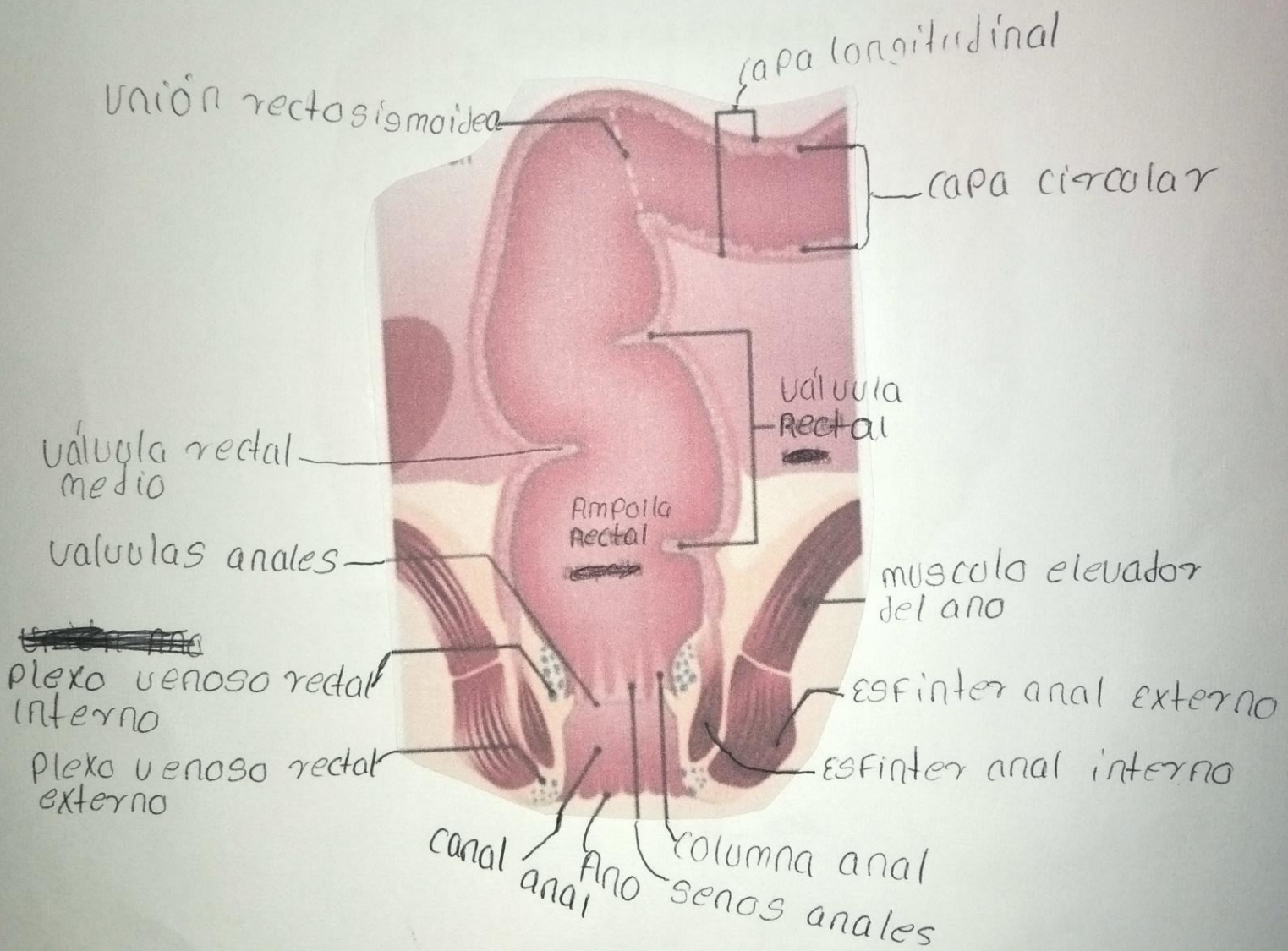
intestino delgado



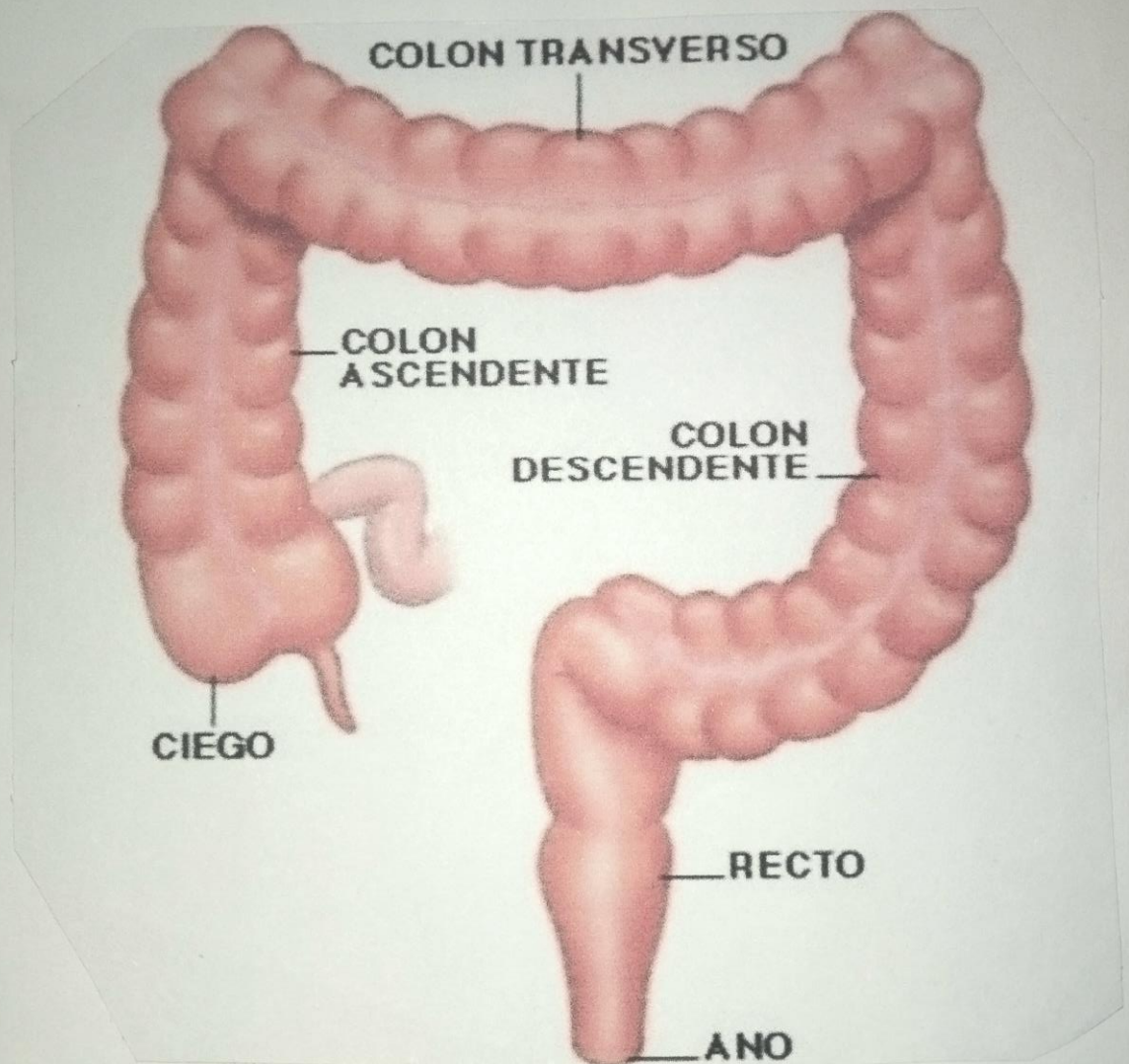
Ciego y apéndice



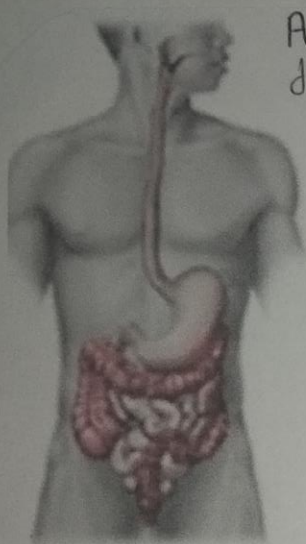
Ano o recto



Intestino grueso



Colón sigmoide, trasverso, descendente y ascendente



Angulo cólico derecho

Colon transverso

Angulo cólico izquierdo

tenias del colon

Apéndices epiploicos

Colon descendente

Haustra

Colon ascendente

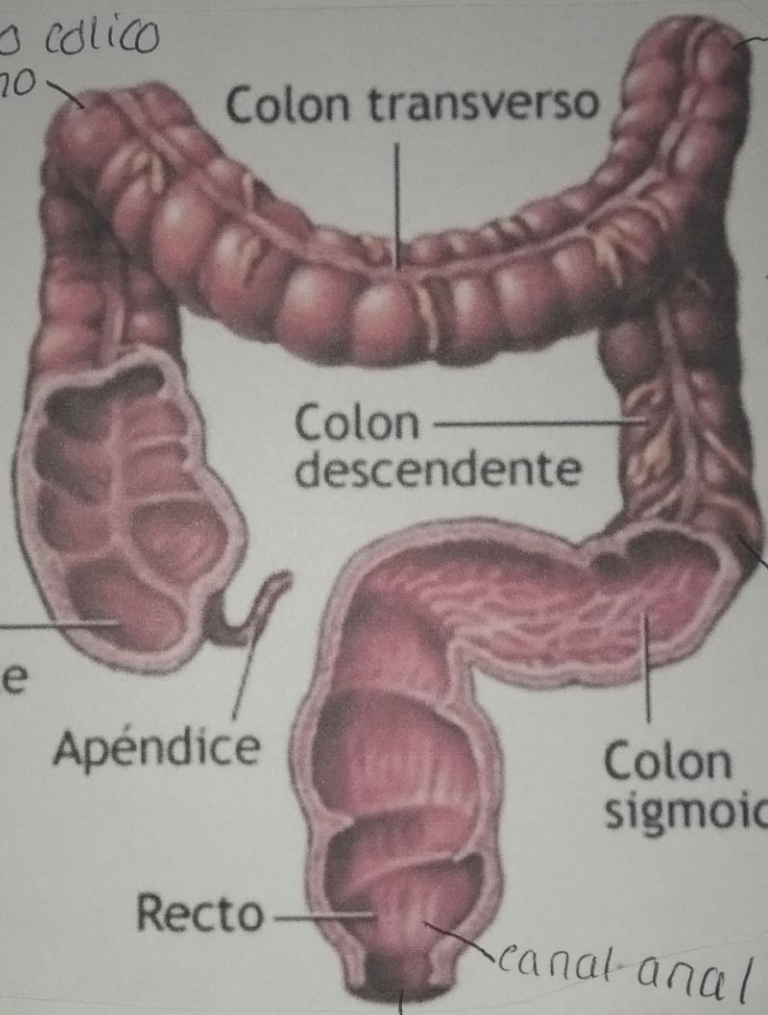
Apéndice

Colon sigmoide

Recto

canal anal

Ano



Bibliografía

Principios de anatomía y fisiología tortora derrickson...edicos.org