



CARRERA: MEDICINA HUMANA

MATERIA: CLÍNICAS PEDIÁTRICAS

ESQUEMAS CARDIOPATÍAS CONGENITAS

VIVIANA EDITH ROJAS TORRES

7° SEMETRE

Cardiopatías congénitas

Acianóticas

Cianóticas

Handwritten: Cianóticas

Flujo pulmonar aumentado
Shunt izq → der

Flujo pulmonar normal o disminuido
(obstructivas)

Flujo pulmonar aumentado

Flujo pulmonar disminuido

CIV

Estenosis aortica

Transposición de grandes arterias

Tetralogía de Fallot

CIA

Coartación aortica

Tronco arterioso

Atresia pulmonar

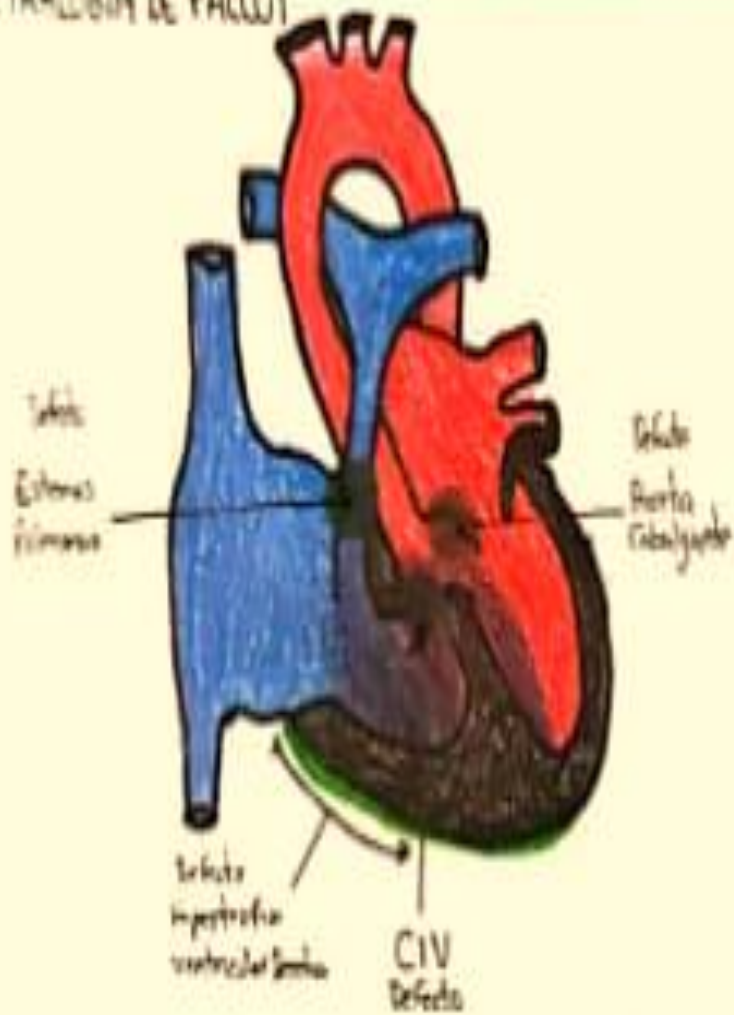
Ductus arterial persistente

Estenosis valvular pulmonar

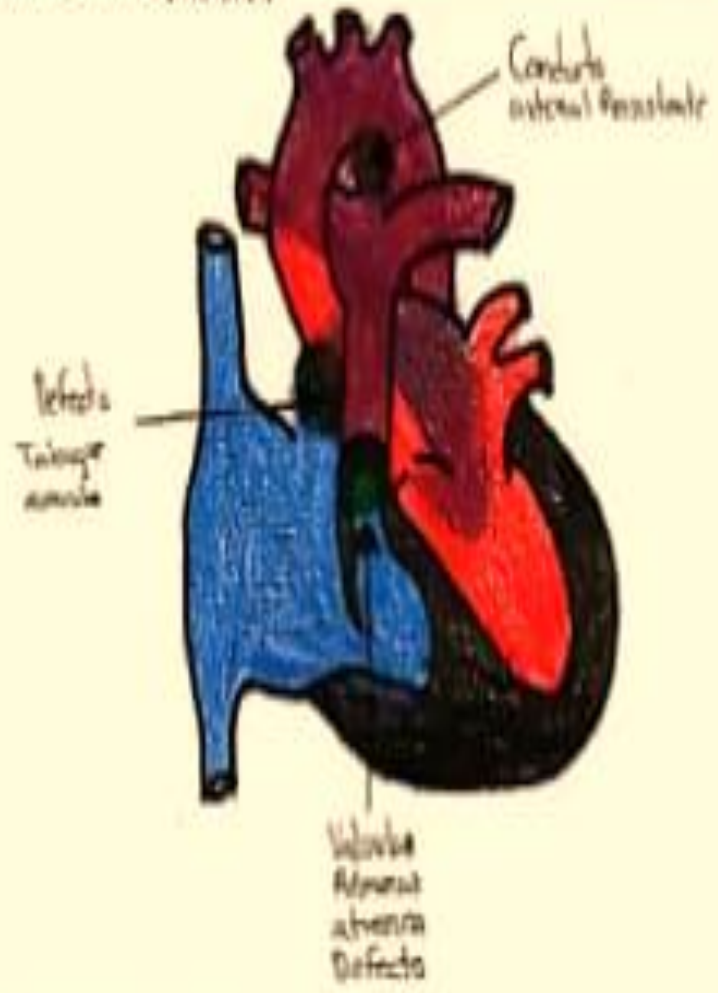
Ventrículo único

Atresia tricuspidea

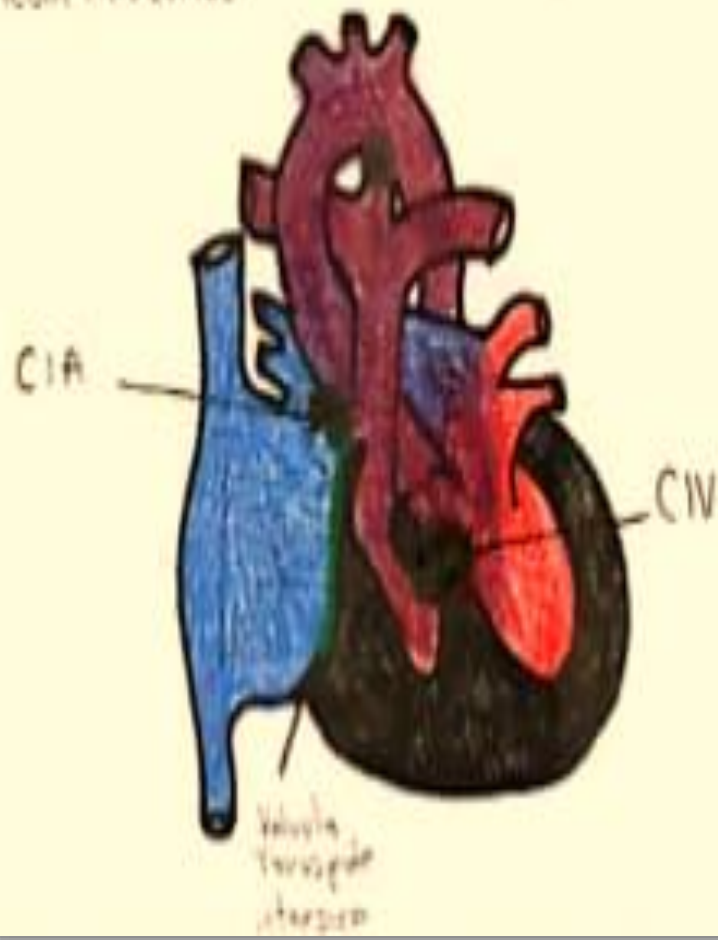
TETRALOGIA DE PALLOT



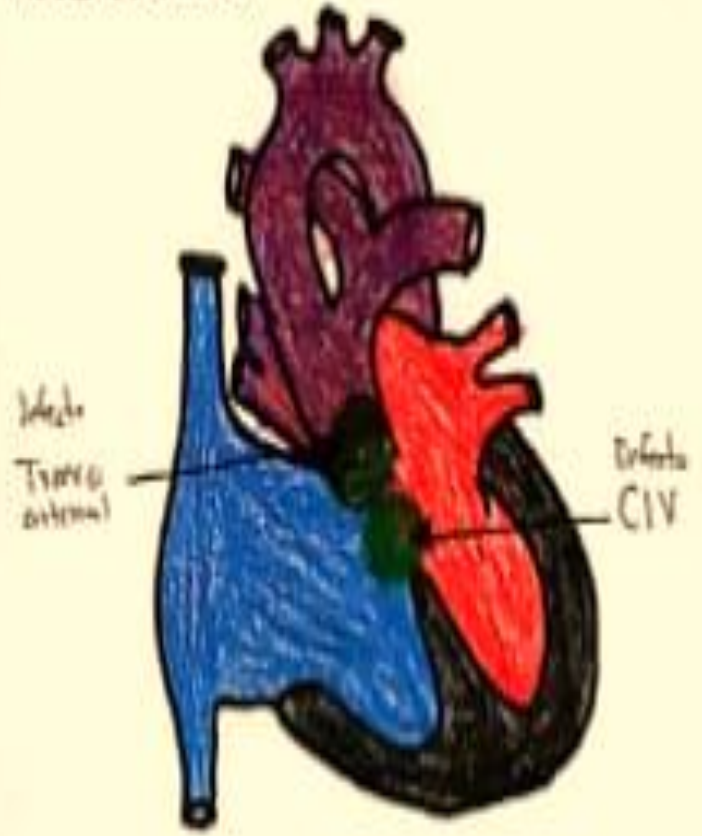
ATRESIA PULMONAR



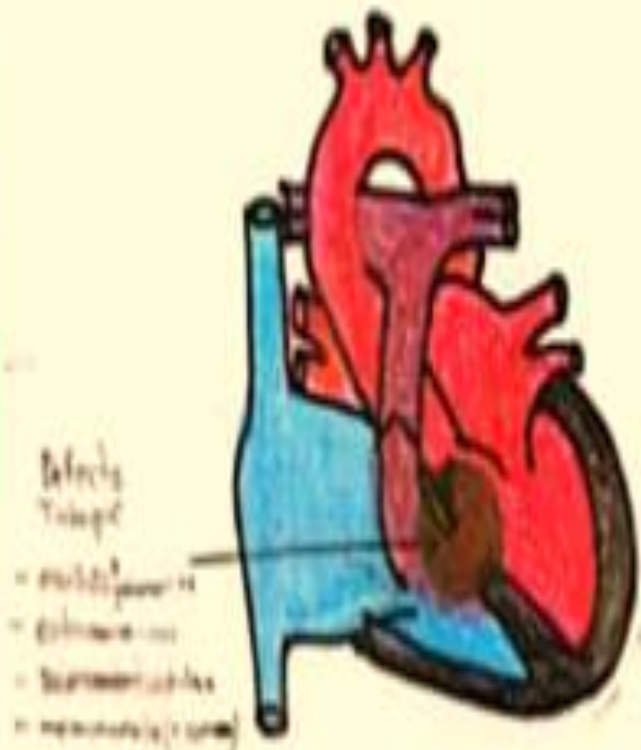
ATRESIA TRICUVIDE



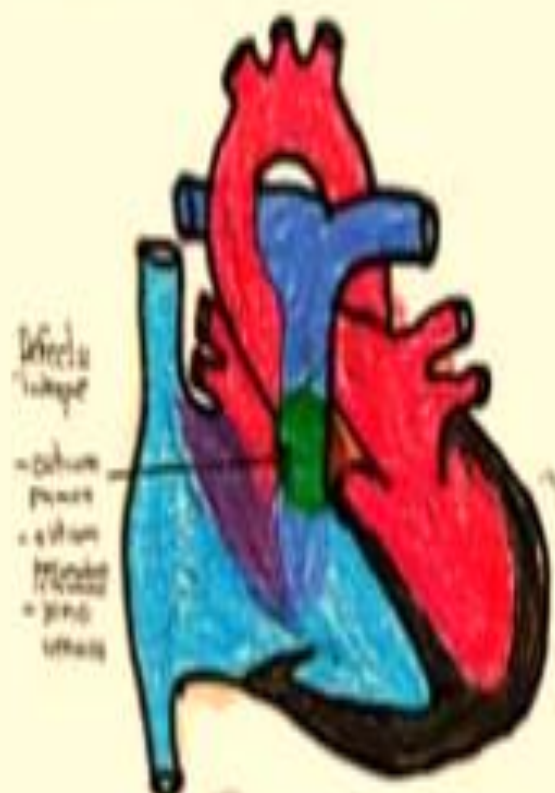
TRONCO ARTERIOSO



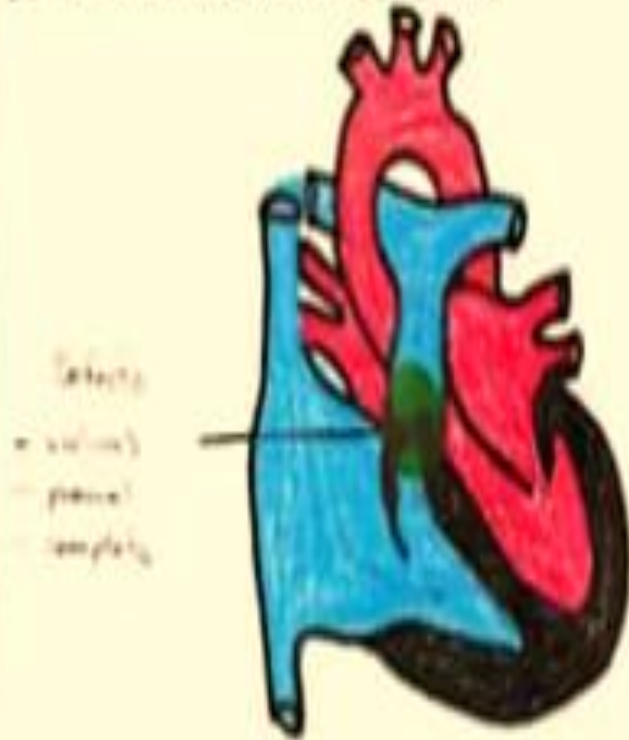COMUNICACION INTERVENTRICULAR



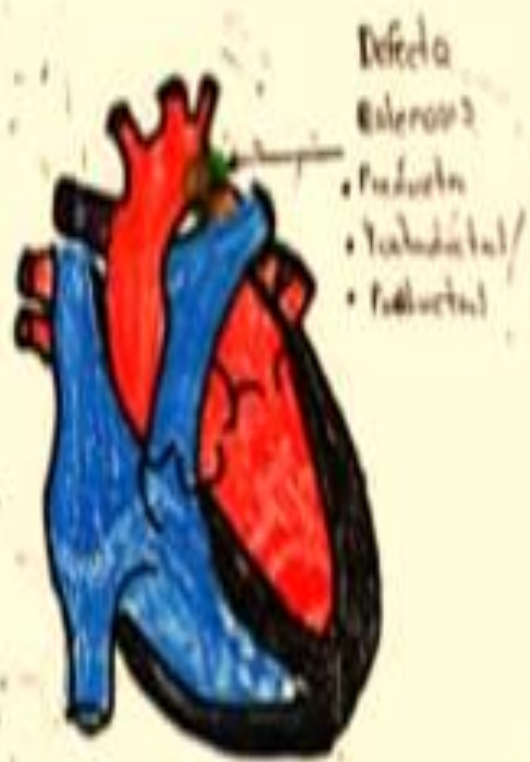COMUNICACION INTERAURICULAR



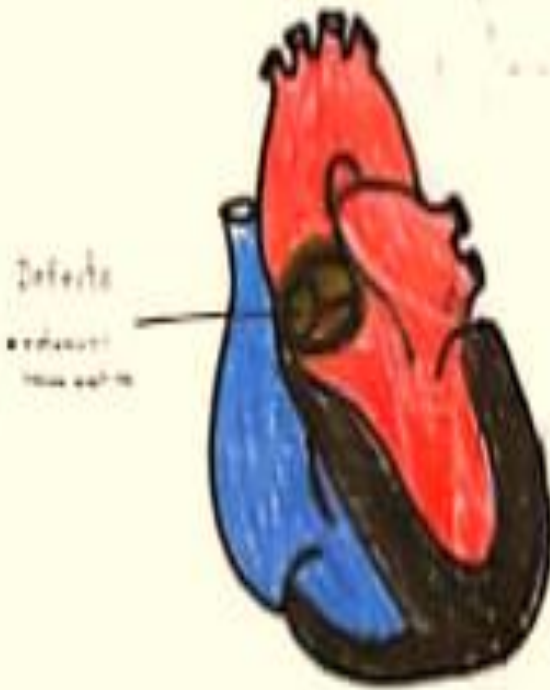
ESTENOSIS VALVULAR PULMONAR



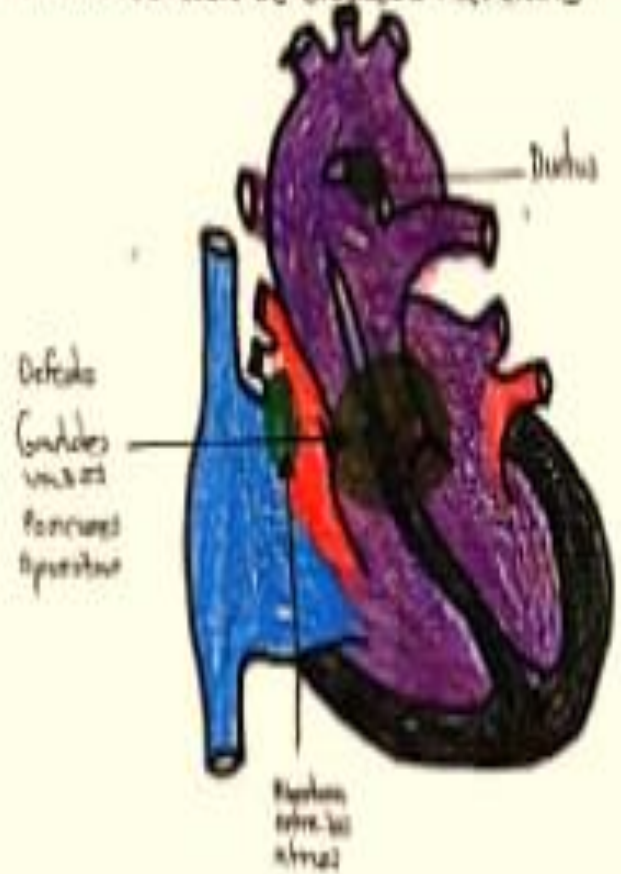
COARCTACION DE LA AORTA



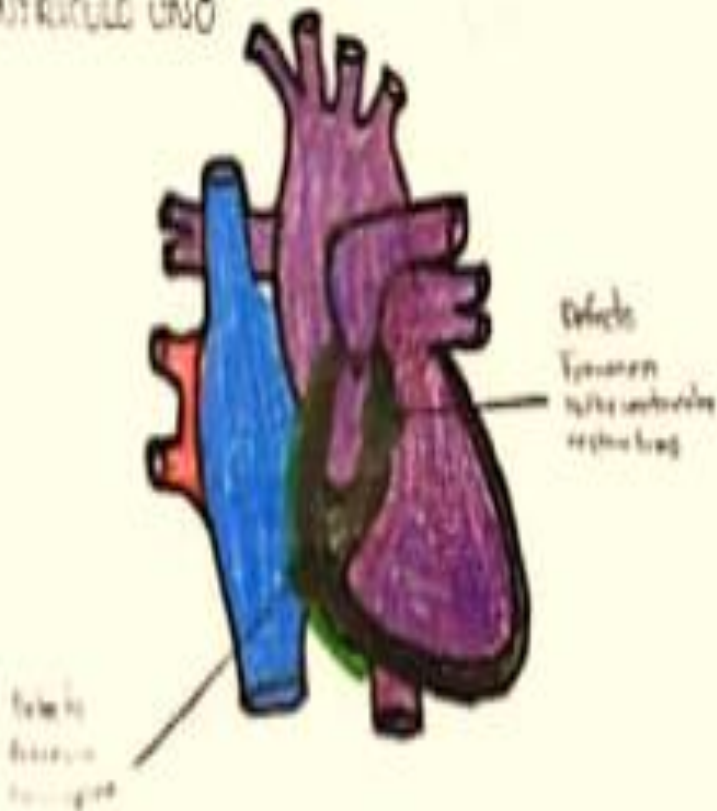
ESTENOSIS AORTICA



TRANSPOSICION DE GRANDES ARTERIAS



VENTRICULO UNO



DUCTUS ARTERIAL PERSISTENTE

