

Anan Villatoro Jiménez

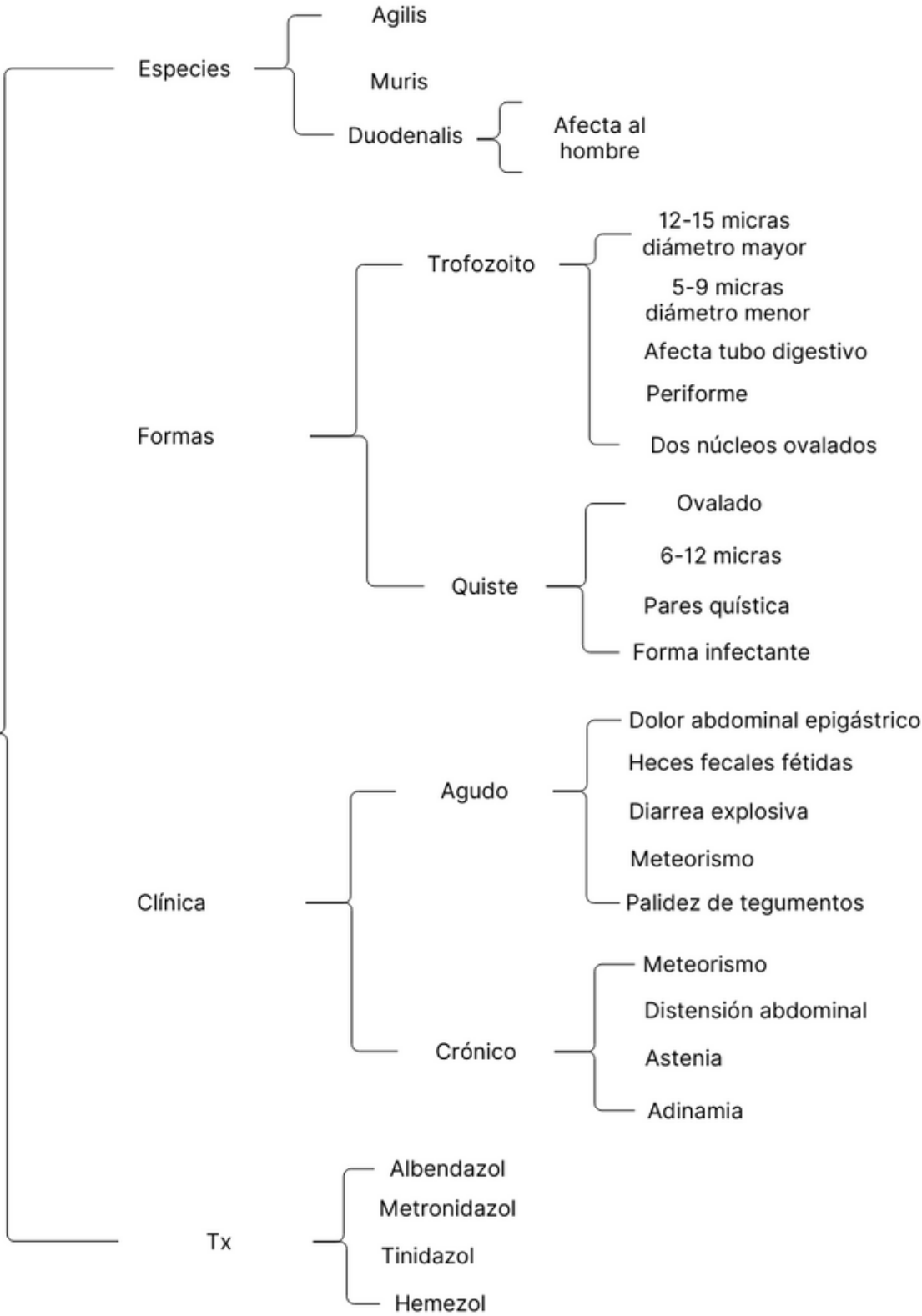
QFB. Hugo Nájera Mijangos

Microbiología y parasitología

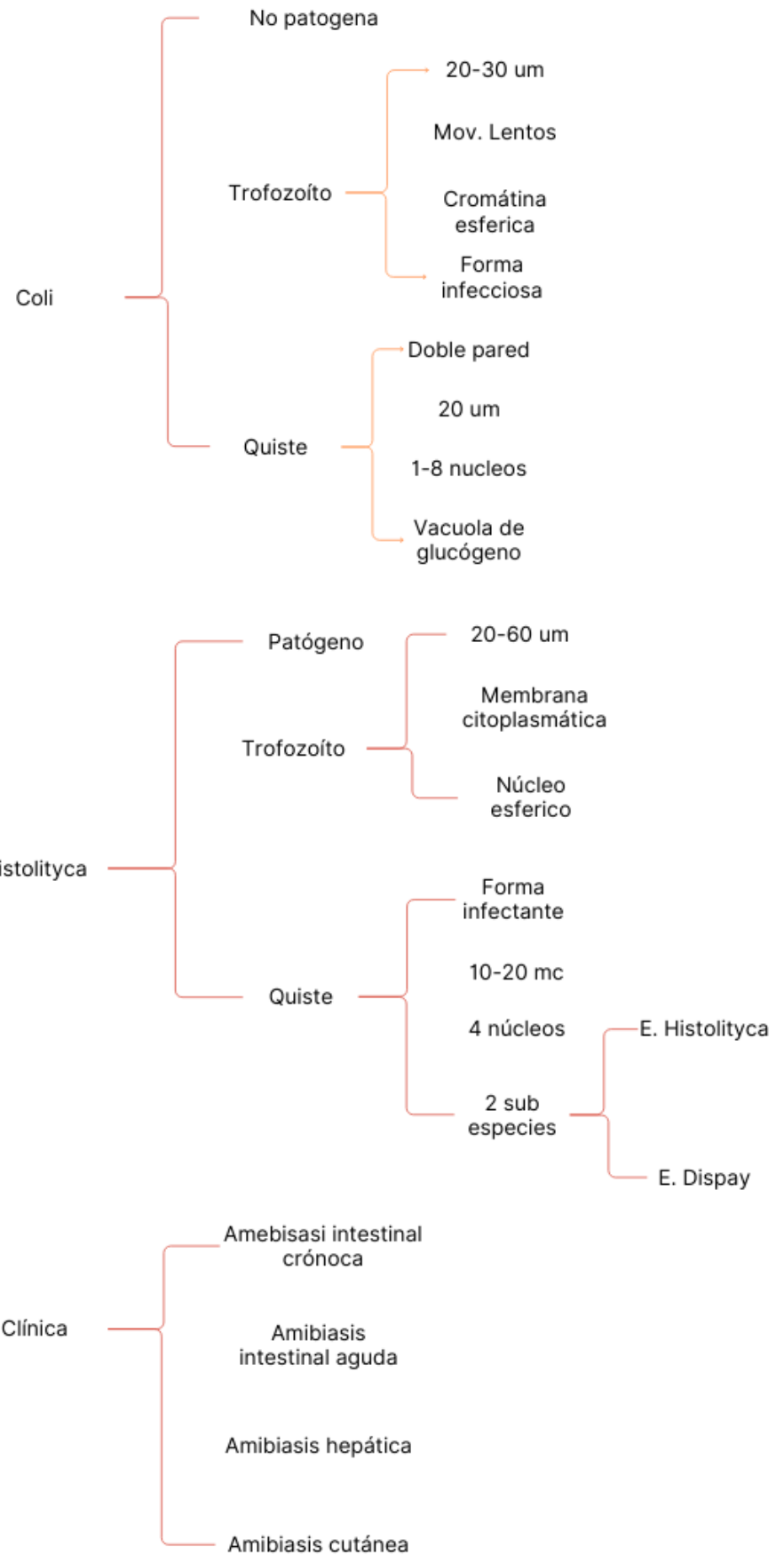
Parasitología

2C

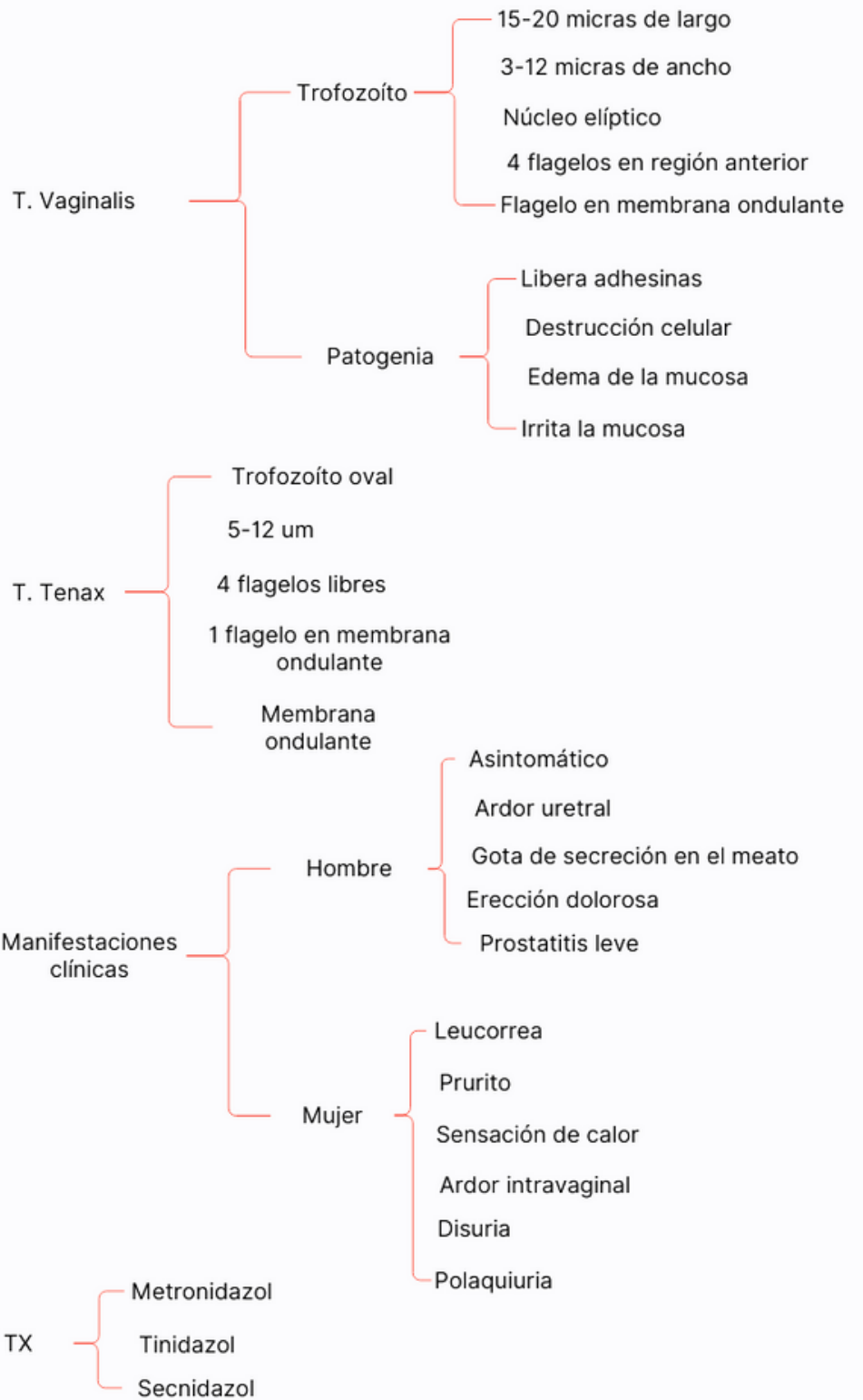
GIARDIA LAMBIA



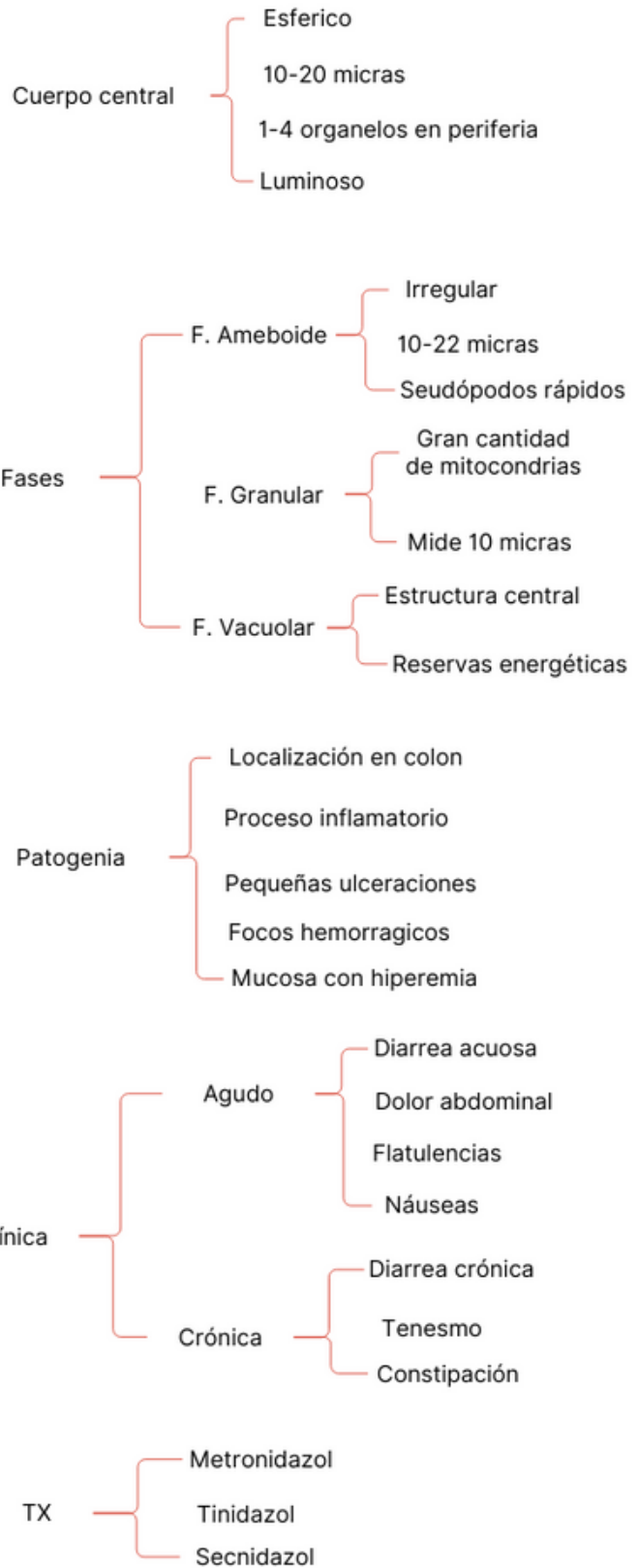
ENTAMOEBA



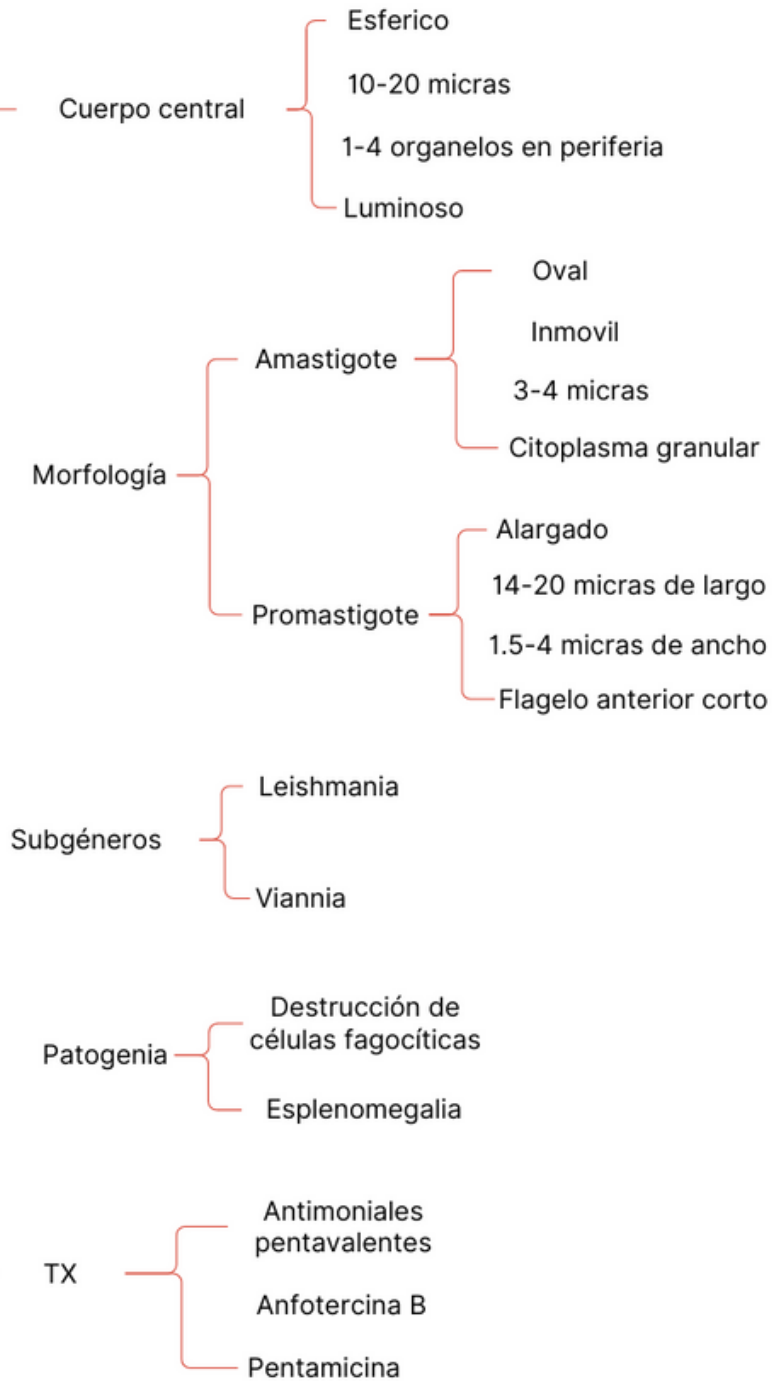
TRICHOMONA



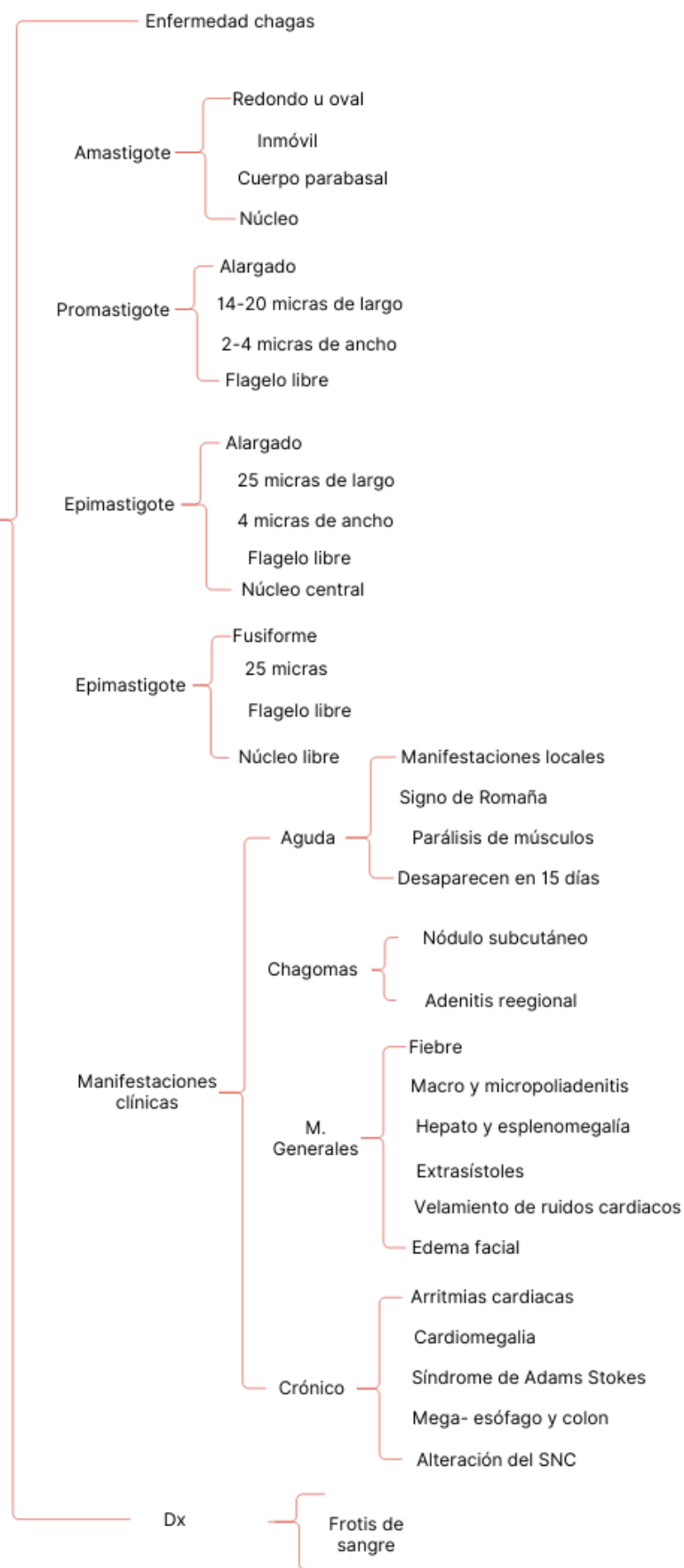
BLASTOCISTIS HOMINIS



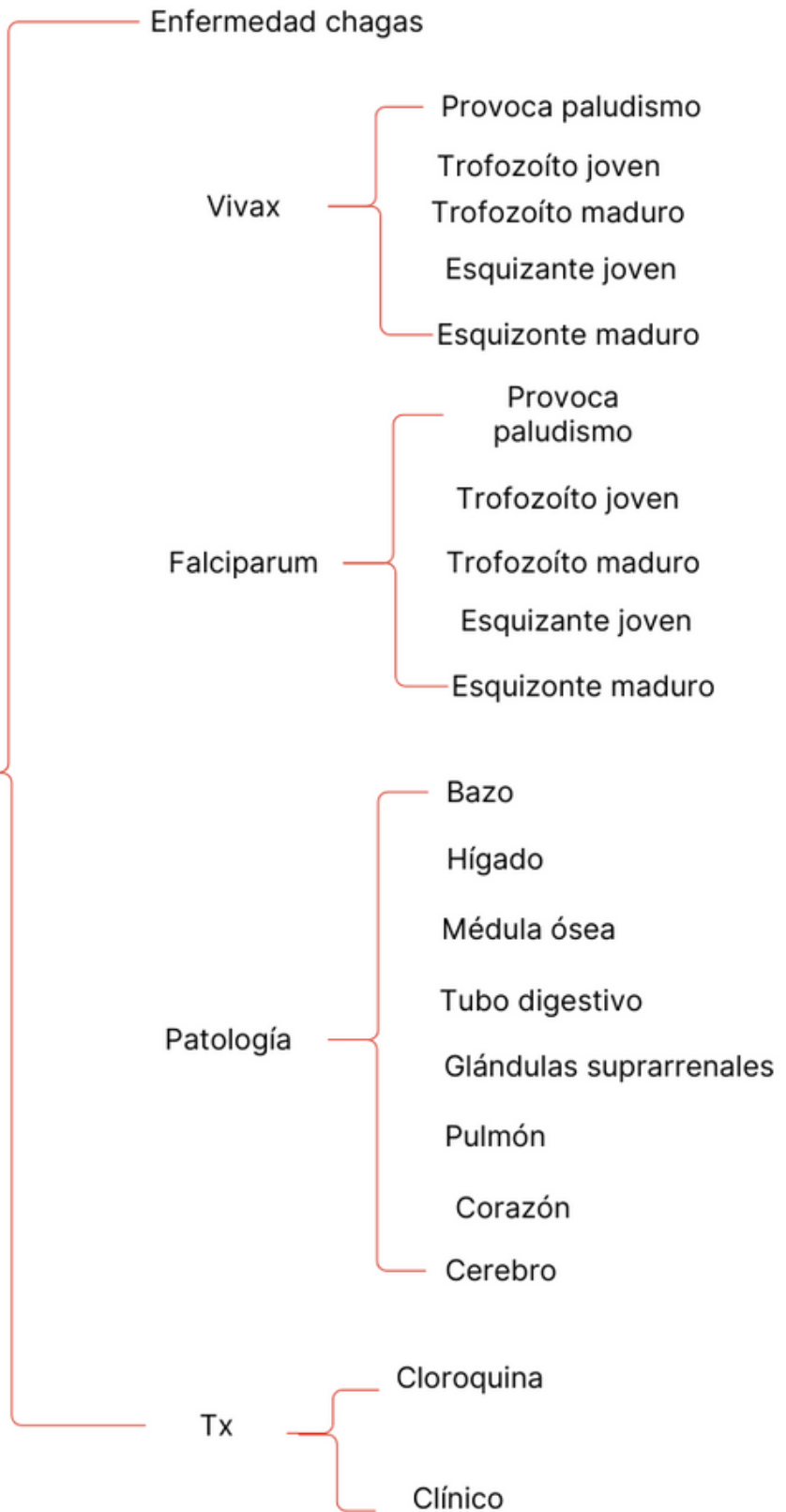
LEISHMANIA



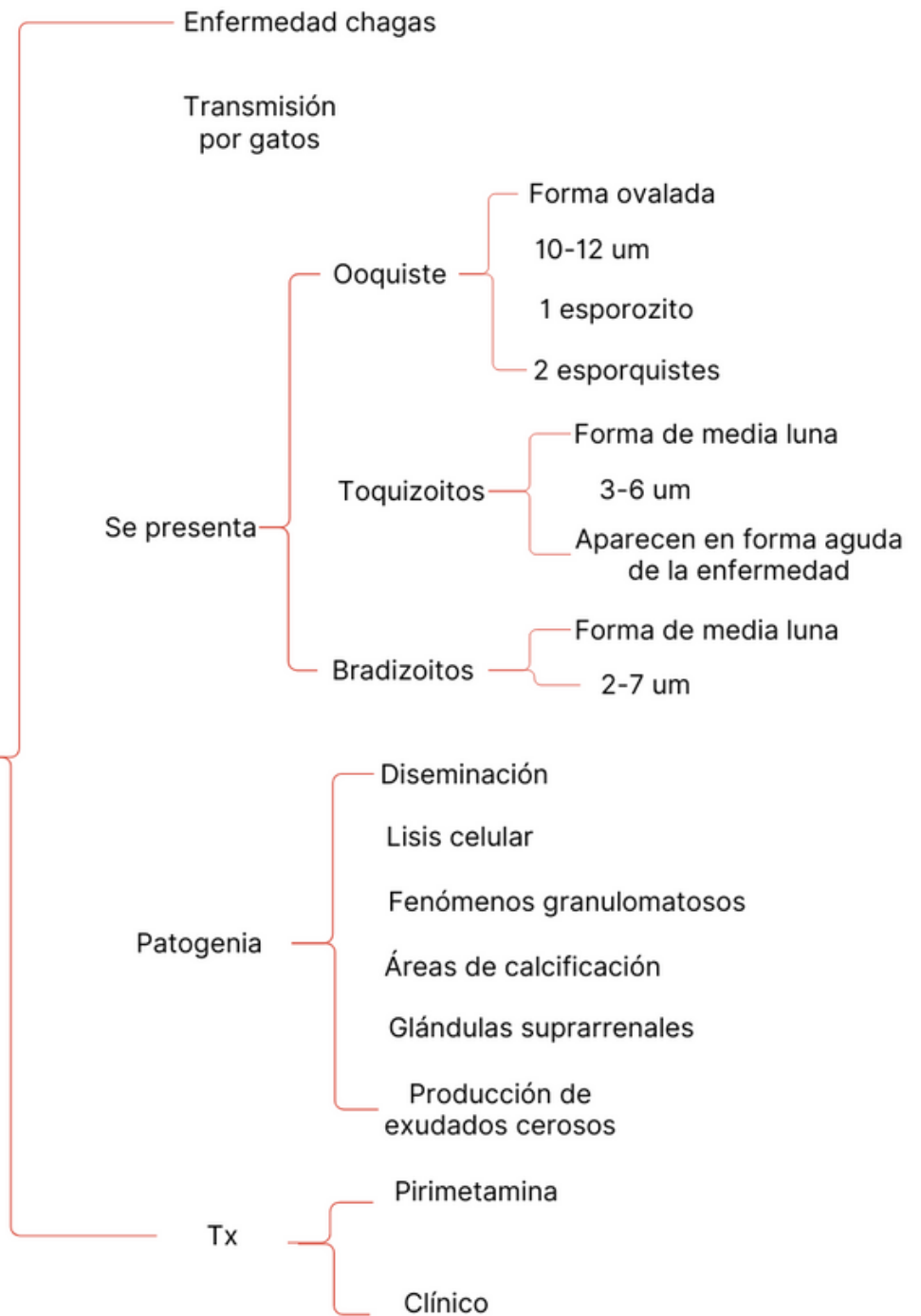
TRIPANOSOMA CRUZI



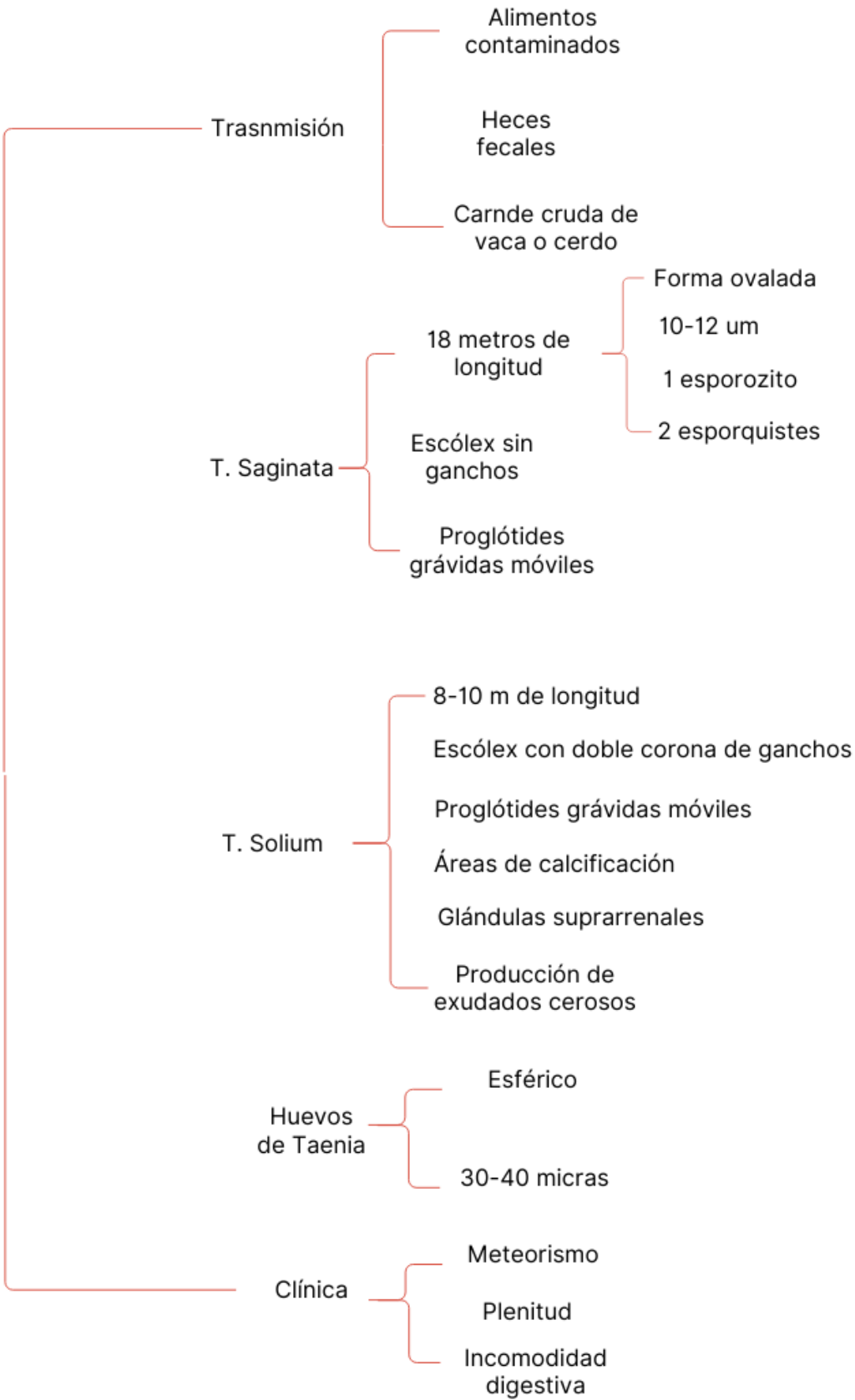
TOXOPLASMA



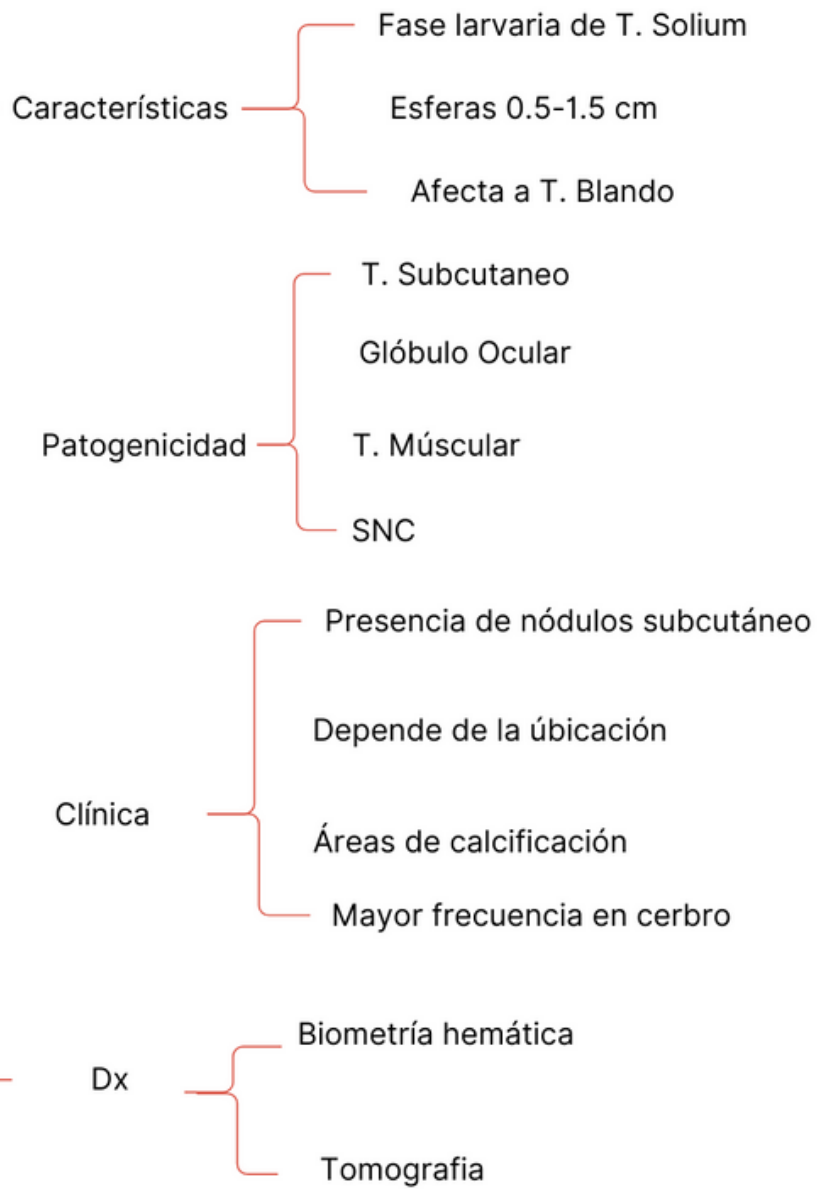
PLASMIDIUM



TAENIA



CISTICERCOS



FASCIOLA HEPATICA

Características

- 3 cm adulto
- Huevos 140x 175 μ m
- Miracidio 128 x 25 μ m
- Cercarias 300 μ m largo
270 μ m ancho
- Esporquiste 550 μ m

Fases

Migratoria

- Fiebre
- Dolor lumbar
- Dolor abdominal
- Urticaria

Estado

- Colicos biliares
- Nauseas
- Dolor abdominal
- Prurito generalizado
- Hepatomegalia
- Ictericia

Patogenia

- Irritación de la pared intestinal
- Cocos hemorragicos e inflamación
- Eosinofilia
- Tejido necrotico

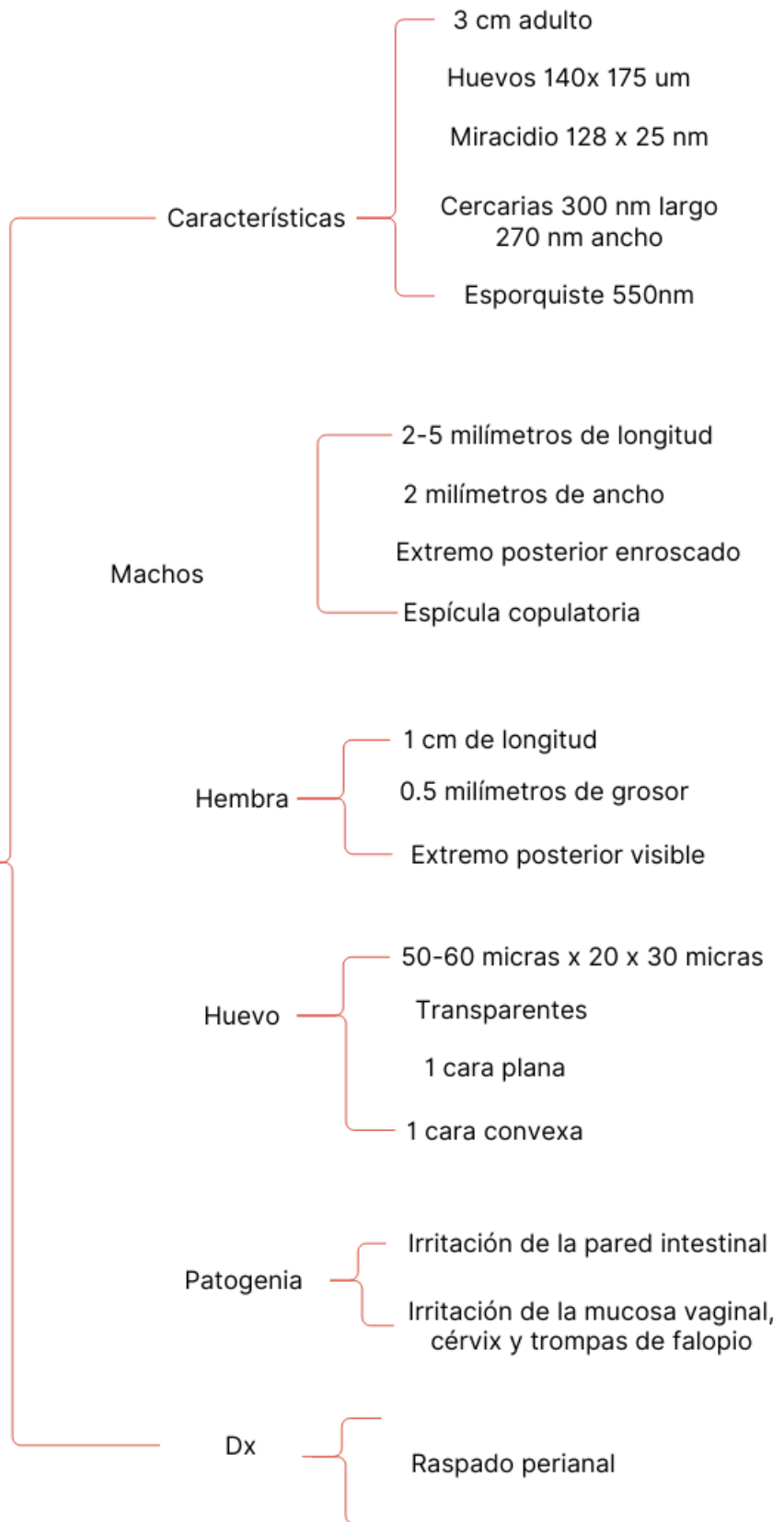
Dx

- Capsula de Beal
- Biometria hematica
- Coproparasitoscópicos

Tx

- Dehidrometina
- Bitionol
- Albendazol

ENTEROBIUS VERMICULARIS



TRICHURIS TRICHURIA

Machos

- 30-45 milímetros
- Extremo posterior enroscado
- Forma de látigo
- Espícula copulatoria

Hembra

- 35-50 milímetros
- Forma de látigo
- Extremo posterior rombo

Huevo

- 50-60 micras x 25-30 micras
- Forma de barril
- Cubierta triple
- 2 tapones mucosos

Patogenia

- Inflamación difusa
- Descamación de pared abdominal
- Acción exfoliativa
- Aumento del peristaltismo
- Estimulación de plexos nervioso
- Focos hemorrágicos en pared intestinal

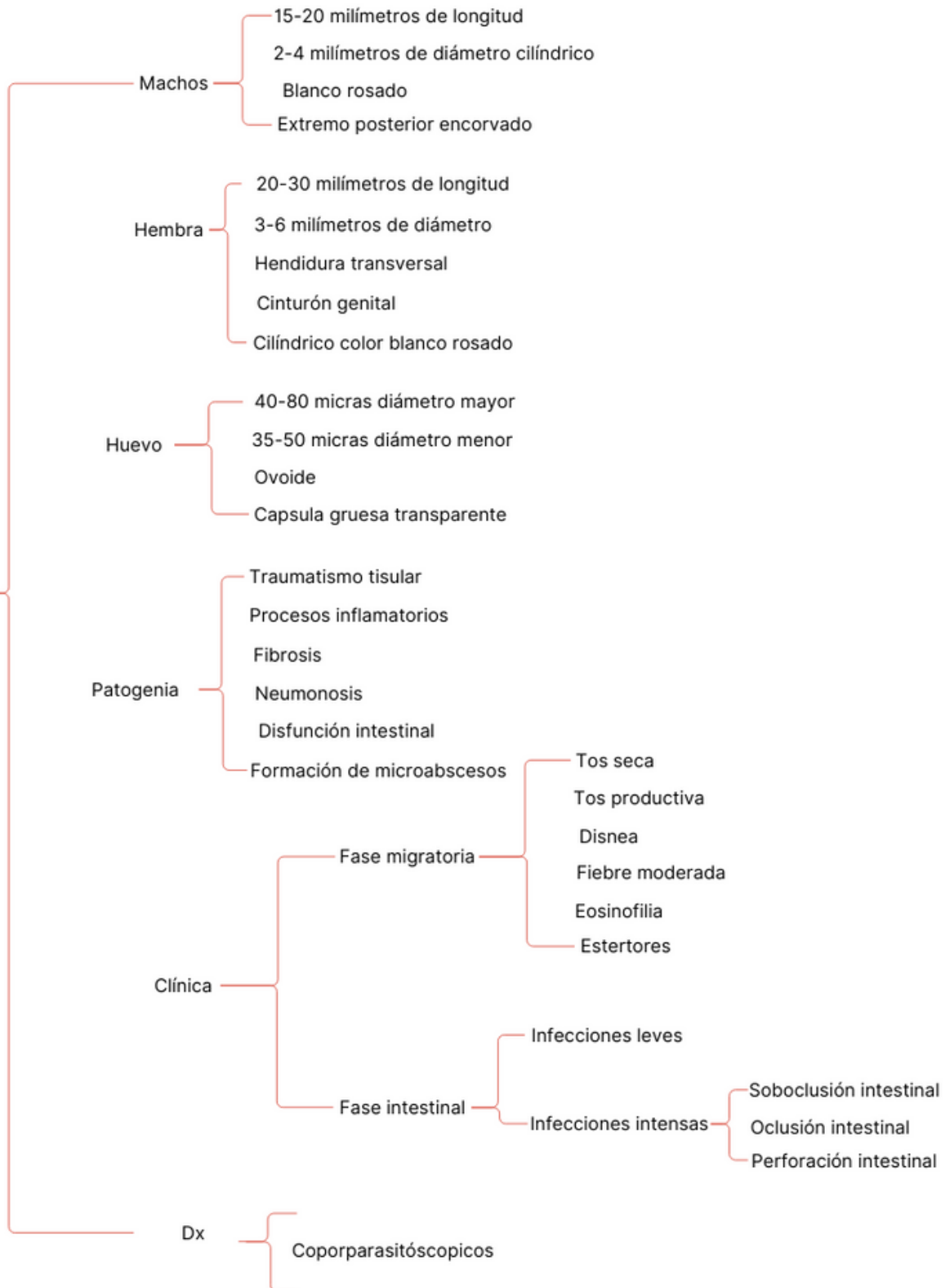
Clínica

- Dolor abdominal
- Diarrea con sangre
- Disentería
- Anemia
- Prolapso rectal
- Apendicitis verminosa

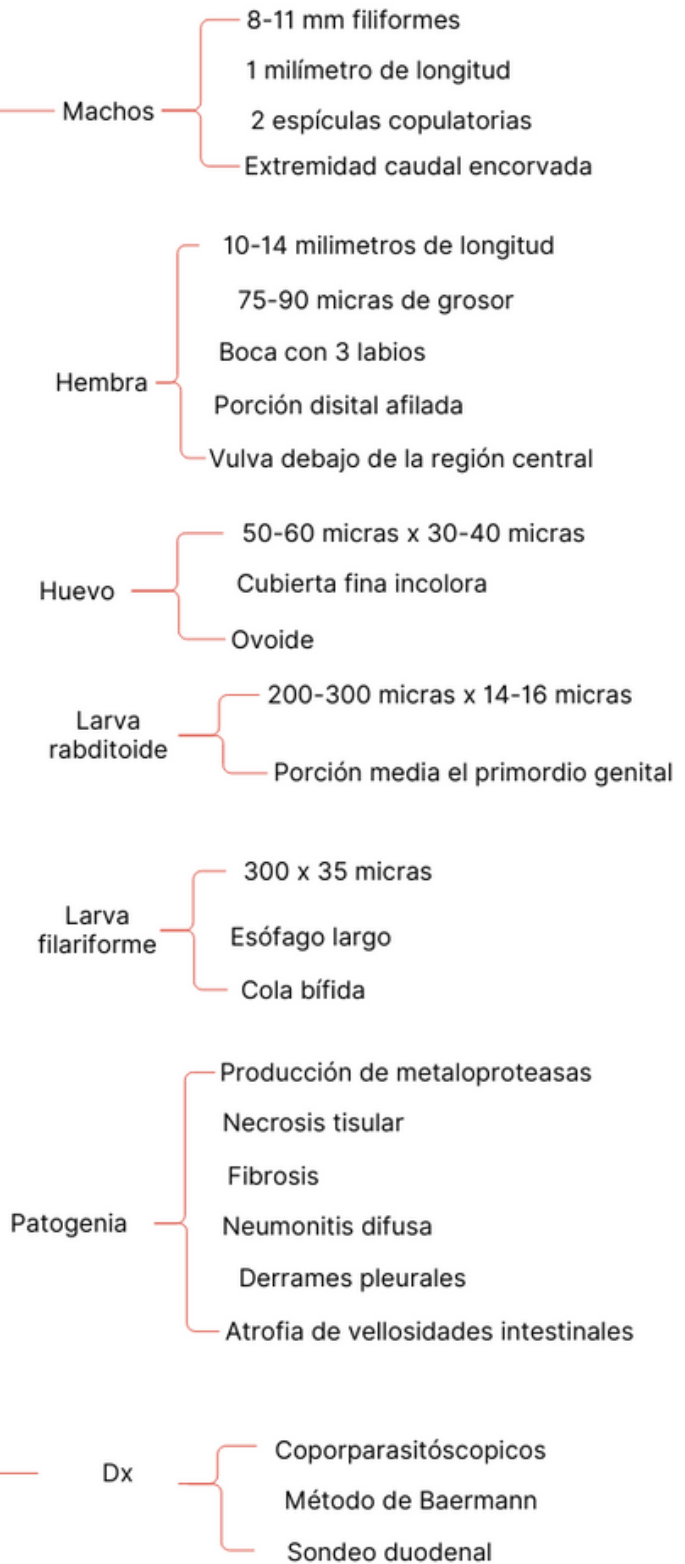
Dx

- Coproparasitoscópicos cuantitativos
- Identificación de huevos

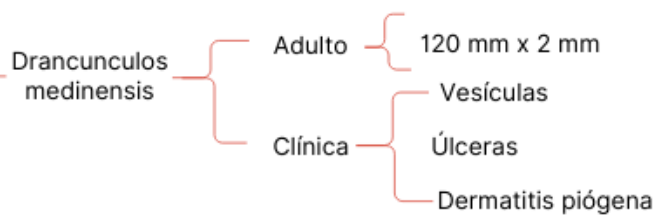
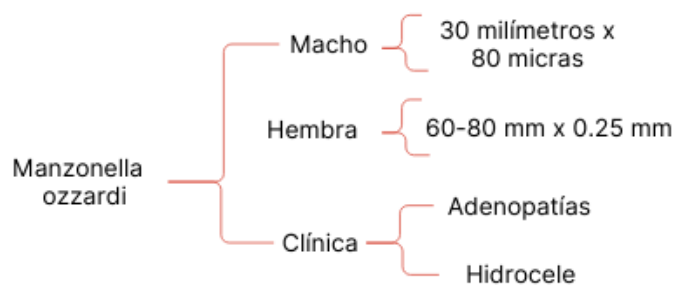
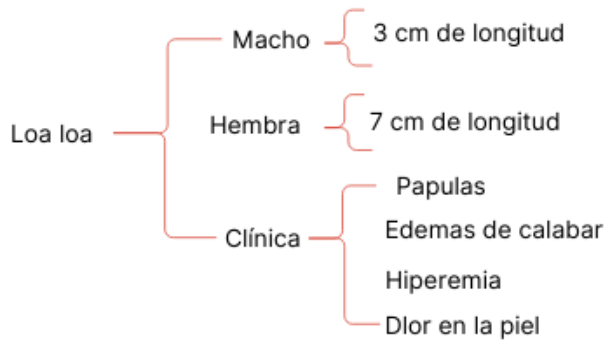
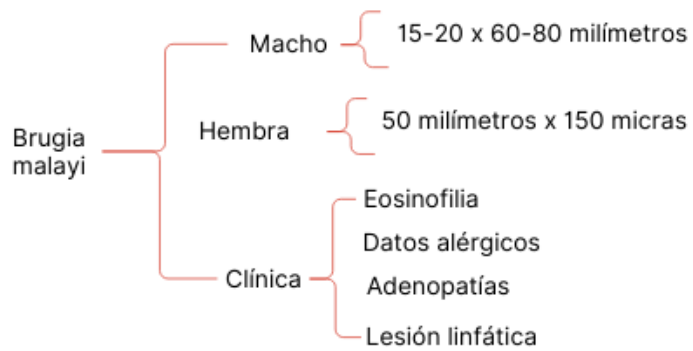
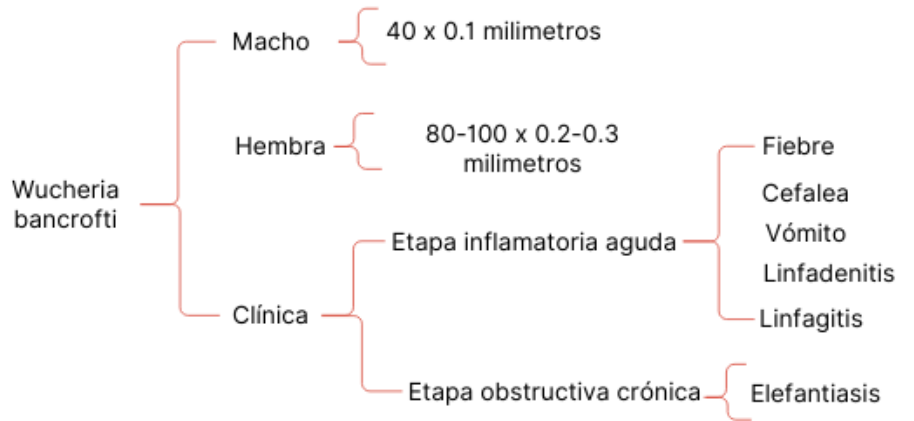
ASCARIS LUMBRICOIDES



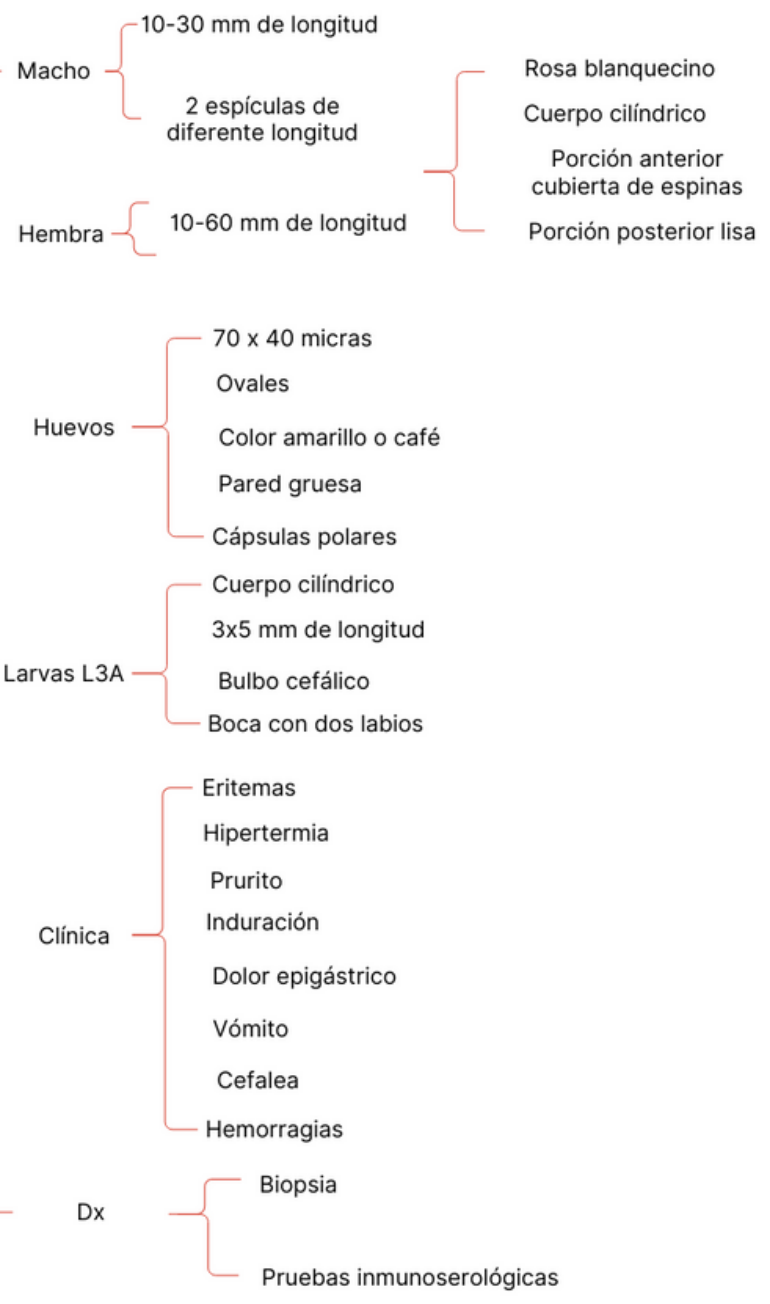
STRONGLYOIDES STERCORALIS



FILIARIAS



GNATHOSTOMA SPINIGERUM



BIBLIOGRAFÍA

Cabello. R (2018) Microbiología y parasitología Humana 4ta edición Ciudad de México. Editorial Médica Panamericana