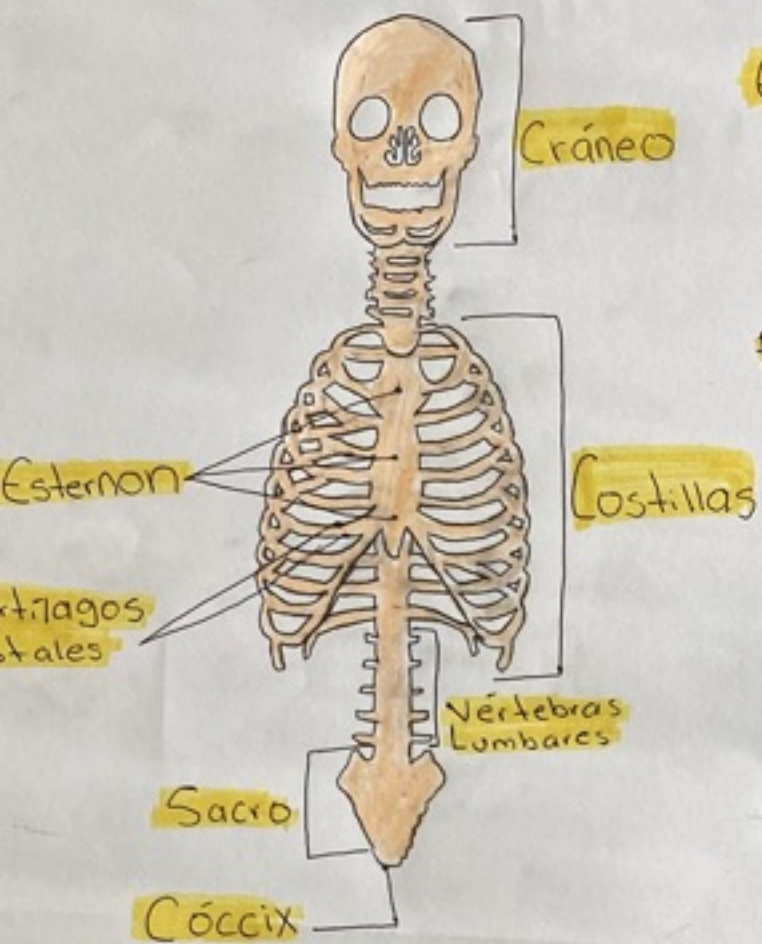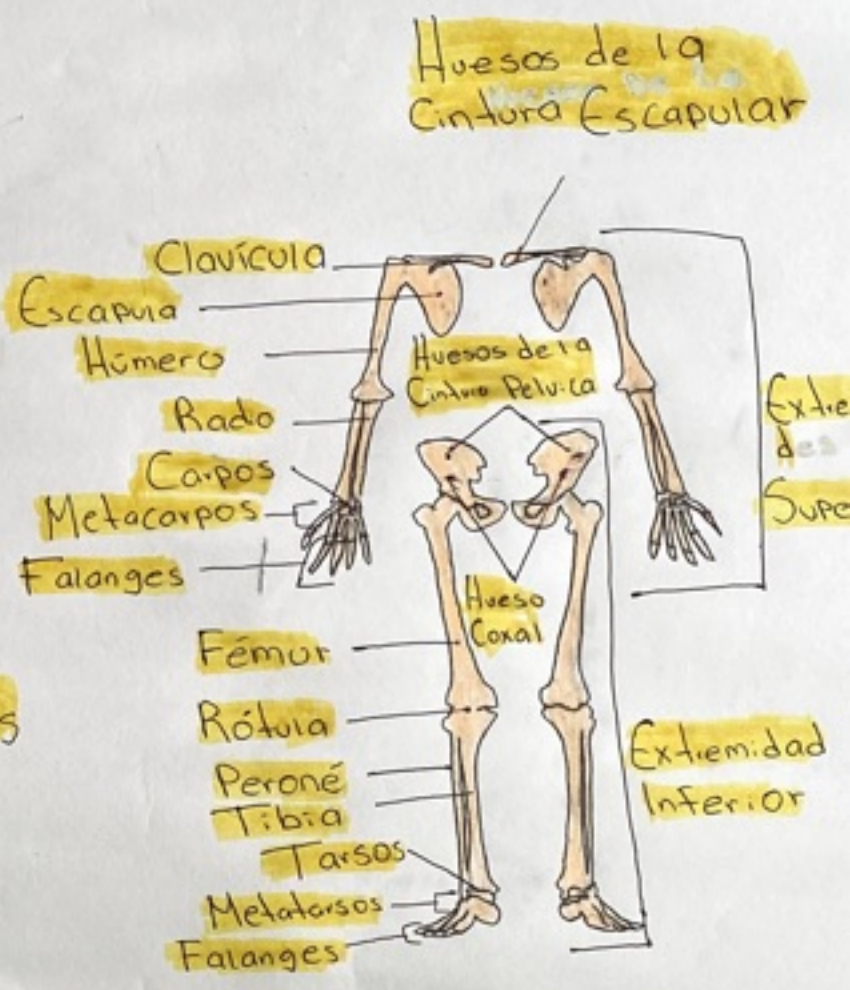


Esqueleto Axial



Esqueleto Apendicular