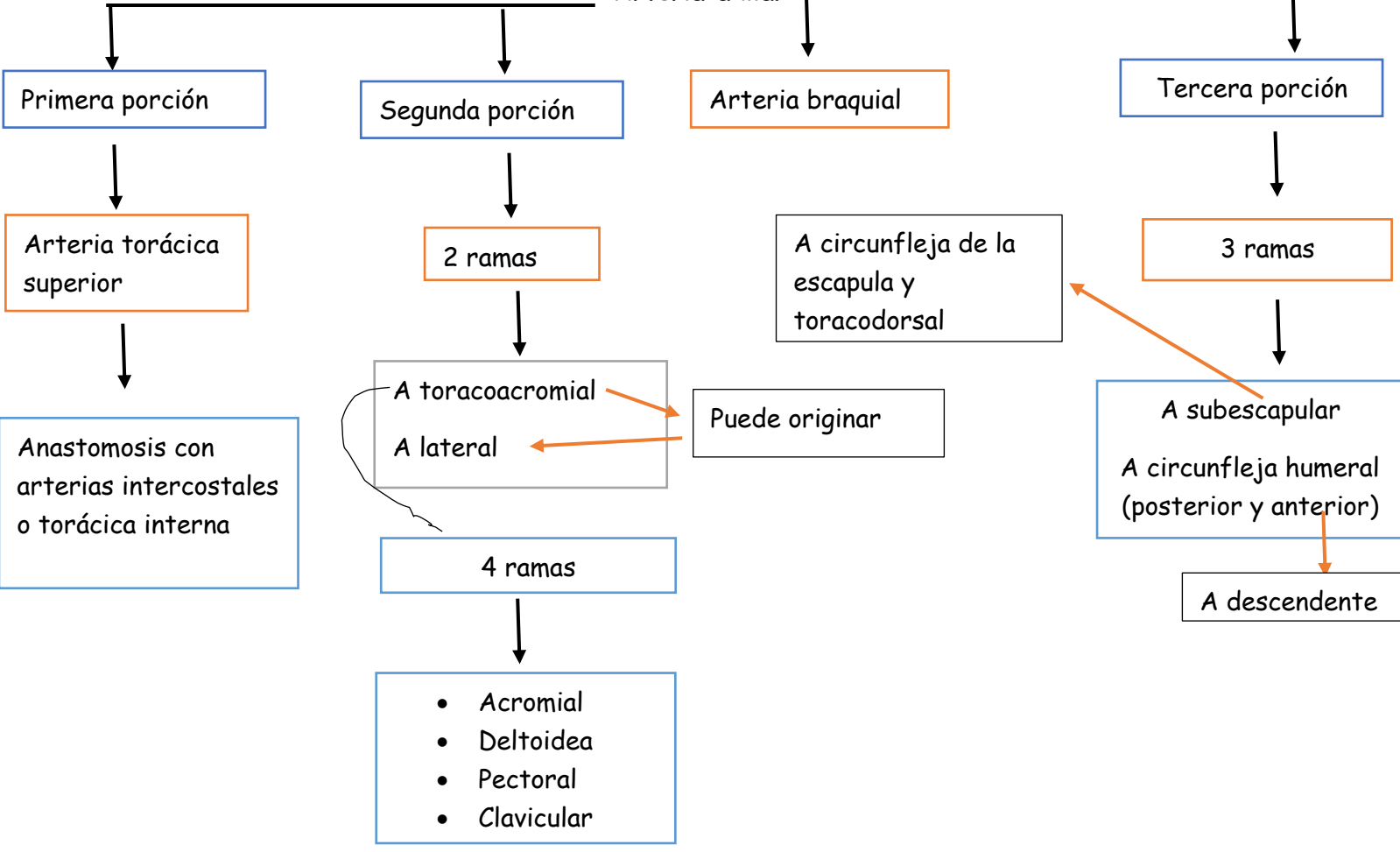


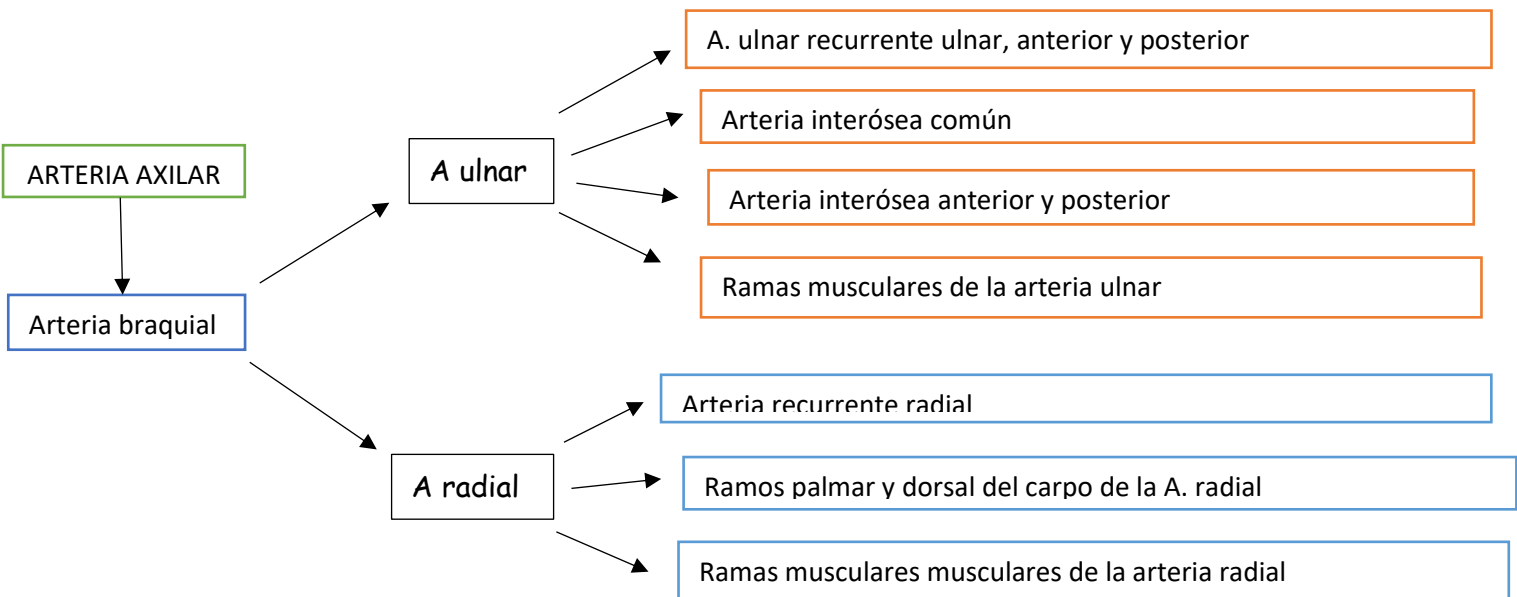
AXILAR

Arteria subclavia

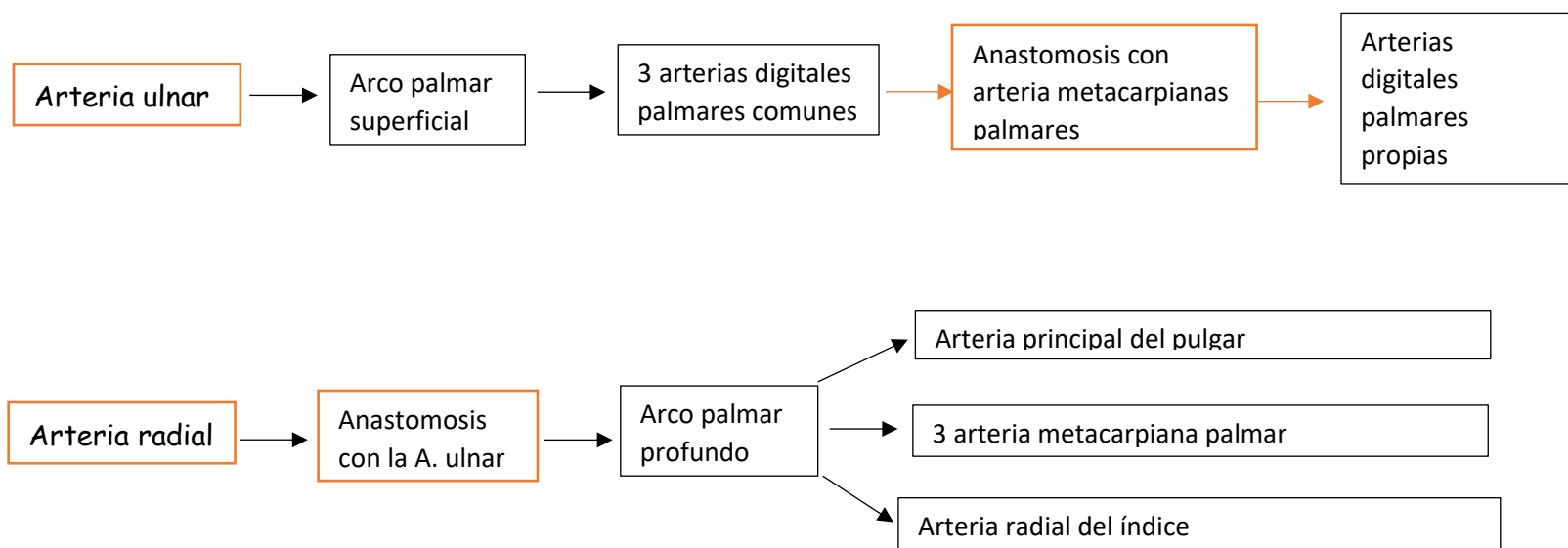
Arteria axilar



ARTERIA ANTEBRAZO



MANO



BRAZO

ARTERIA AXILAR

ARTERIA BRAQUIAL

Arteria nutricia del humero

Profunda

Arteria braquial profunda
Arterias colaterales ulnar superior e inferior

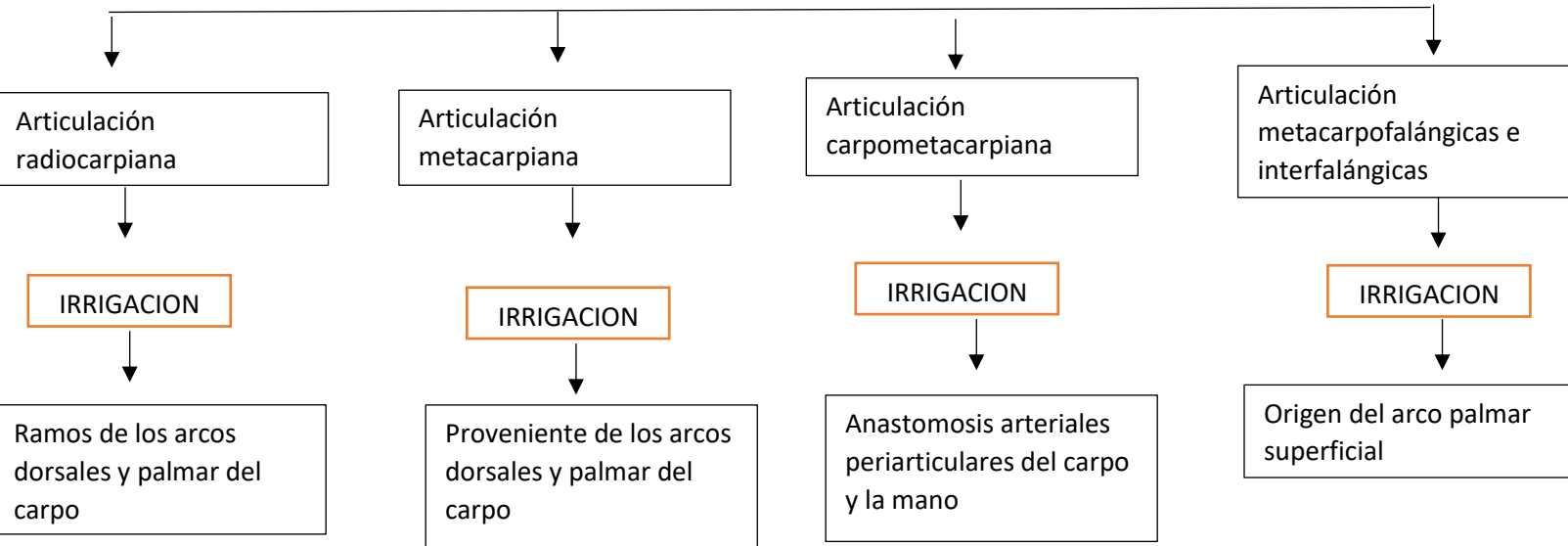
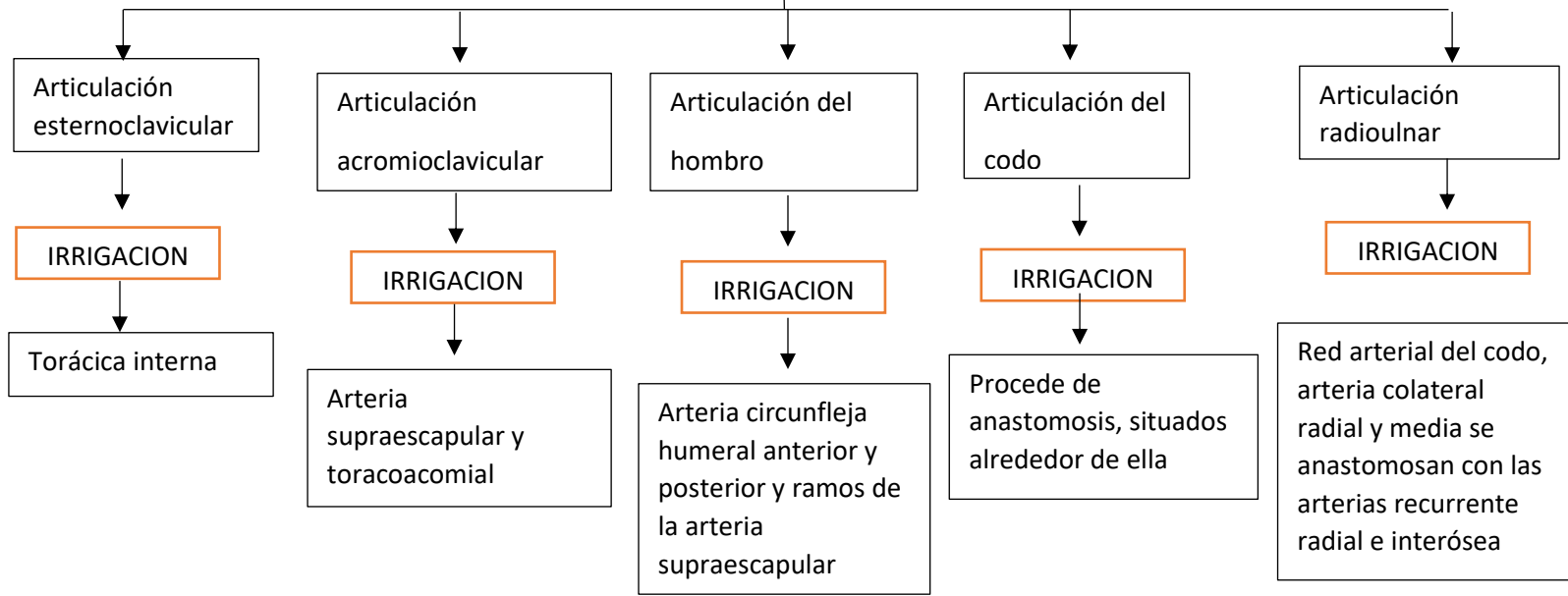
Arteria colateral media y radial

Anastomosis con arteria recurrente ulnar inferior y participa en la anastomosis arterial periarticulares del codo

Arteria radial
Arteria ulnar interósea

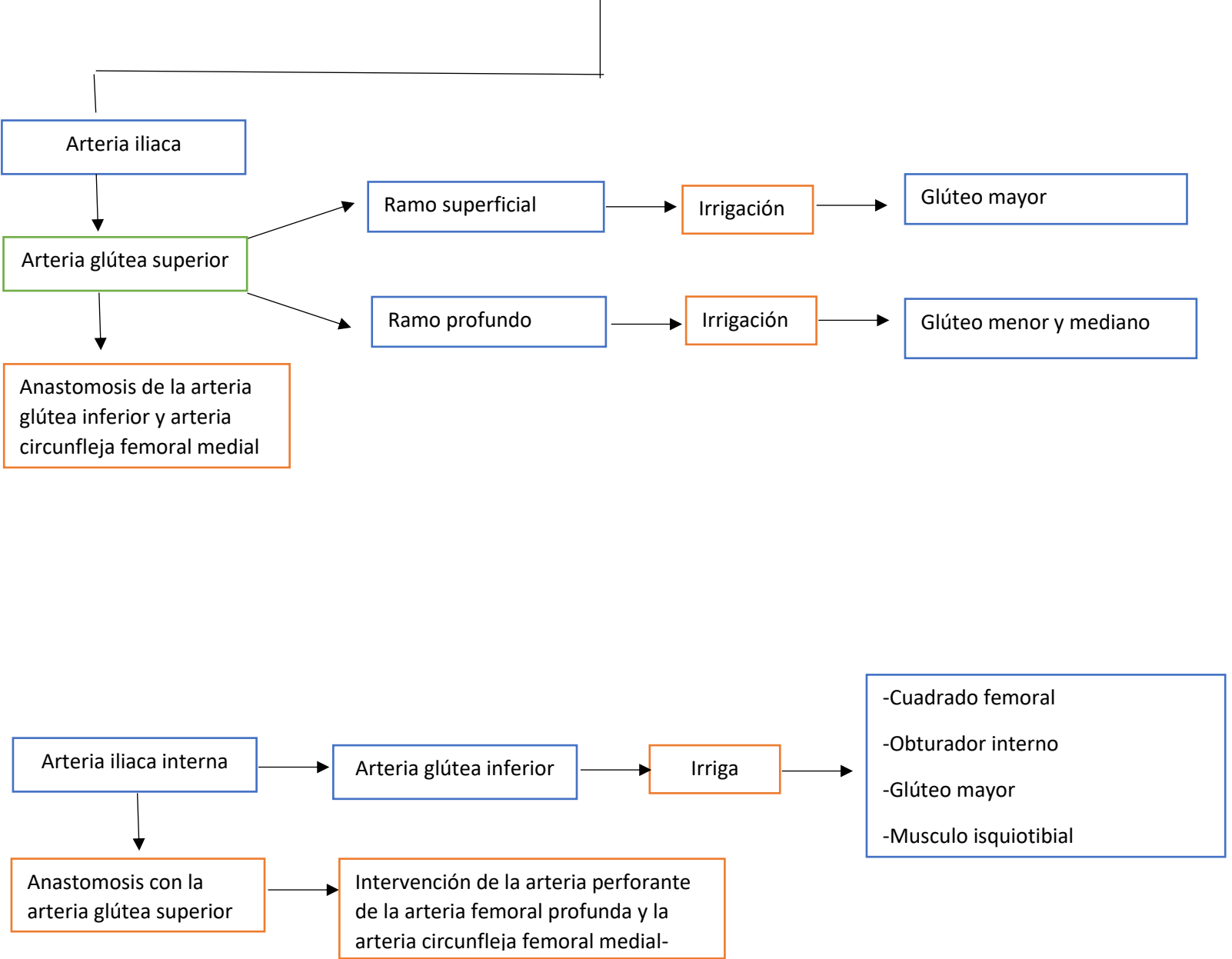
Anastomosis con la arteria recurrente ulnar anterior, participa en la anastomosis arterial periarticular del codo

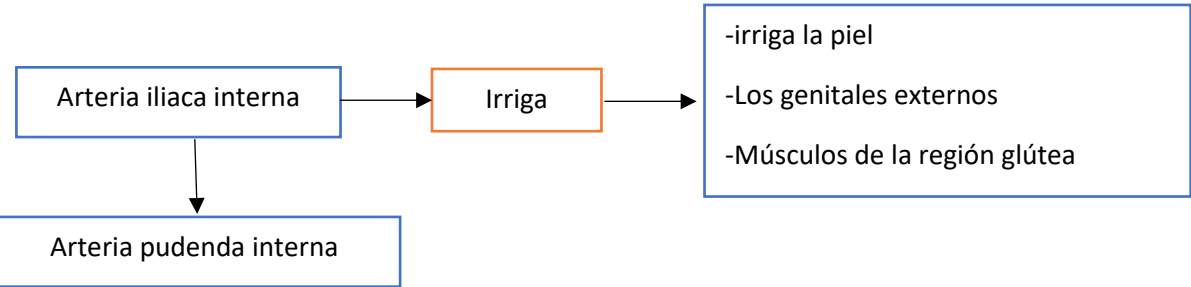
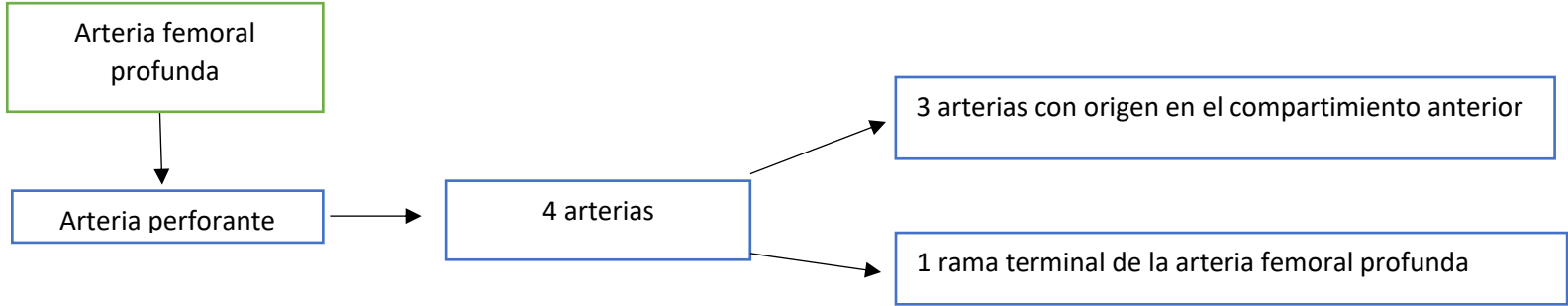
MOVIMIENTOS E IRRIGACION



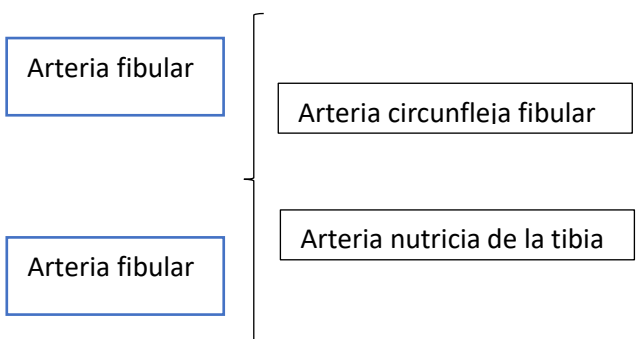
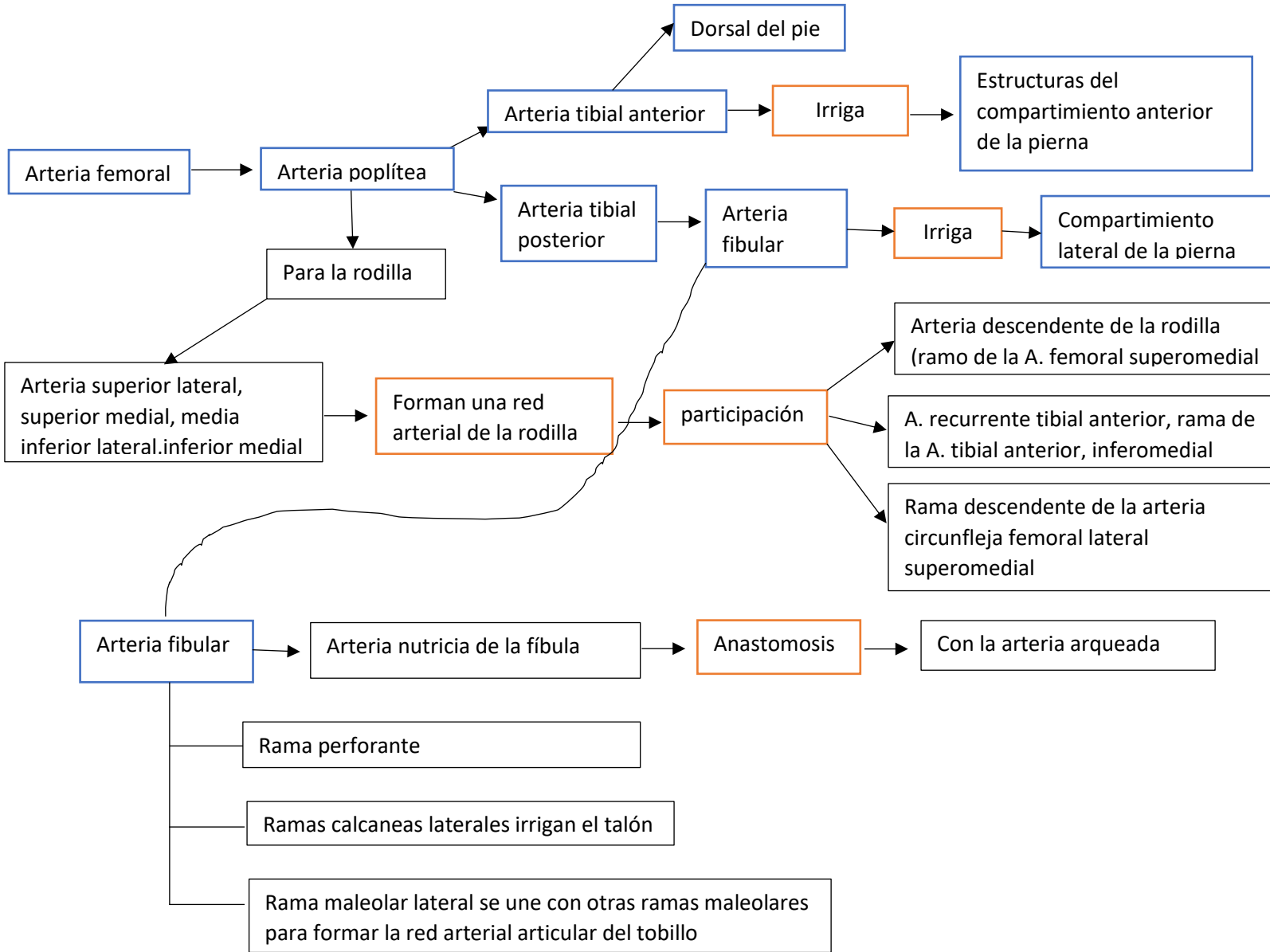
MIEMBRO INFERIOR

REGION GLUTEA Y POSTERIOR DEL MUSLO

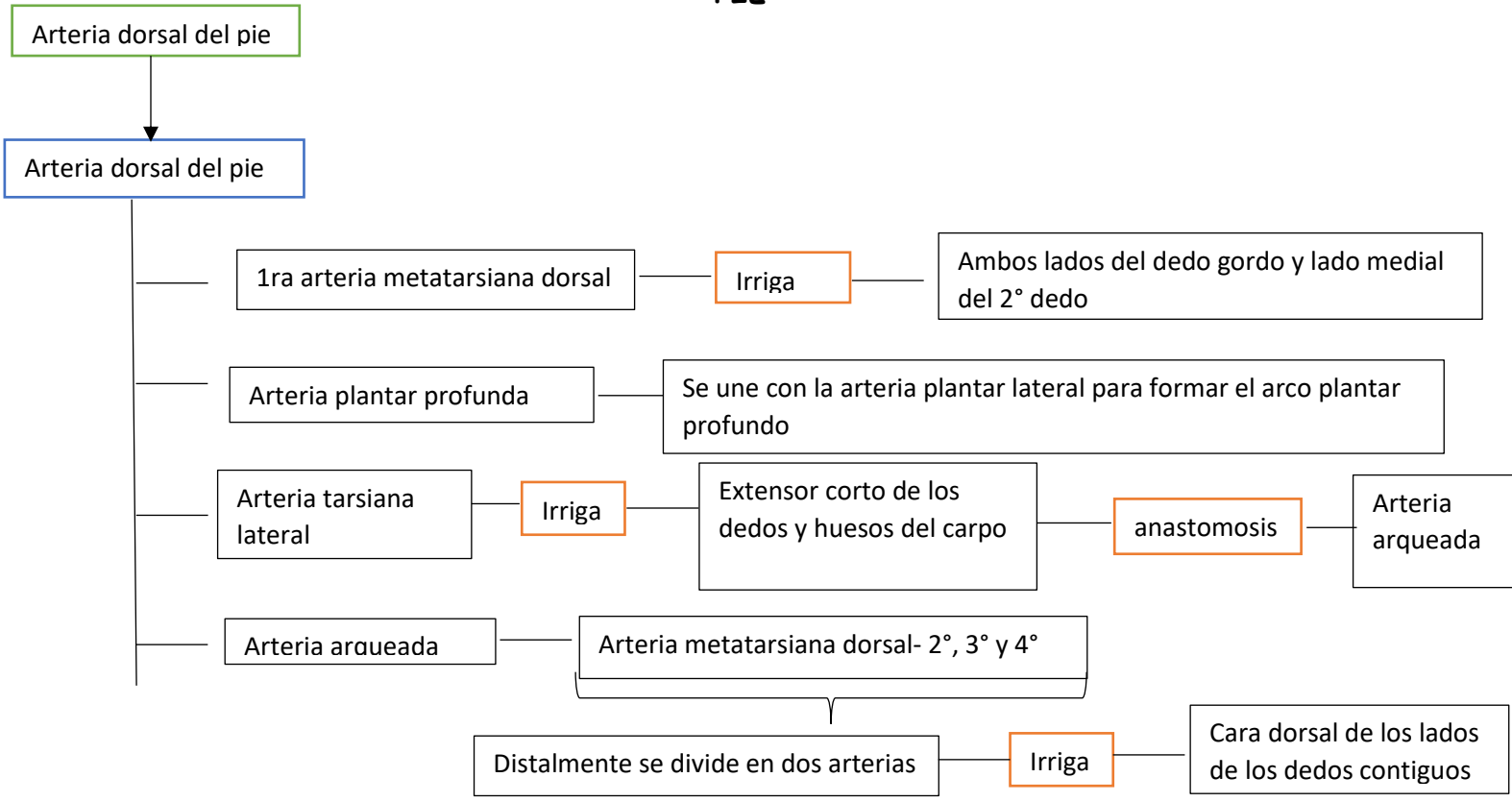




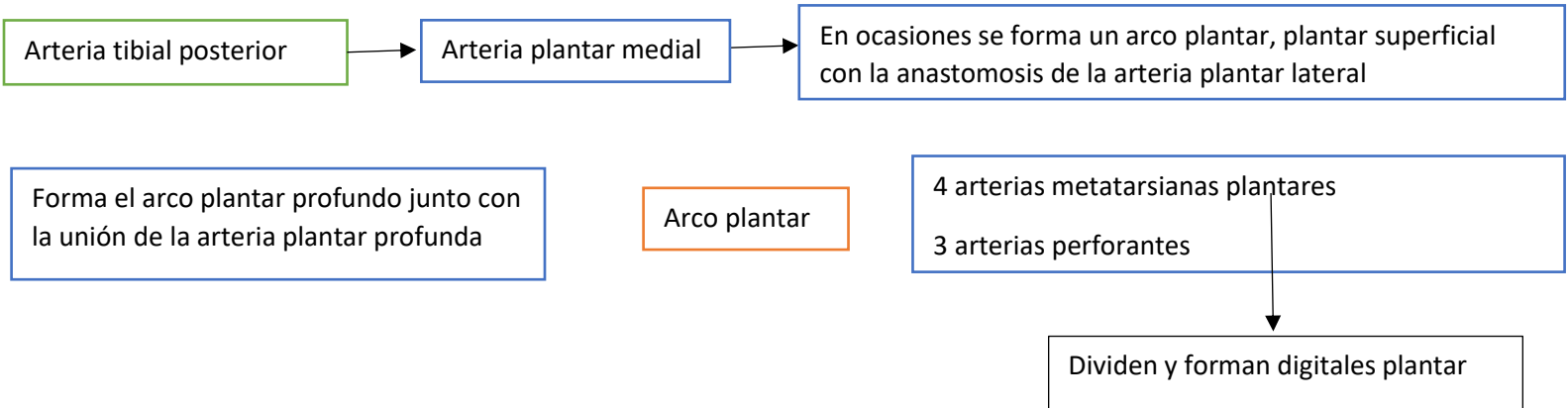
ARTERIAS DE LA PIERNA



PIE



PLANTA DEL PIE



MOVIMIENTOS E IRRIGACION

