



Julián Santiago Lopez

Dr. Romeo Suarez Martínez

**Diagrama de Taquiarritmias y
Bradiarritmias**

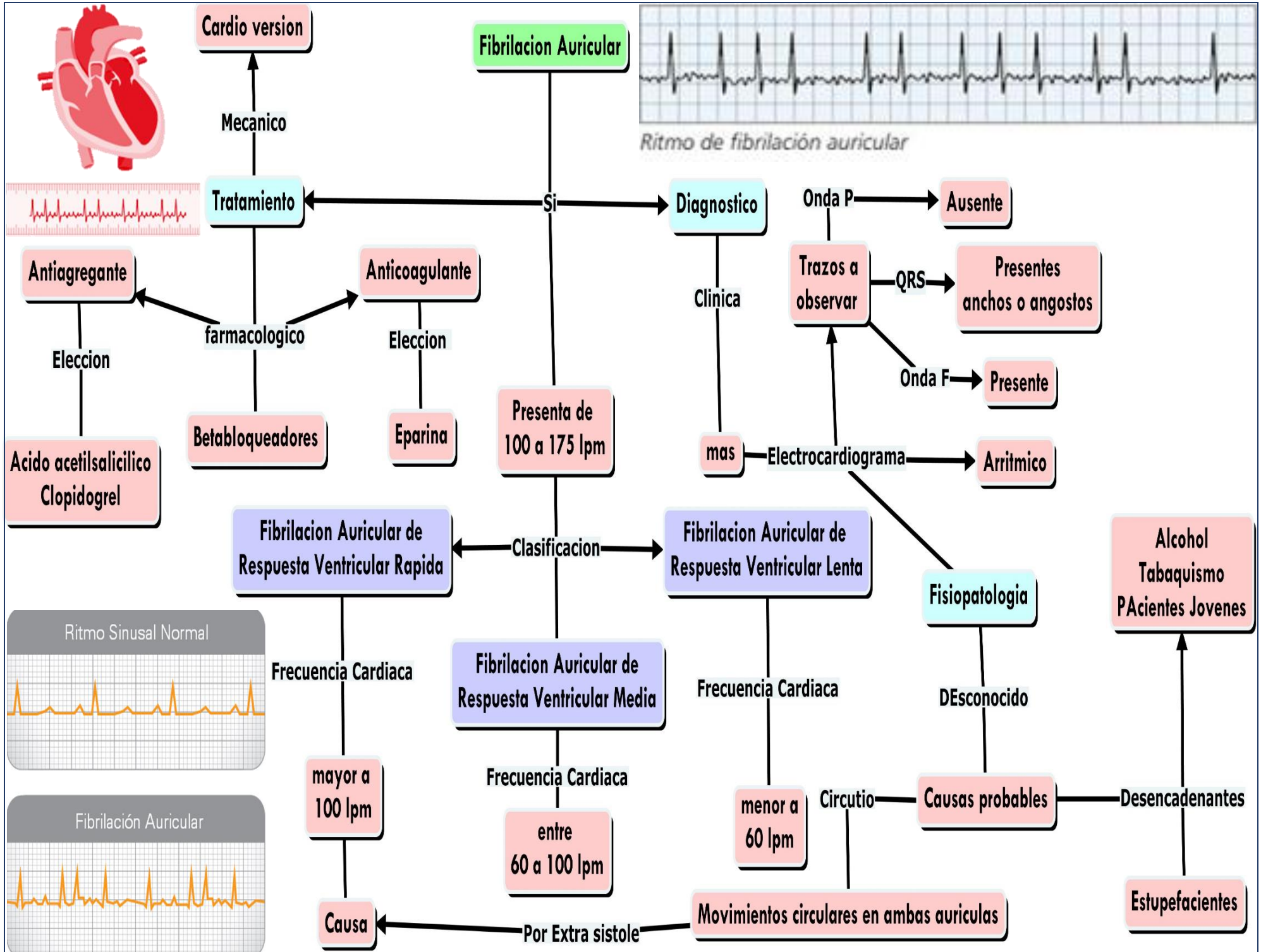
Cardiología

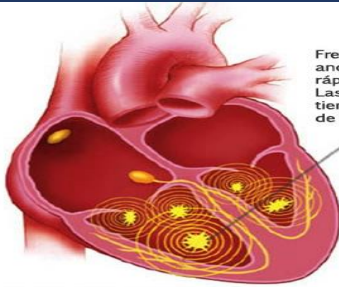
PASIÓN POR EDUCAR

Grado: Quinto Semestre Grupo "B"

**Facultad de Medicina Campus
Comitán**

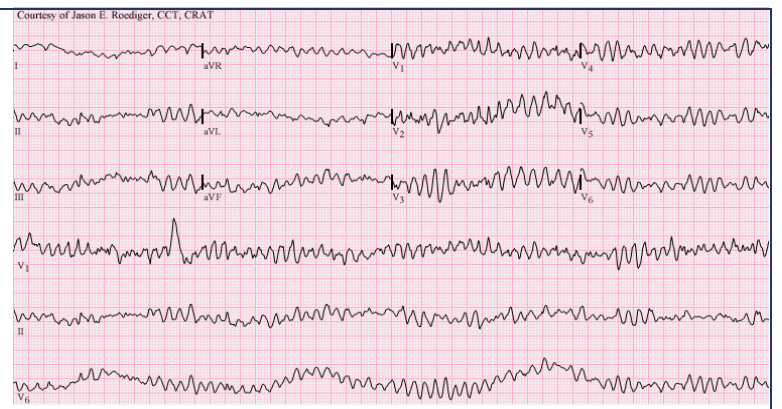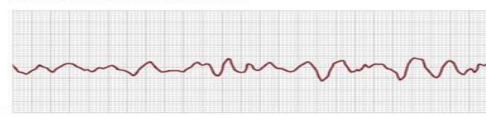
Comitán de Domínguez Chiapas a 16 de septiembre del 2022



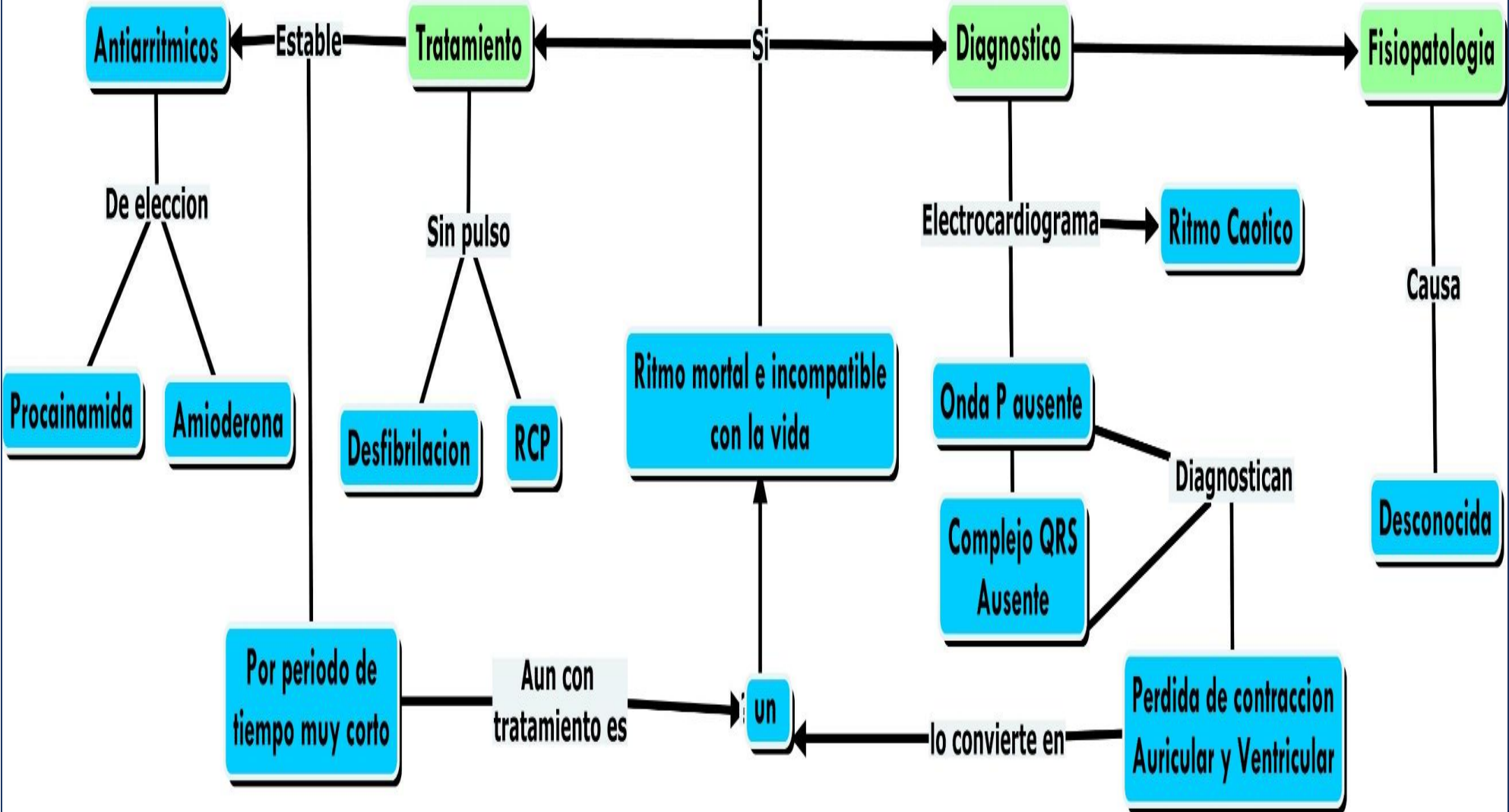


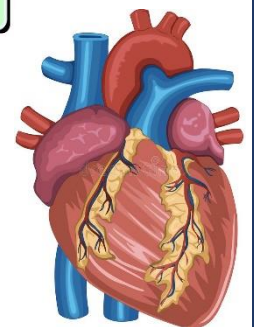
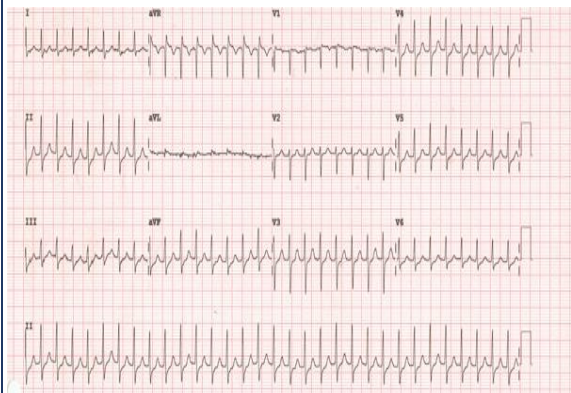
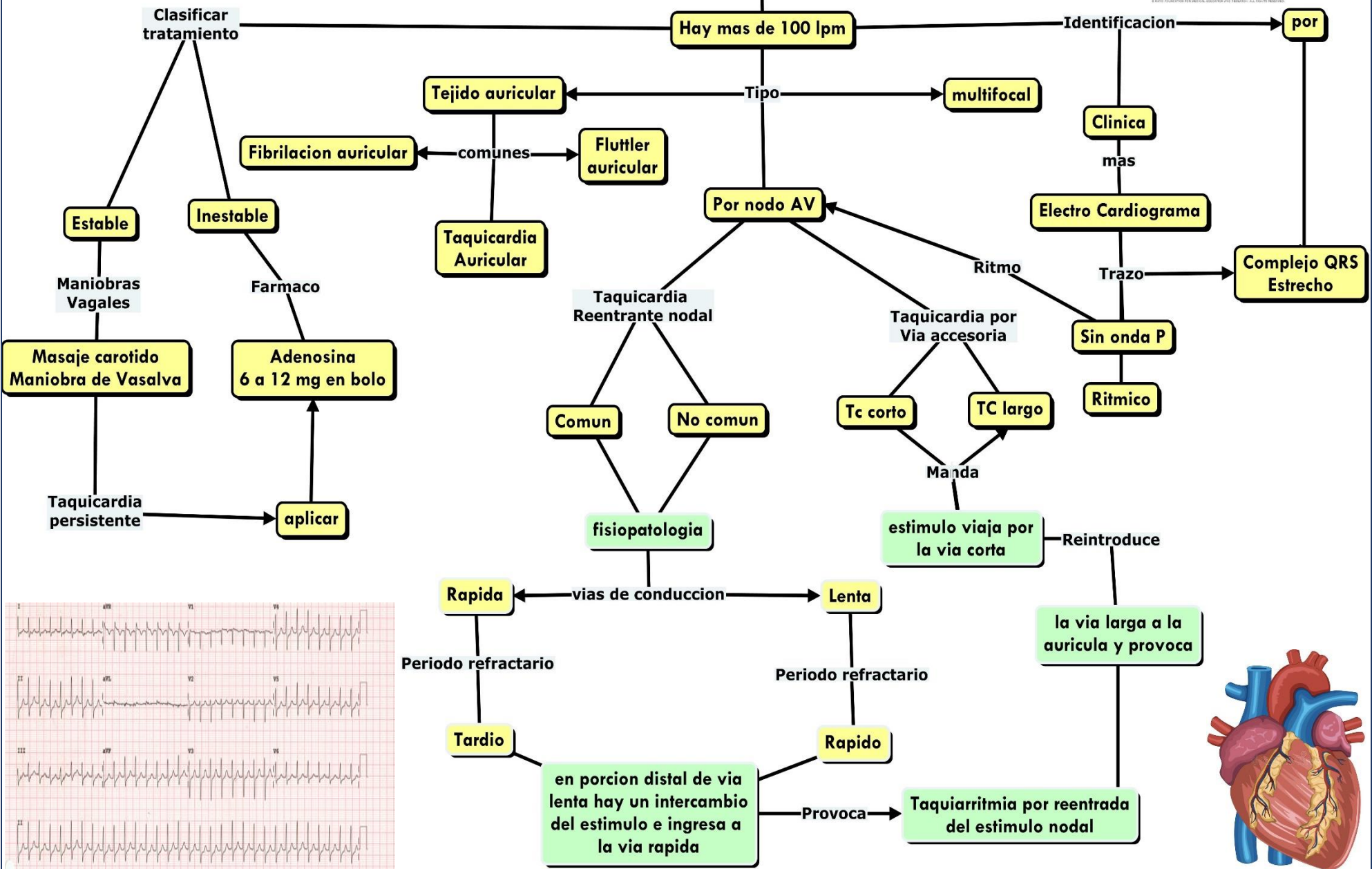
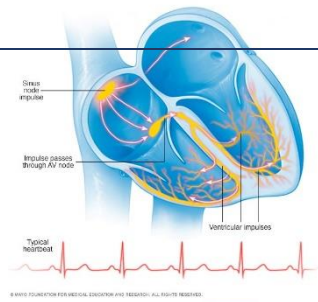
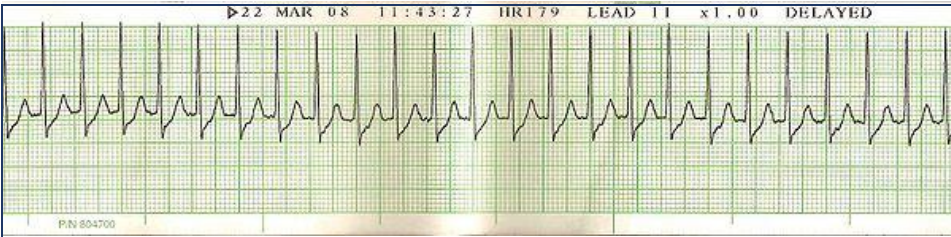
Frecuencia cardíaca anormalmente rápida y caótica; Las aurículas tiemblan en vez de latir.

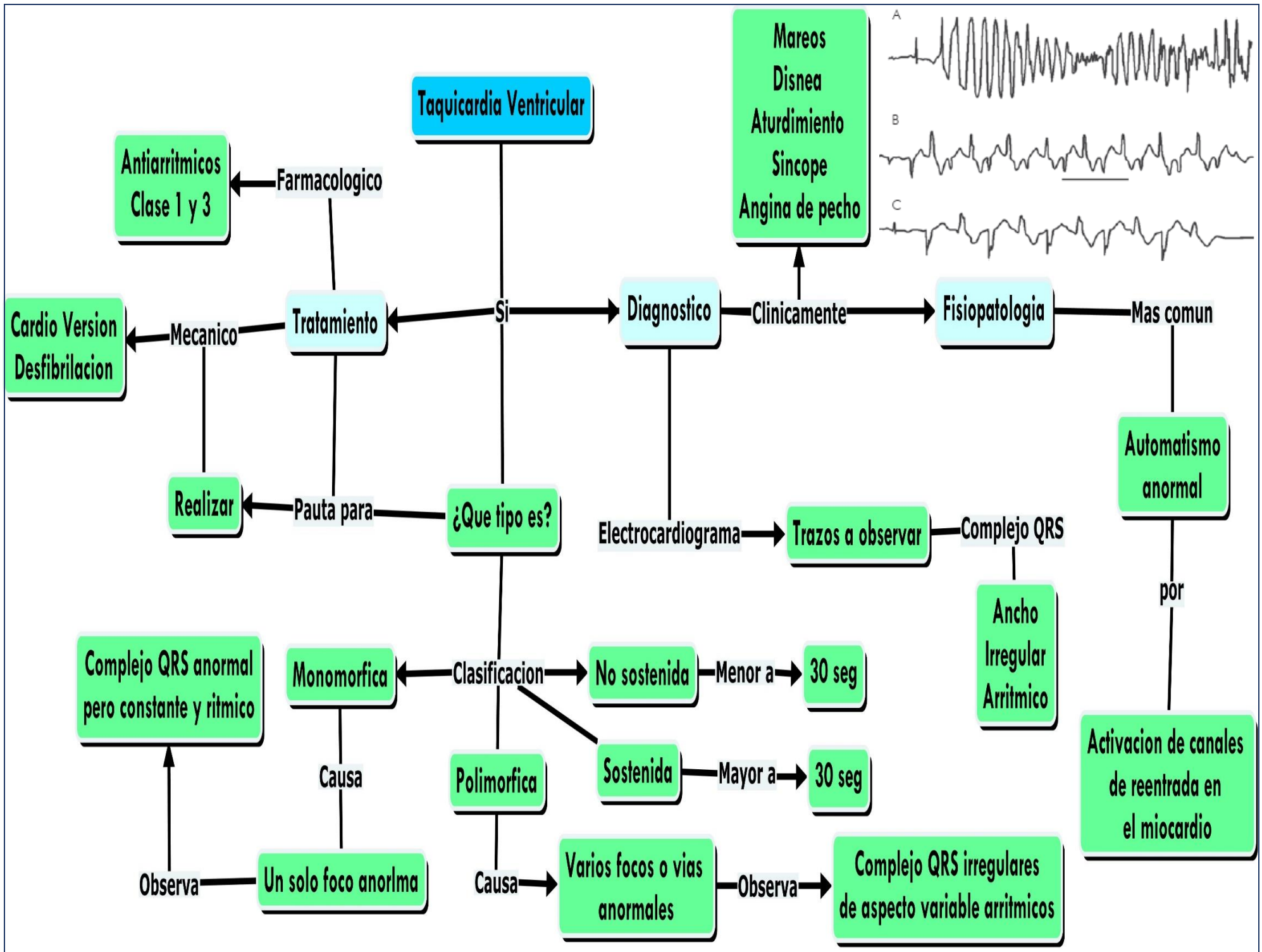
Fibrilación ventricular ECG

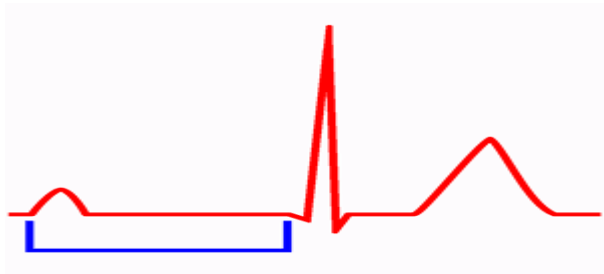


Fibrilación Ventricular

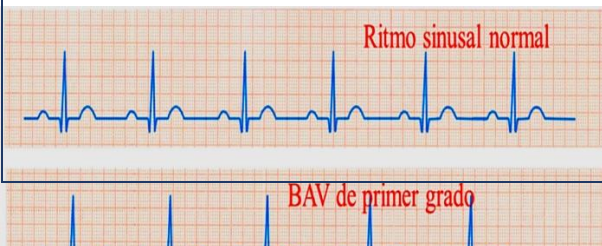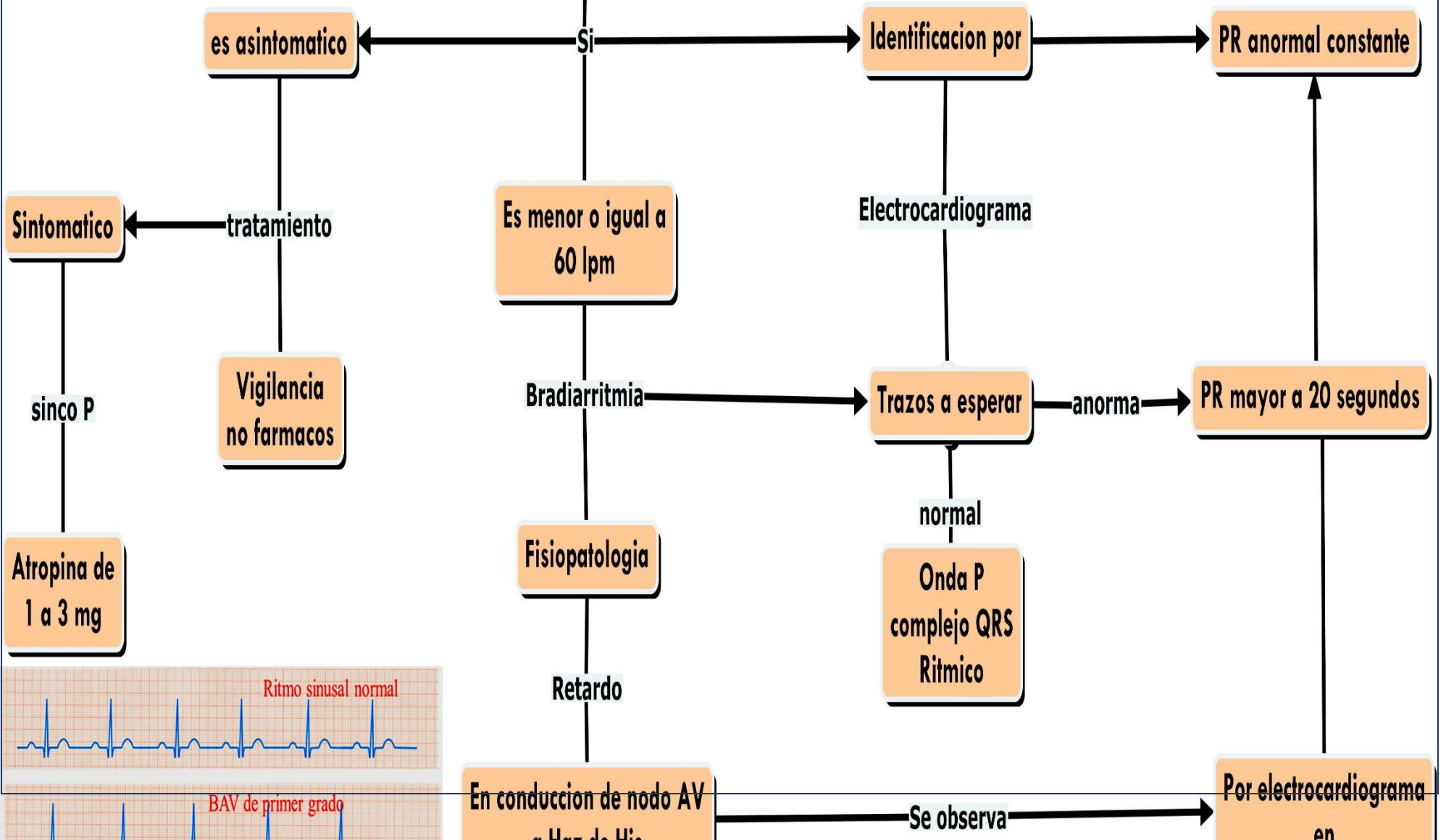
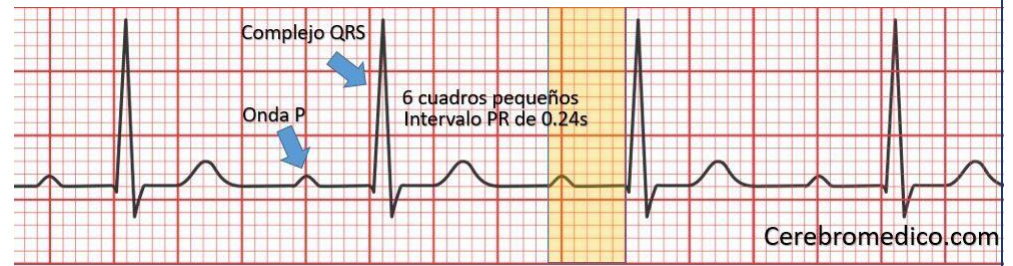




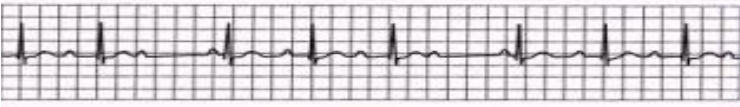




Bloqueo AV de Primer Grado

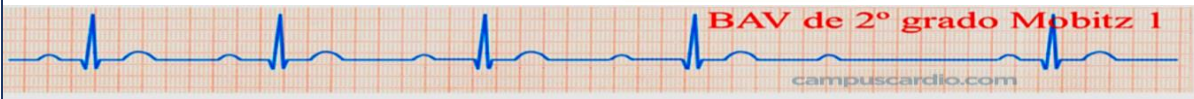
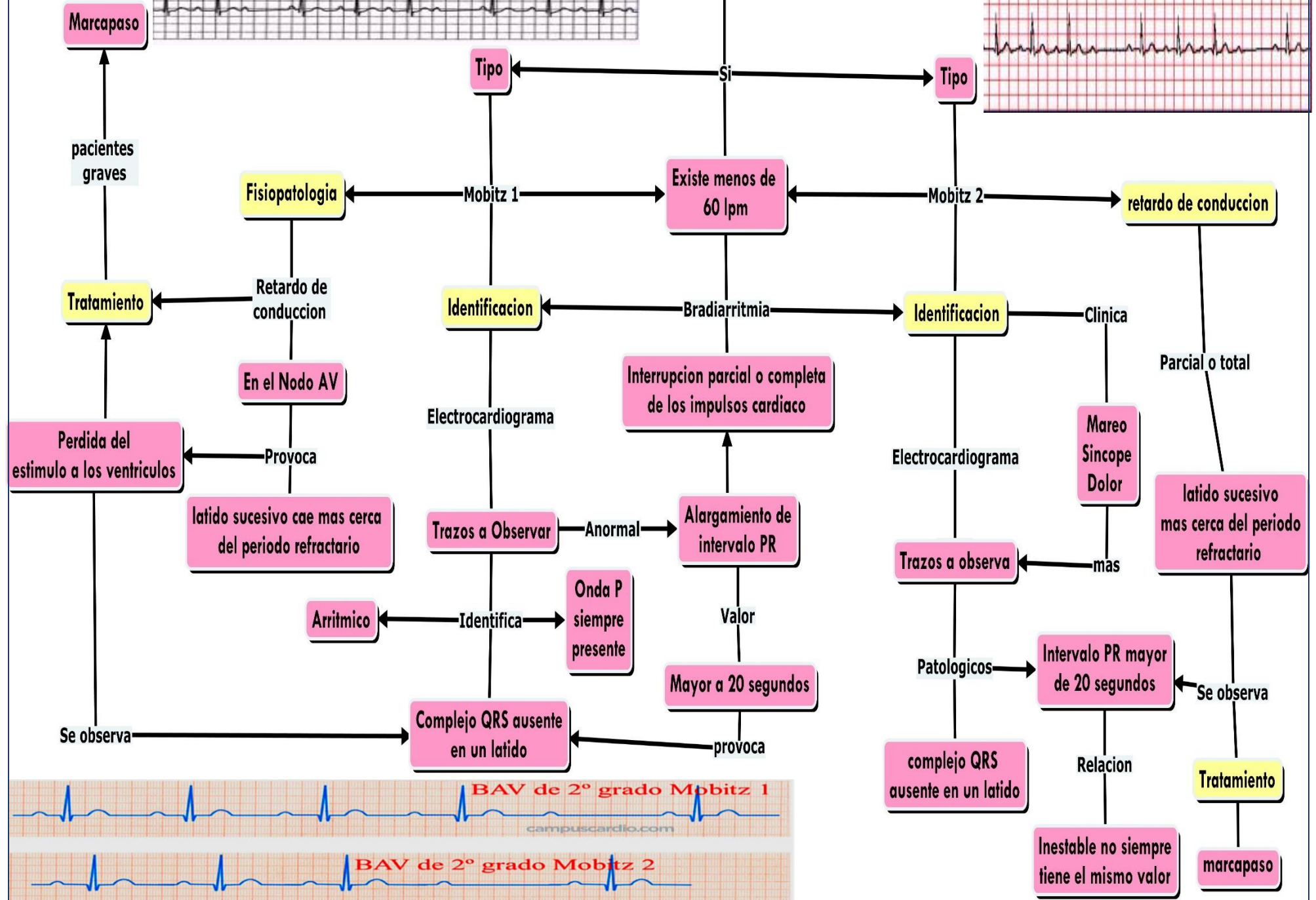
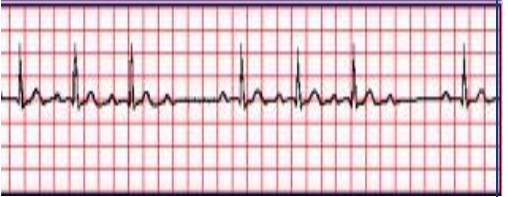

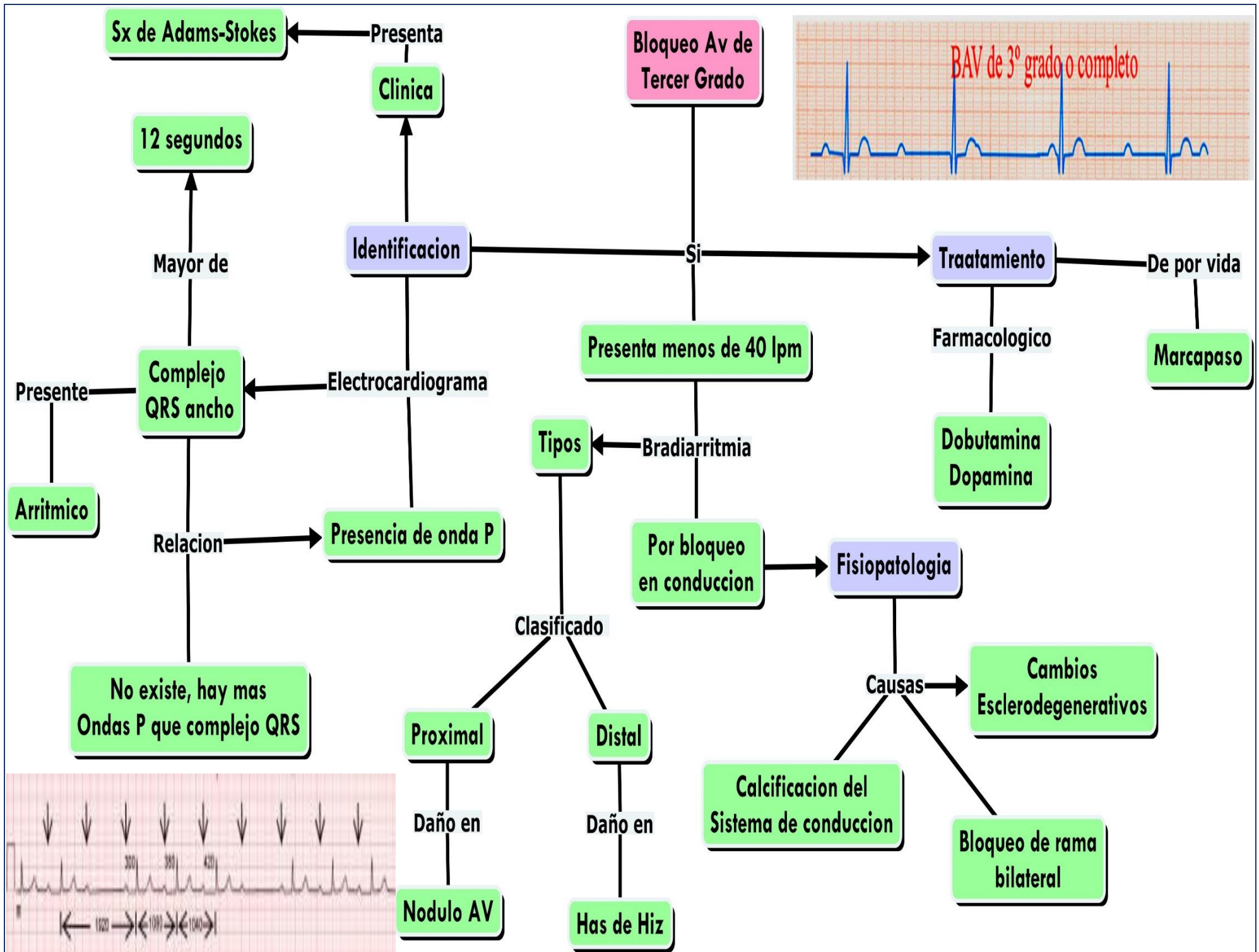
Bloqueo AV 2º grado (PR > 0,20 s) Mobitz 1 (Wenckebach):
 -Prolongación progresiva de PR.
 -Finalmente, QRS ausente luego de Onda P



Bloqueo AV de Segundo Grado

Bloqueo AV 2º grado (PR > 0,20 s) Mobitz 2:
 Ocasionalmente no hay QRS luego de la onda P.





Referencias

Electrocardiografía y arritmias/ William Uribe Arango

GPC tratamiento para taquicardia supraventricular

William Uribe Arango, M., Mauricio Duque Ramírez, M., & Eduardo Medina Durango, M. (s.f.).
Electrocardiografía y arritmias . Medellín.

Alteraciones electrocardiograficas. (s.f.). 4.

Bloqueo AV de 3er grado . (s.f.). En D. E. Muñoz, Aprenda ECG en un día (págs. 42-43). Jaypee-
Highlights Medical Pulishers Inc.

William Uribe Arango, M. D. (s.f.). Electrocardiografia y arritmias .