



**Mi Universidad**

**Universidad del sureste campus Comitán,  
licenciatura en medicina humana.**

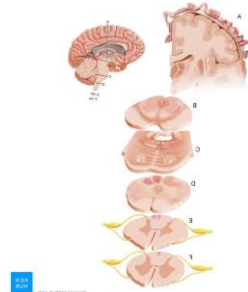
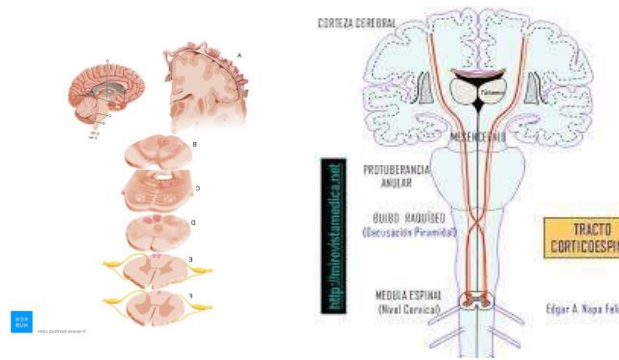
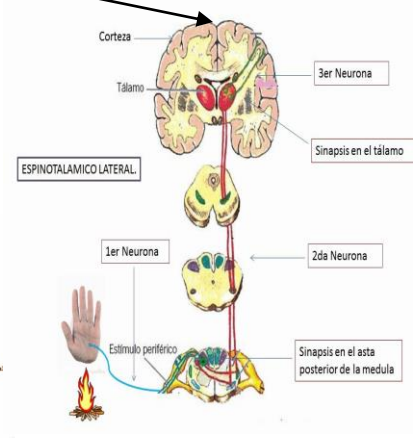
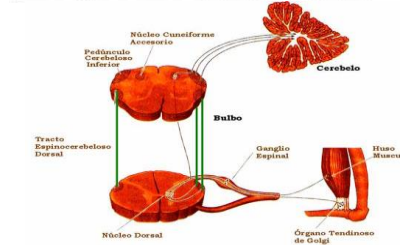
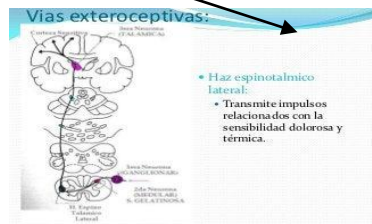
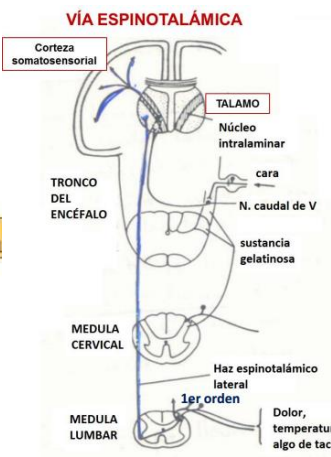
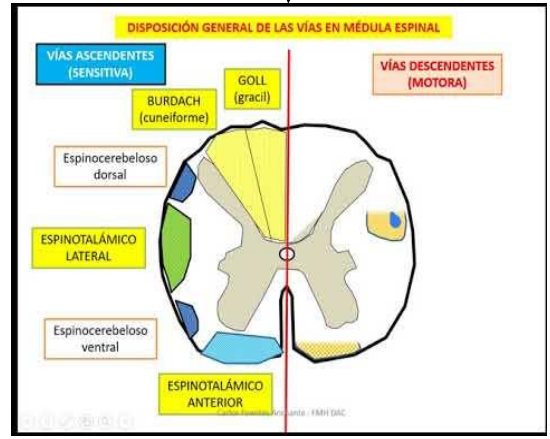
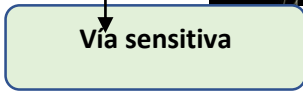
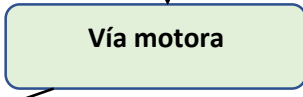
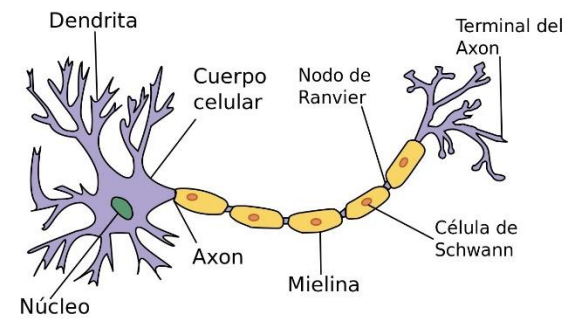
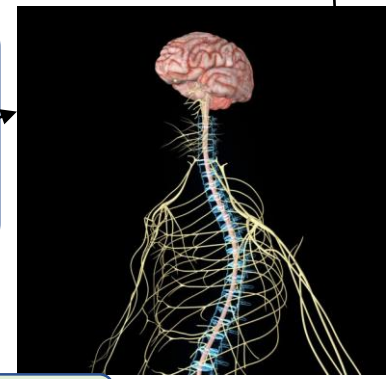
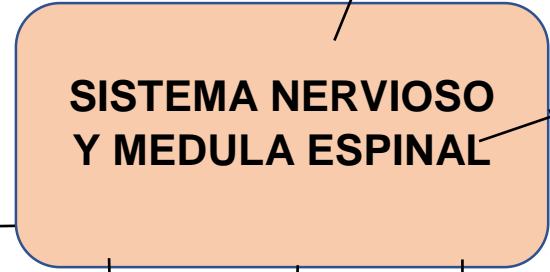
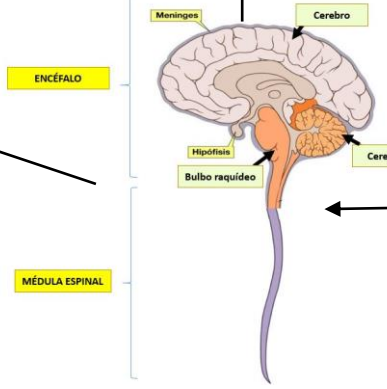
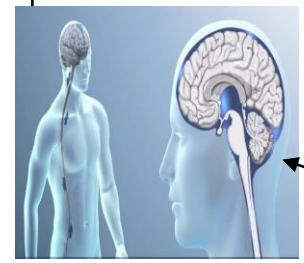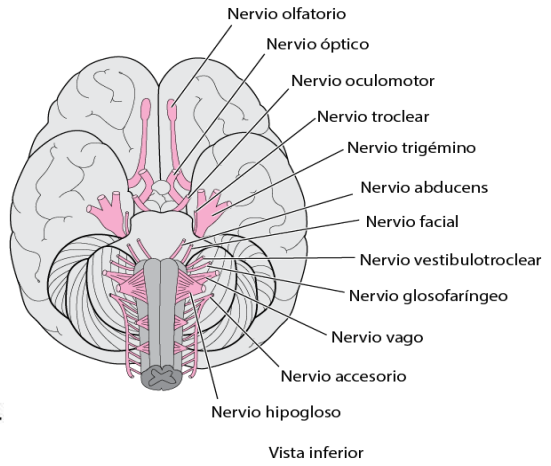
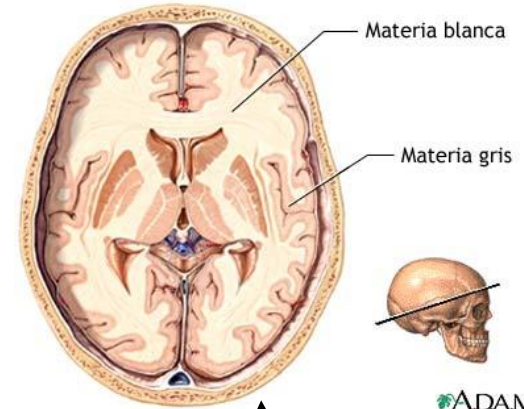
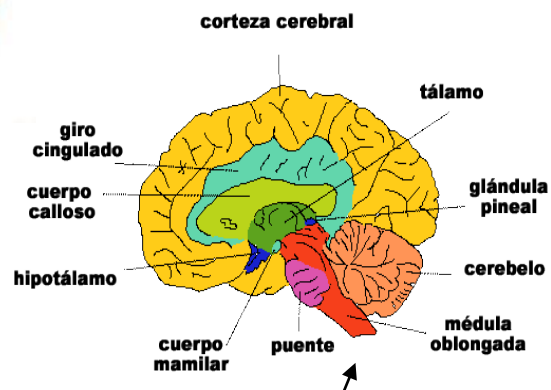
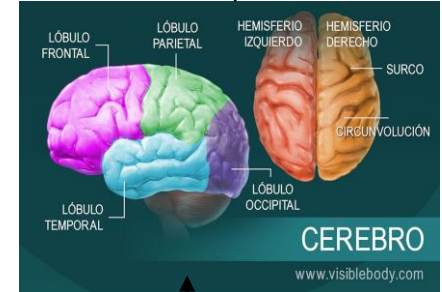
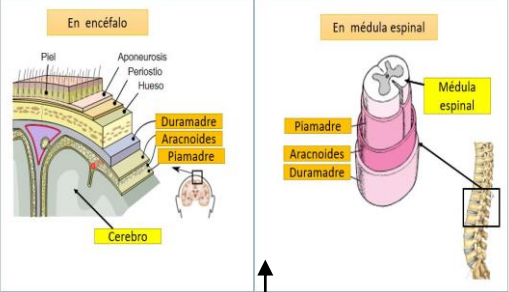
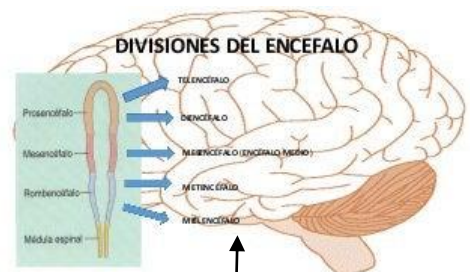
**NOMBRE DEL ALUMNO:** Edman Uriel  
Morales Aguilar

**NOMBRE DEL PROFESOR:** Sergio  
Jiménez Ruiz

**NOMBRE DEL TRABAJO:** Mapa conceptual  
Primer parcial

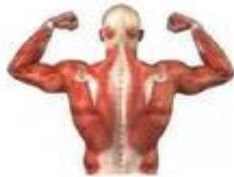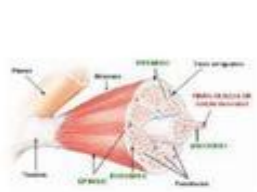
**MATERIA:** Medicina Física y de  
Rehabilitación

**GRADO Y GRUPO:** 5to semestre grupo A



# MUSCULO ESTRIADO

## CARACTERISTICAS



Varios núcleos

Voluntario

Unido a huesos

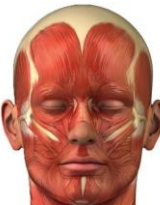

Color rojo oscuro

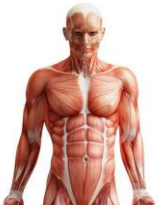## FUNCIONES

Movilización

Protección

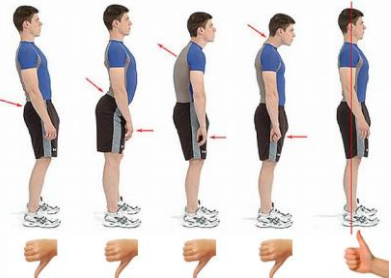


Sostén



Estabilizador de

Mantenimiento de la postura

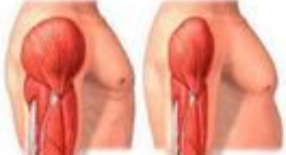

## UNIDAD

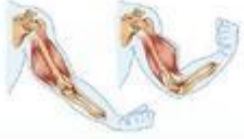Sarcómero

## PROPIEDADES

Tonicidad




Elasticidad

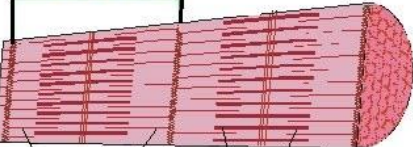

Contractilidad

Excitabilidad

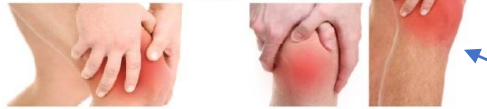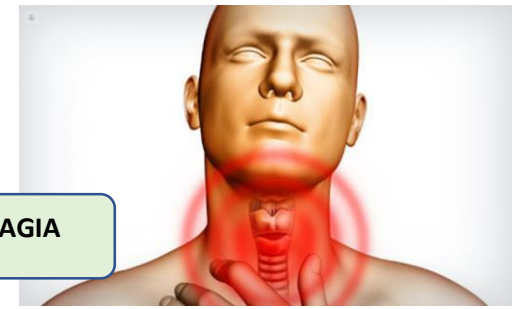

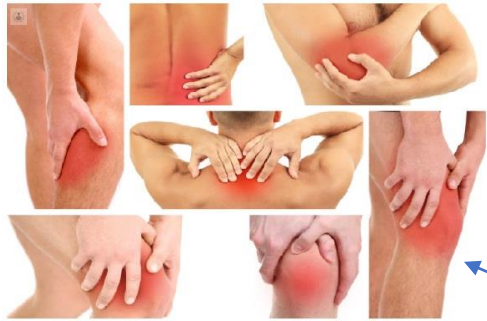
## SARCÓMERO

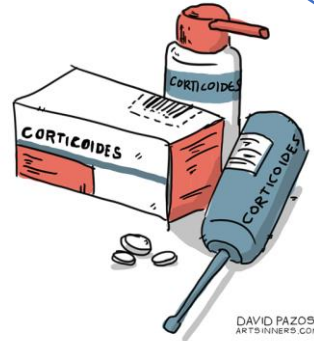

Miofilamentos de actina

Miofilamentos de miosina



FARMACOLOGICO



DAVID PAZOS  
ARTSINNERS.COM

NO FARMACOLOGICO

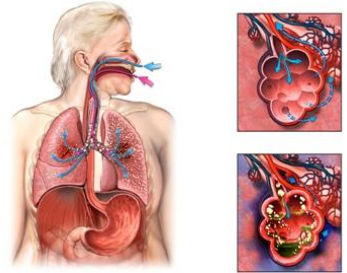


QUE ES

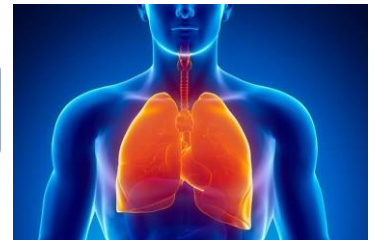A QUIEN AFECTA

COMPLICACIONES

NEUMONIA POR ASPIRACION

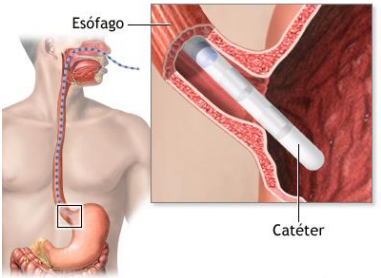
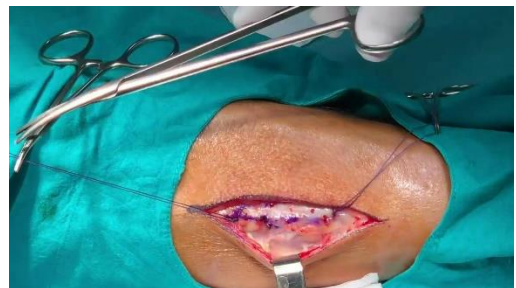
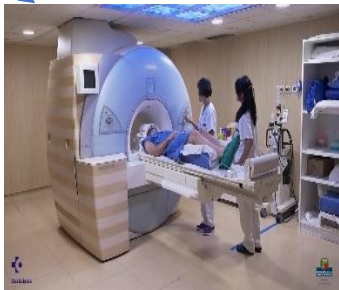
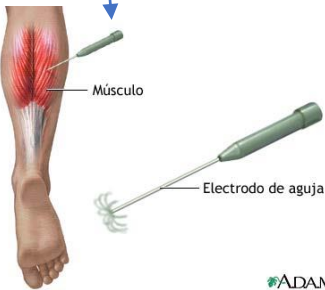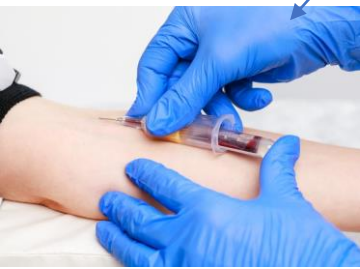PROBLEMAS RESPIRATORIOS



**POLIMIOSITIS**

DIADNOSTICO



ADAM

# BIBLIOGRAFIA

- fundacion española de reumatologia*. (2021). Obtenido de polimiositis: <https://inforeuma.com/wp-content/uploads/2021/07/POLIMIOSITIS.pdf>
- Matamala. (s.f.). *Médula Espinal*. Obtenido de <https://www.med.ufro.cl/neuroanatomia/archivos/pdf/apunte4.pdf>
- Mergler, D. (s.f.). *sistema nervioso* . Obtenido de el cuerpo humano: <https://www.insst.es/documents/94886/161958/Cap%C3%ADtulo+7.+Sistema+nervioso>
- Merino Pérez, J., & Noriega Borge, M. J. (s.f.). *FISIOLOGÍA GENERAL*. Obtenido de <https://ocw.unican.es/pluginfile.php/879/course/section/967/Tema%252010-Bloque%2520II-Fisiologia%2520del%2520Musculo.pdf>