

Neuromielitis óptica

Neurología

Dra. Mónica Rendón Gordillo

Aurora Flor D' Luna Dguez Mtz

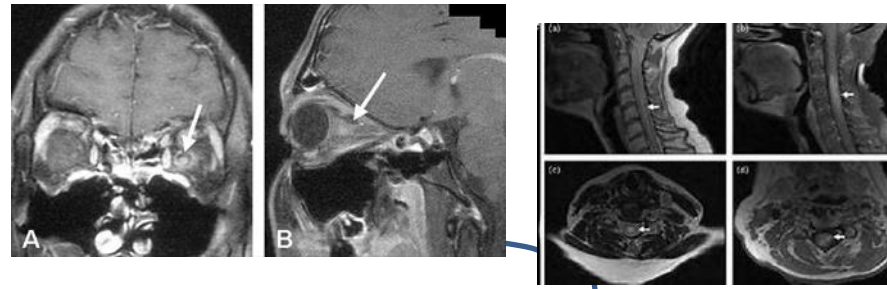
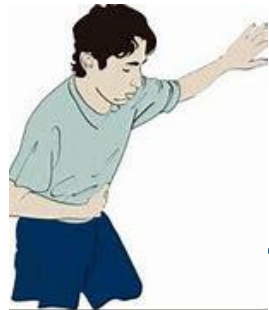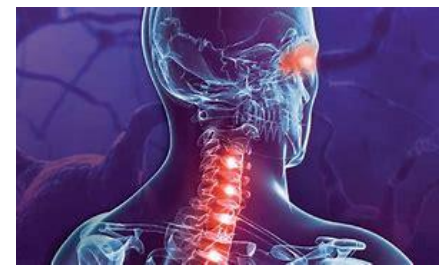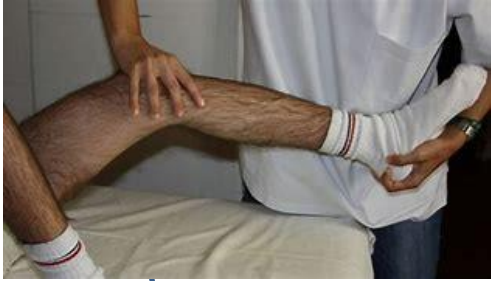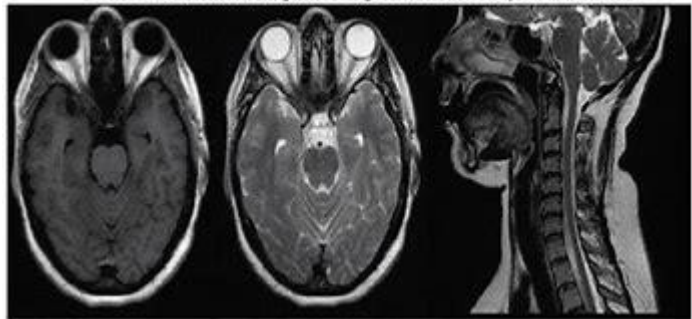
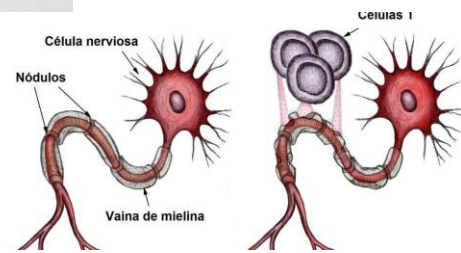
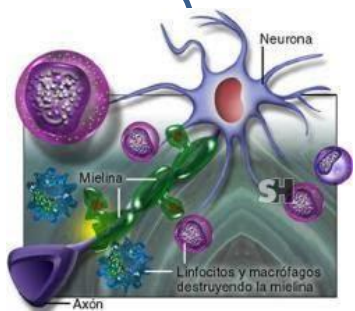
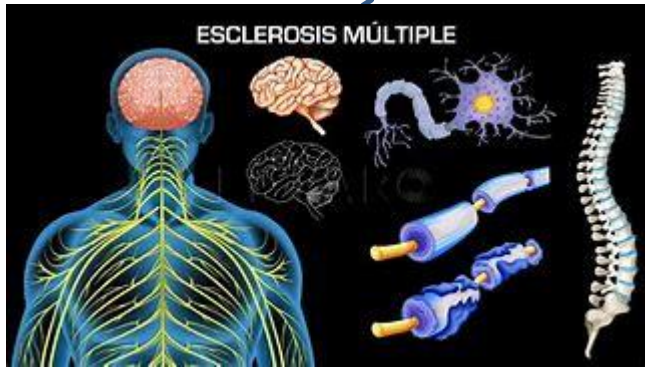
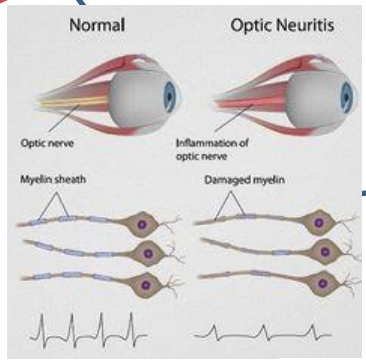
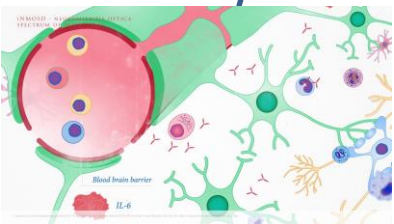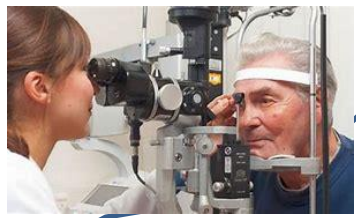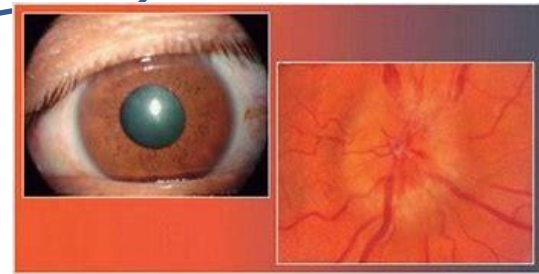


FIGURA 1. Resonancia magnética con gadolinio de cerebro y columna cervical



Neuromielitis Óptica



- Pittock sJ, Weinshenker BG, Lucchinetti cF, et al. neuromyelitis optica brain lesions localized at sites of high aquaporin 4 expression. arch neurol. 2006;63(7):964-8
- 9191_14-20-Revision-Rojas-31-1.pdf (hospitalitaliano.org.ar)