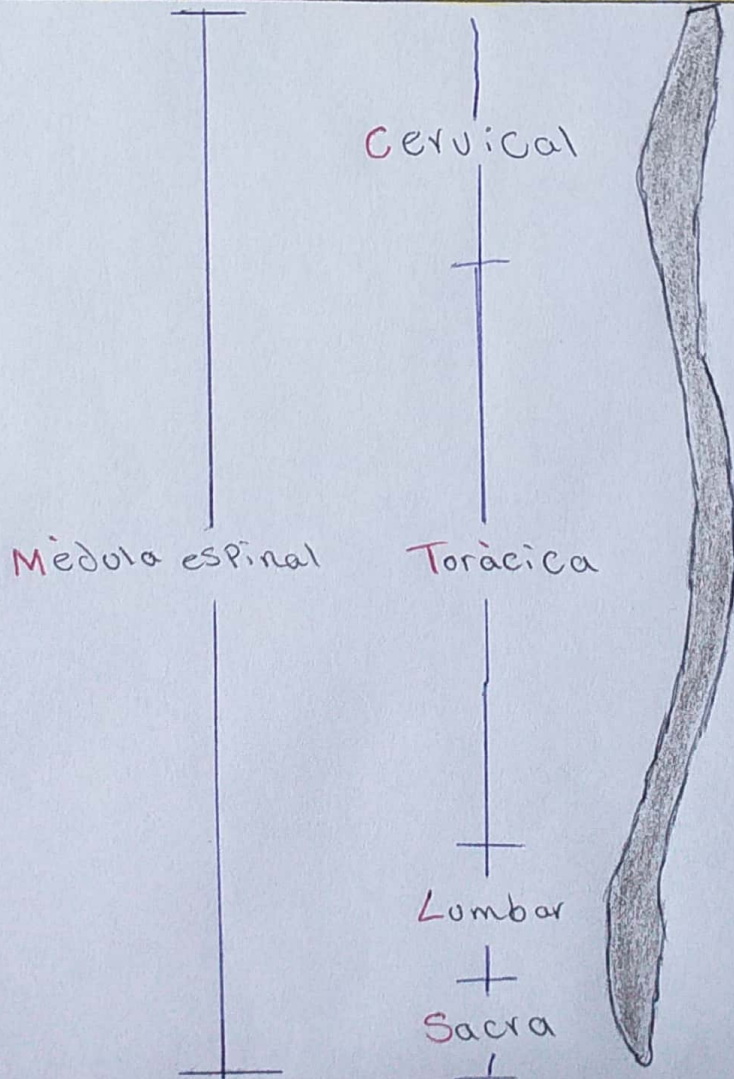
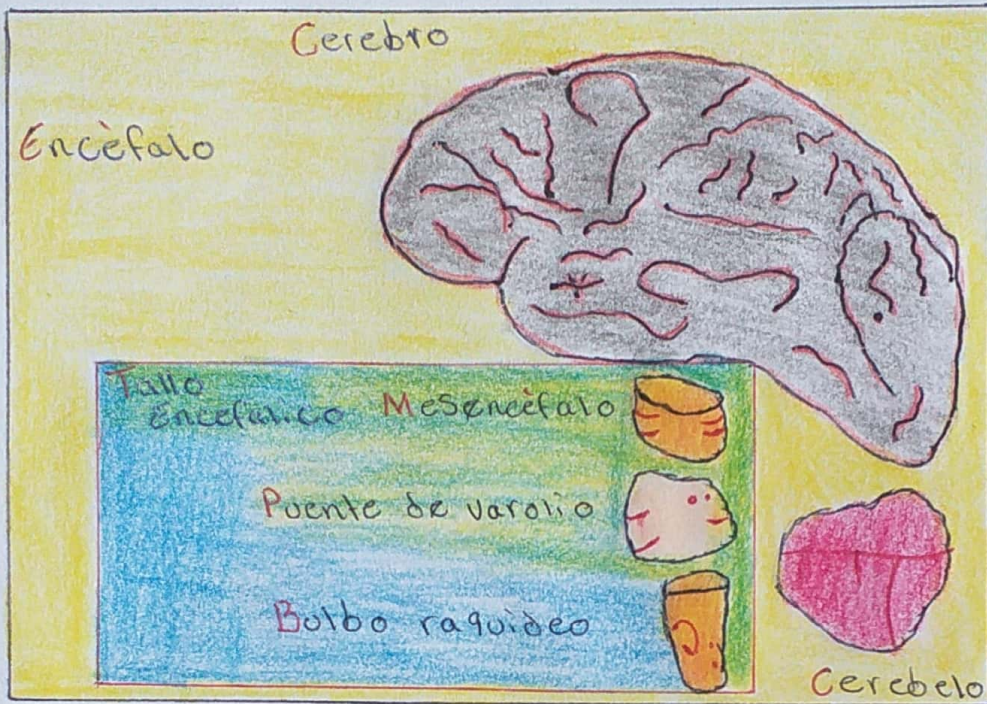


Sistema Nervioso Central. (Humano)

20-04-21

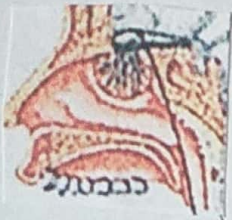
Sandra
Ramos
Solis



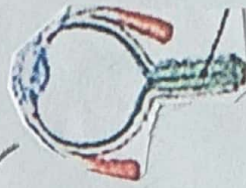
PARES CRANEALES

Sandra Ramos Solís

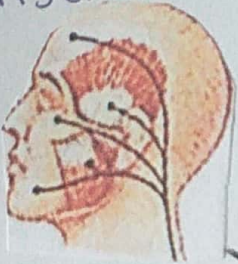
I. Nervio olfatorio



II. Nervio óptico



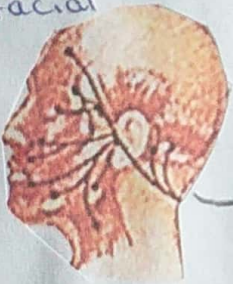V. Nervio trigémino



III, IV y VI. Nervios del movimiento de los ojos



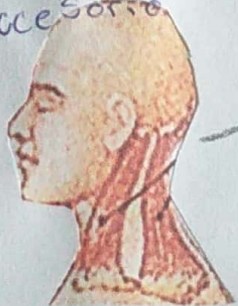
VII. Nervio facial



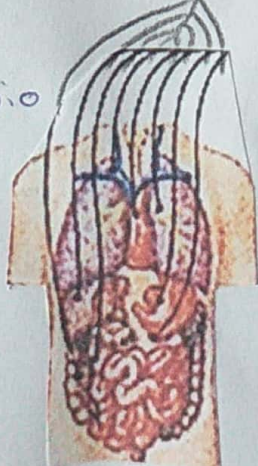
VIII. Nervio vestibulococlear



XI. Nervio accesorio



X. Nervio vago



IX. Nervio glossofaríngeo

XII. Nervio hipogloso

