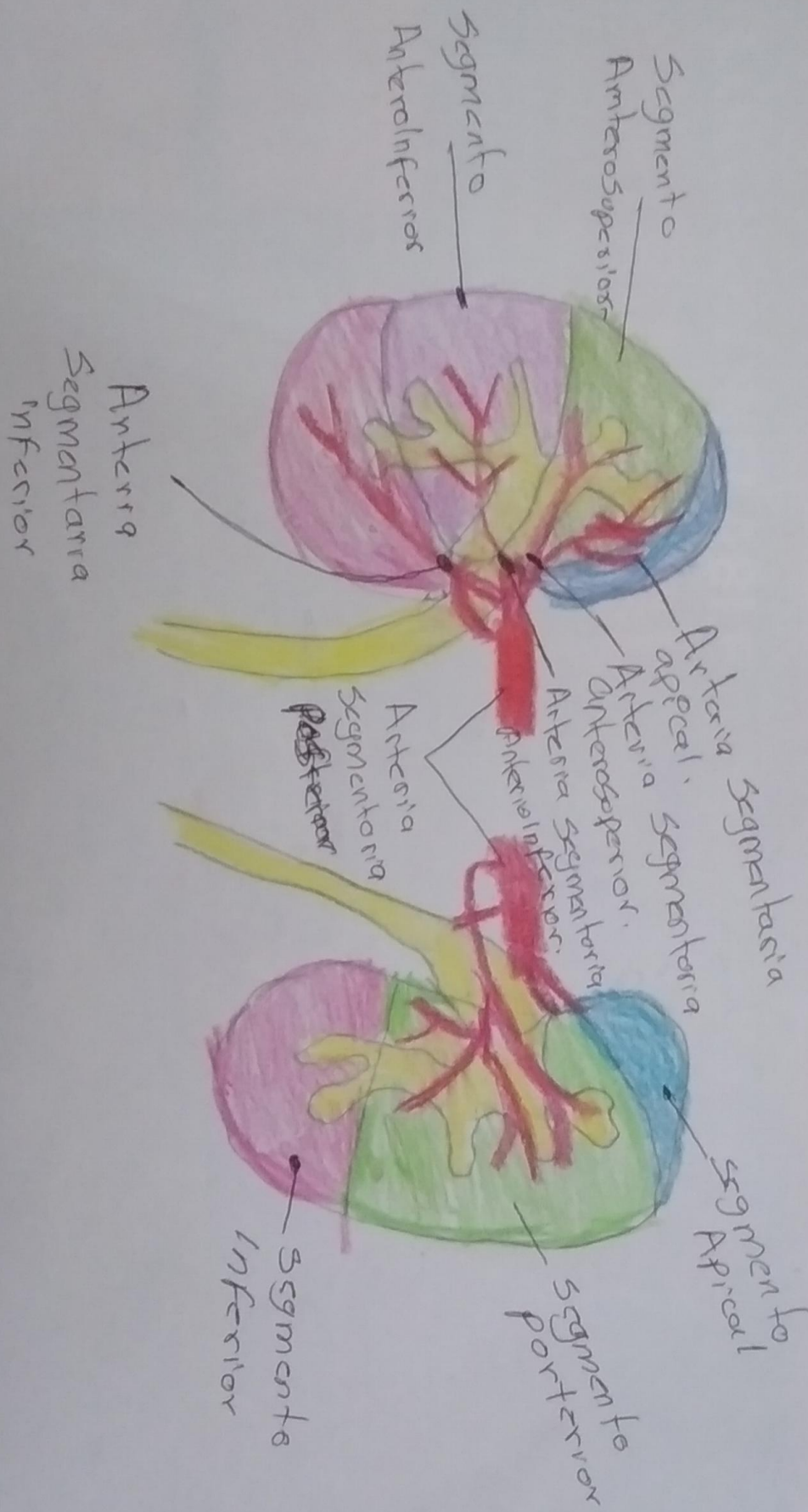
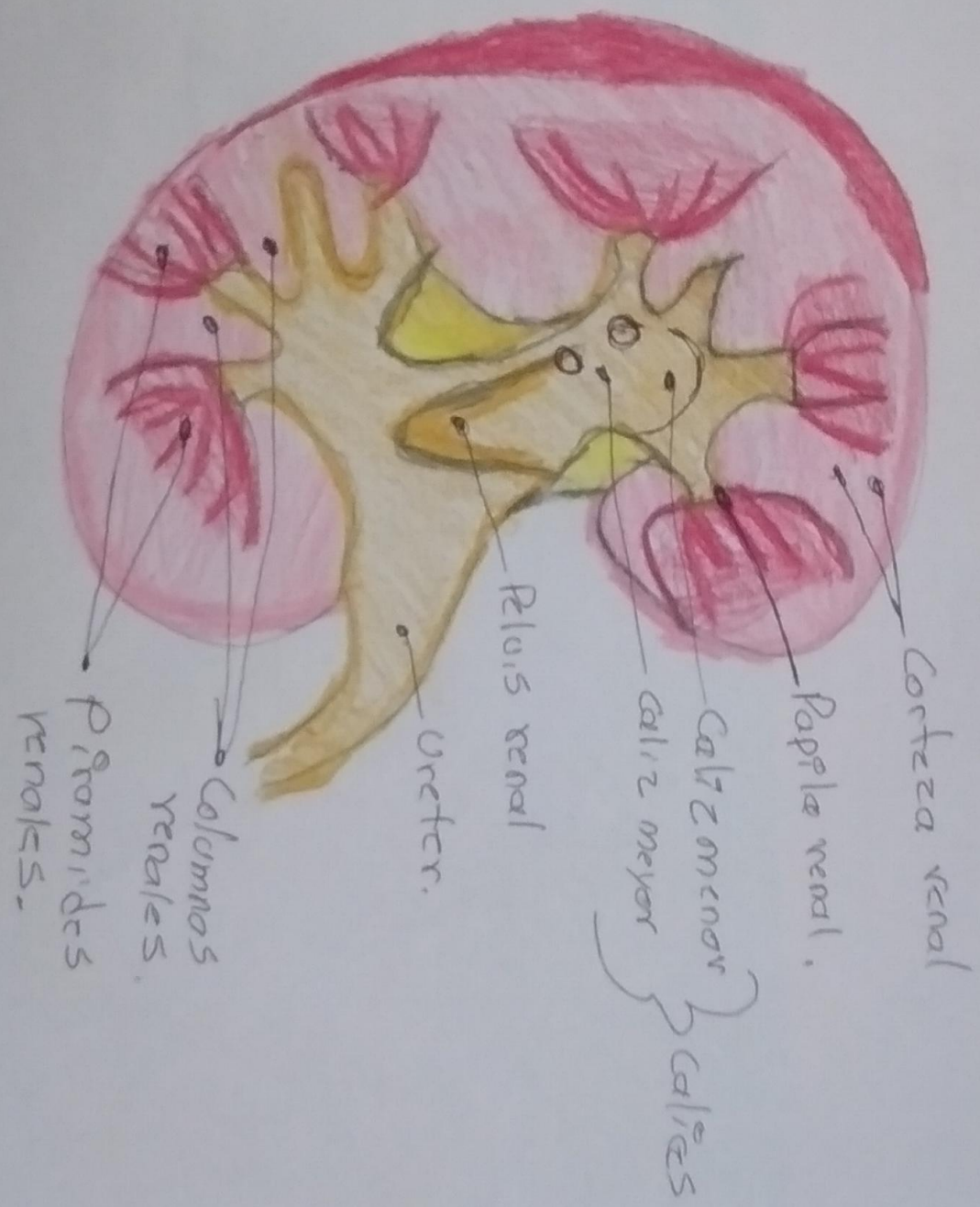
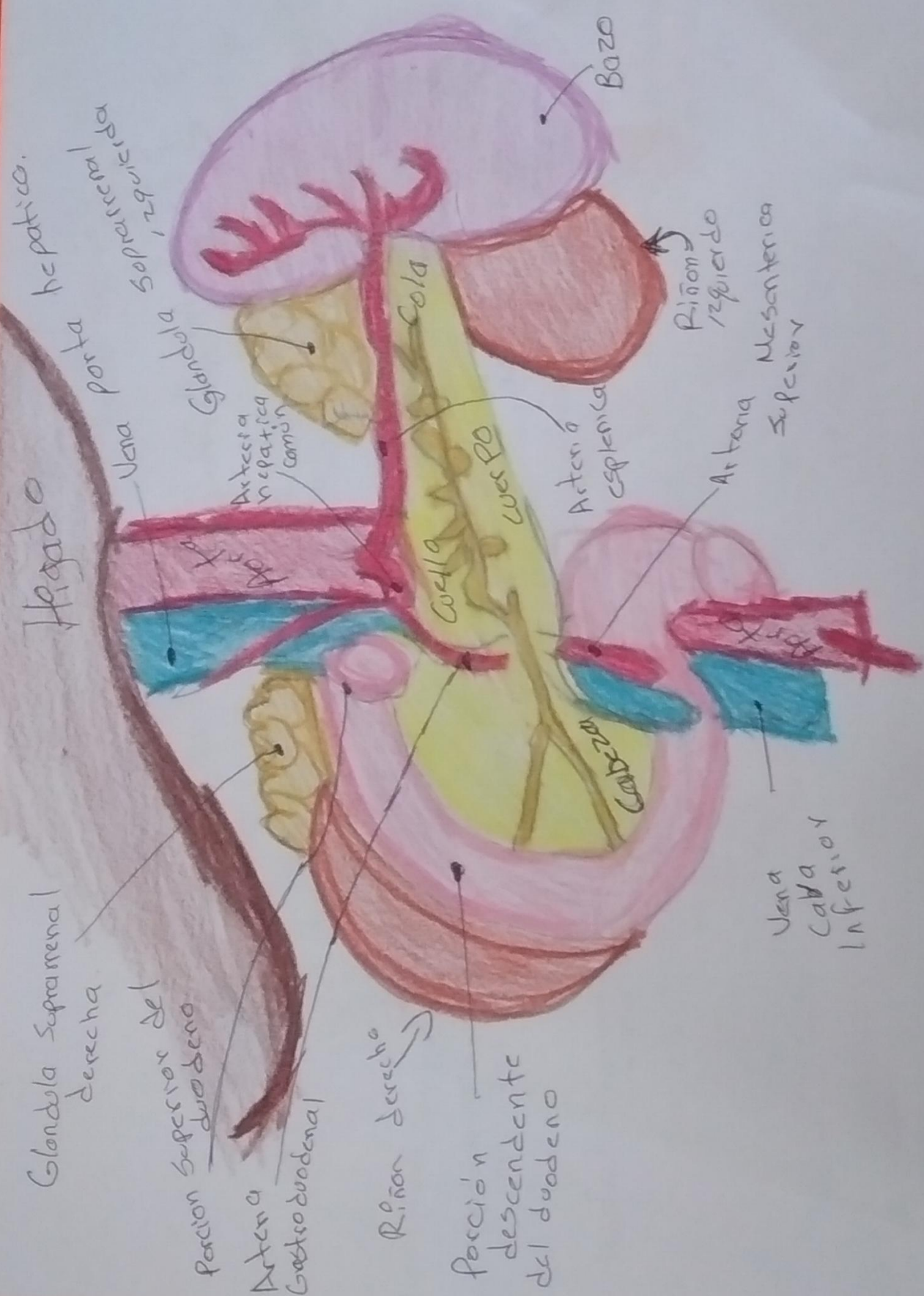Hgado
Vena porta
hepatica.
Arteria supra renal
derecha

Glándula Suprarrenal
derecha

Porción superior del
duodeno

Arteria
Gastroduodenal

Riñón derecho

Porción
descendente
del duodeno

Bazo

Riñón
izquierdo

Arteria
Mesenterica
Superior

Arteria
esplenica

Arteria
Superior

Vena
Cava
Inferior

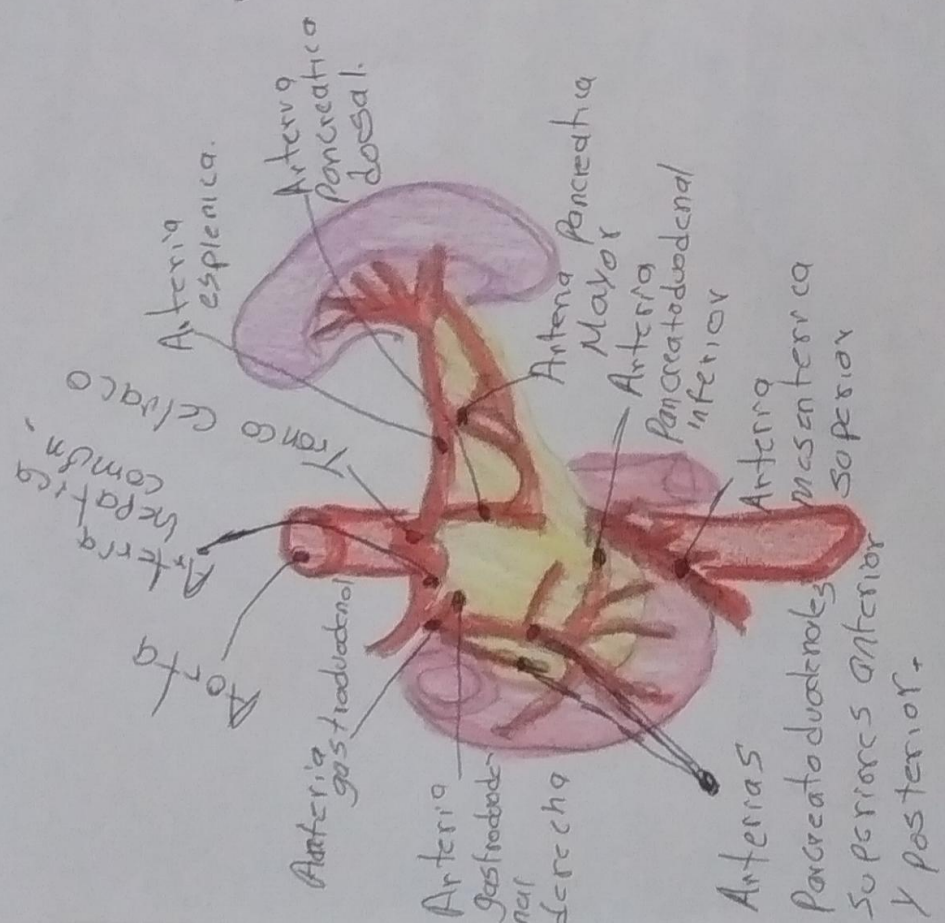
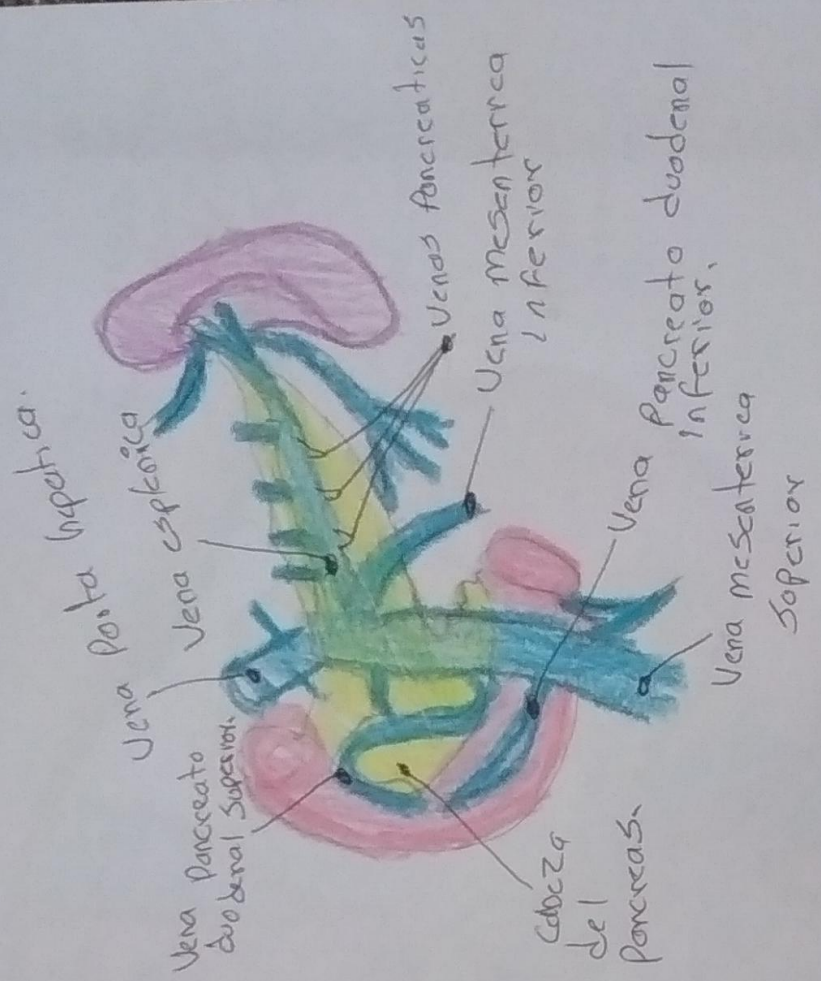
Glándula

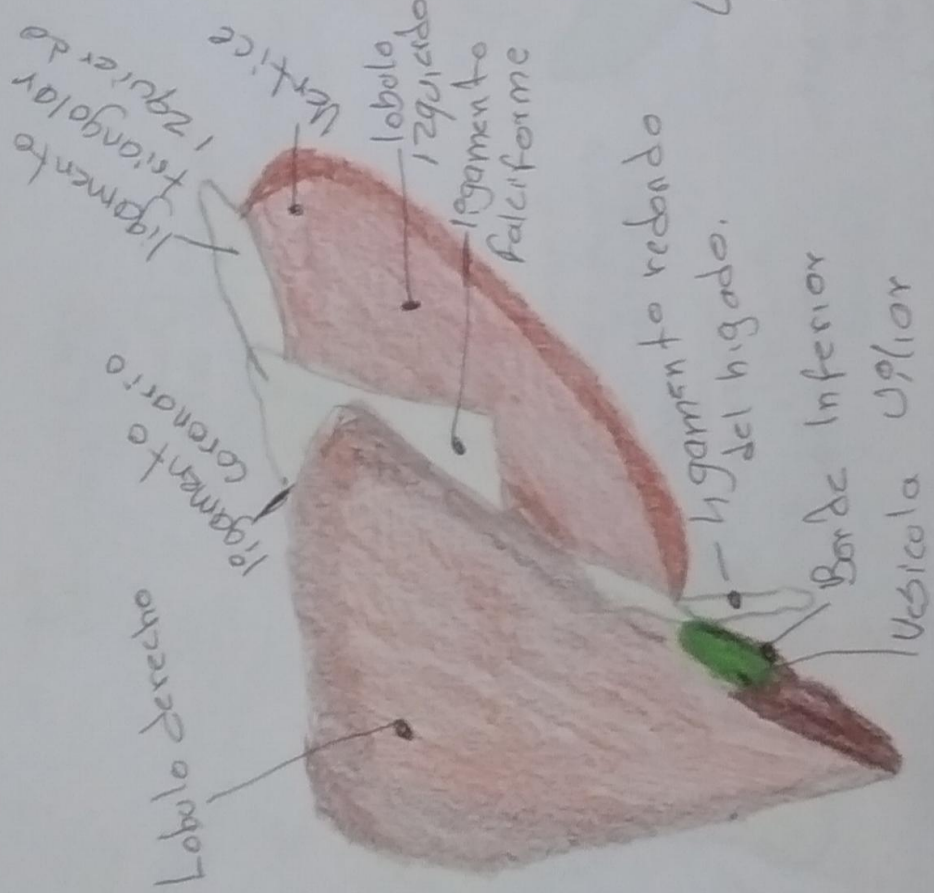
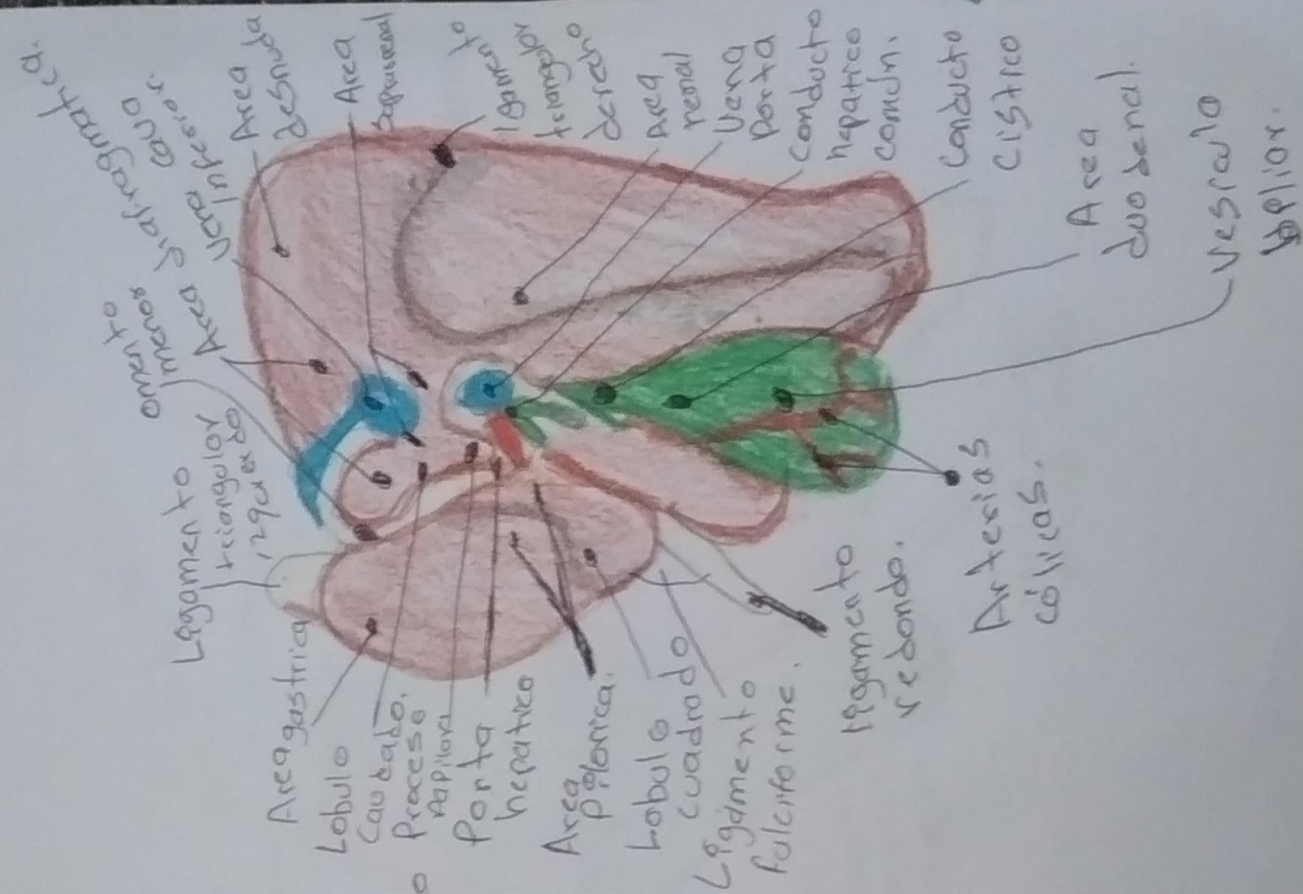
Arteria
hepatica
comun

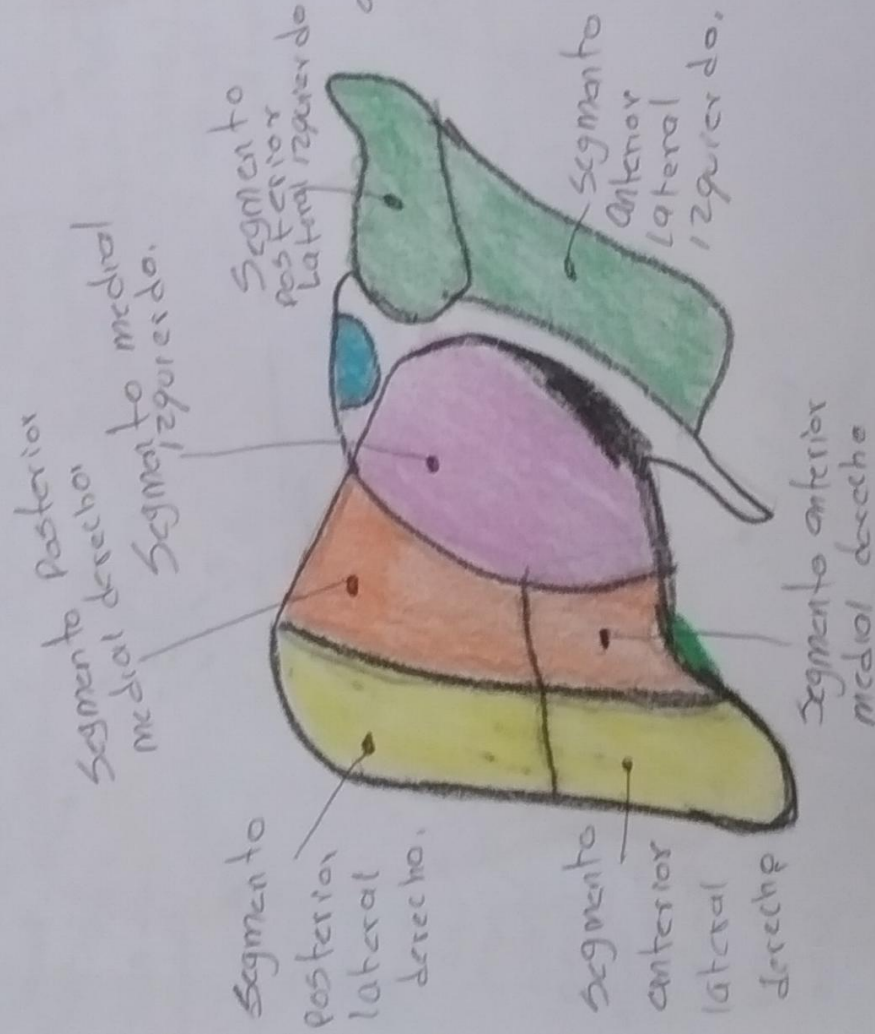
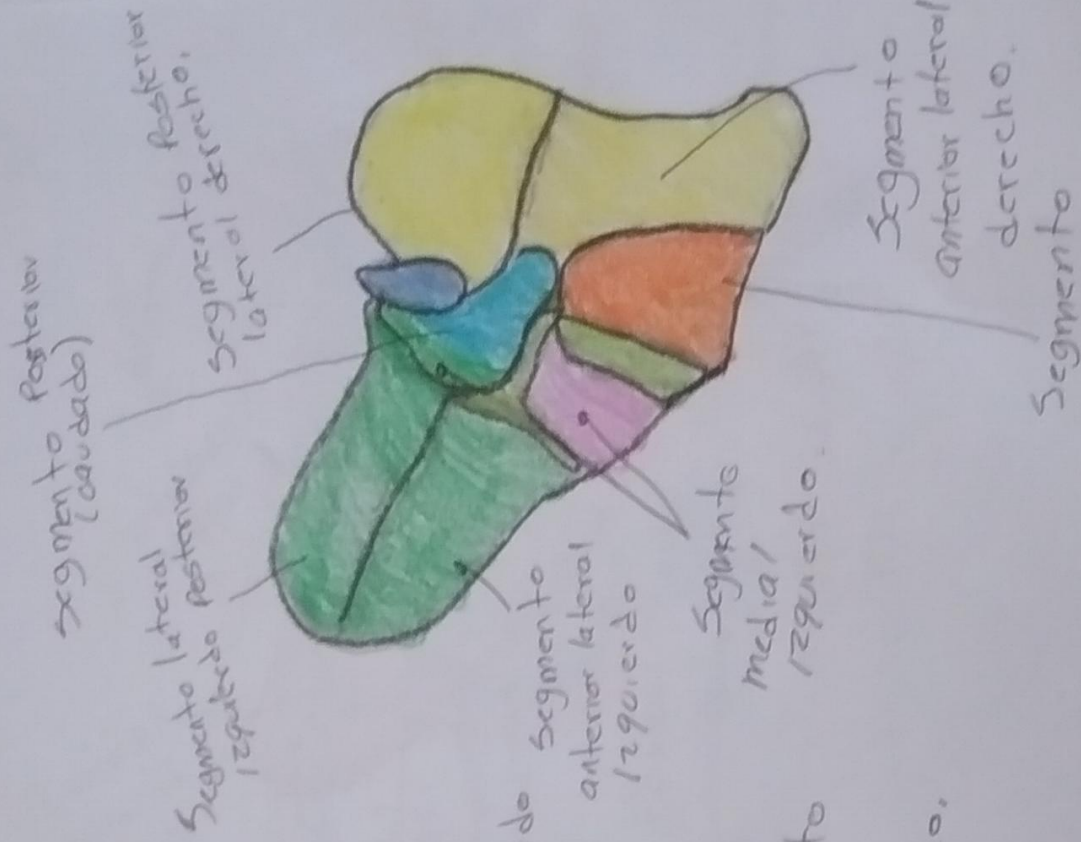
Cola
Cuello
Cabeza

Arteria
esplenica

Arteria
Superior

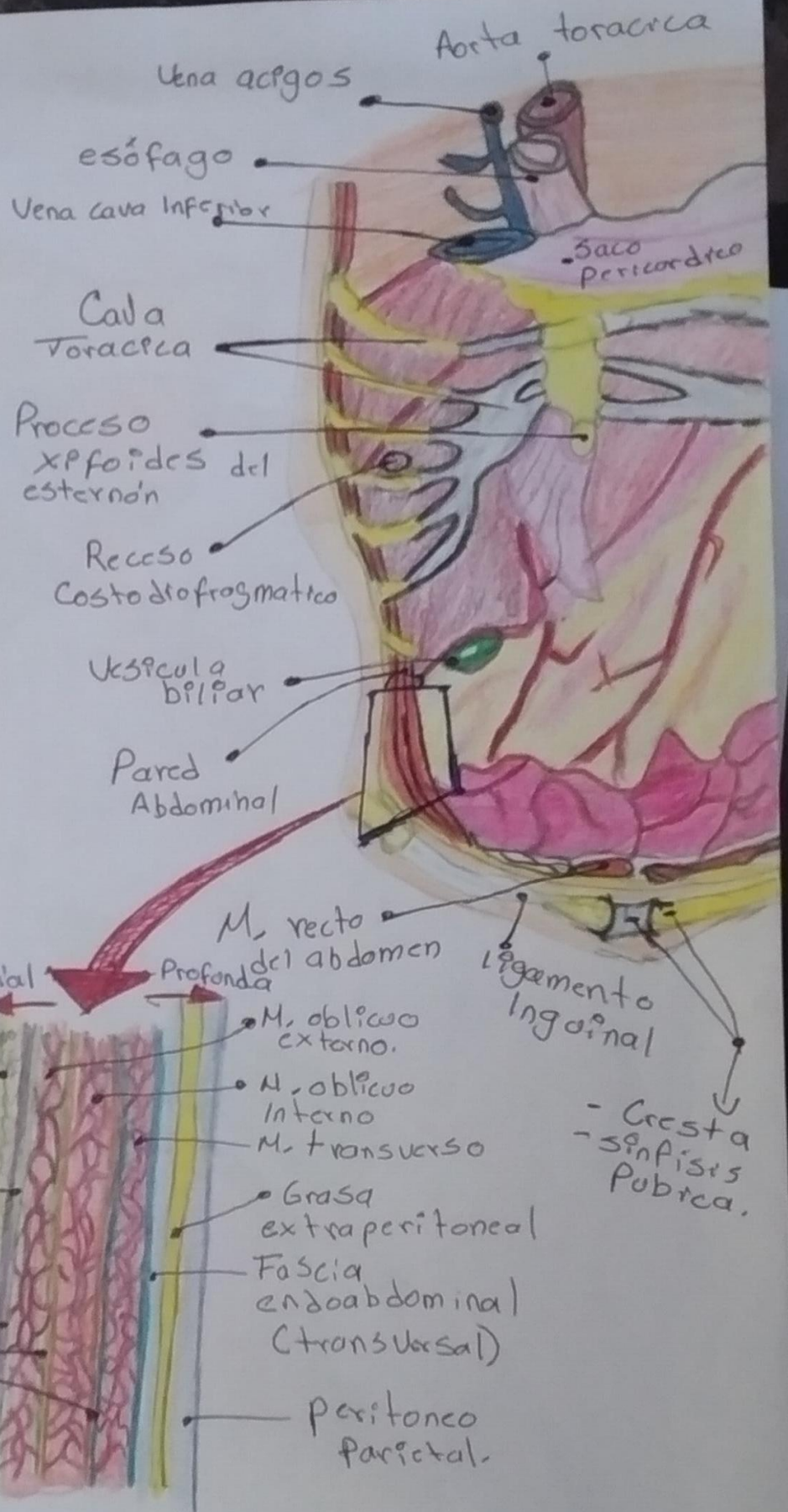


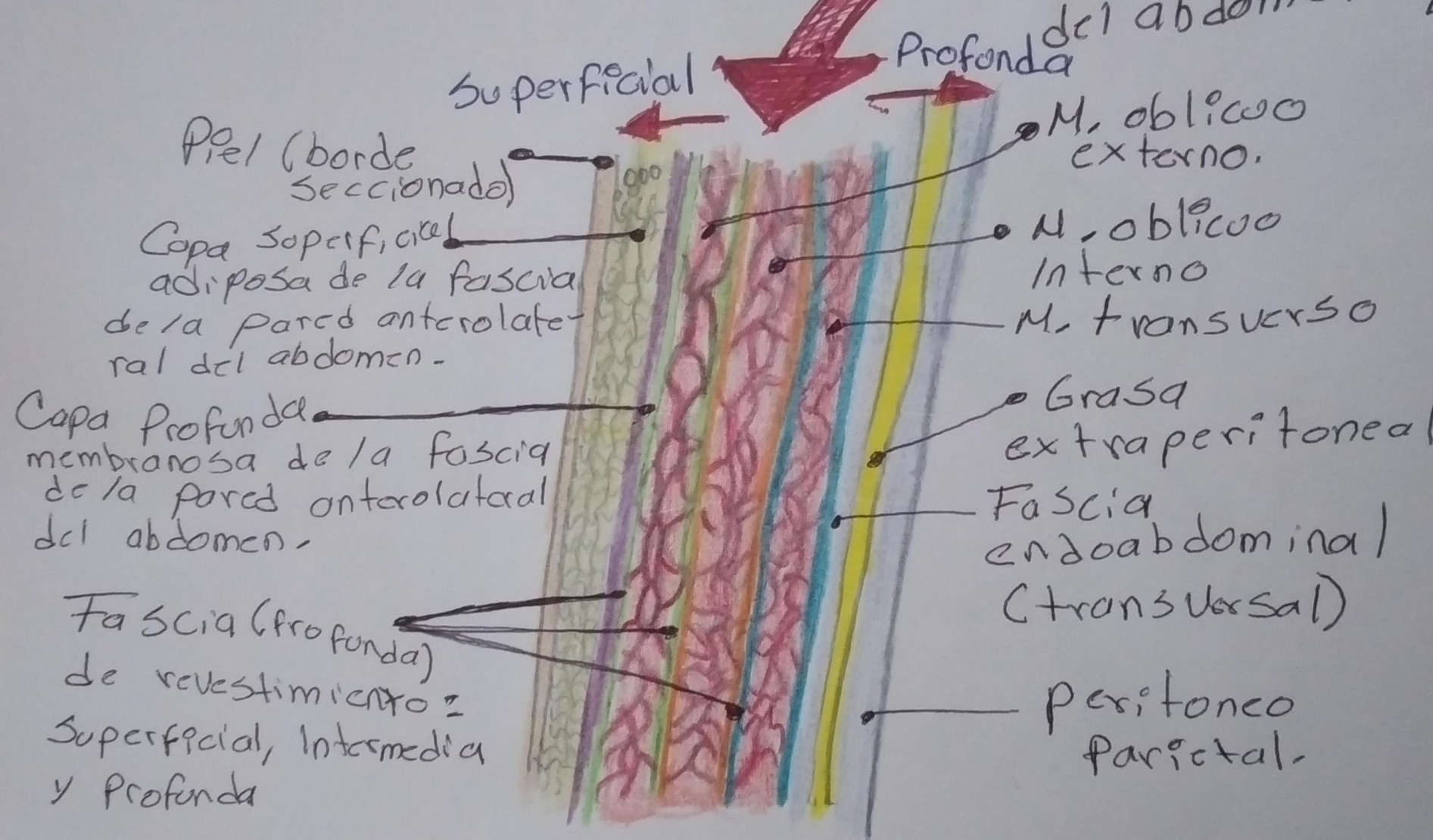




PARED ABDOMINAL.

#





Superficial

Profunda del abdomen

Piel (borde seccionado)

Capa superficial adiposa de la fascia de la pared anterolateral del abdomen.

Capa profunda membranosa de la fascia de la pared anterolateral del abdomen.

Fascia (profunda) de revestimiento = Superficial, Intermedia y Profunda

M. oblicuo externo.

M. oblicuo interno

M. transverso

Grasa extraperitoneal

Fascia endoabdominal (transversal)

Peritoneo parietal.