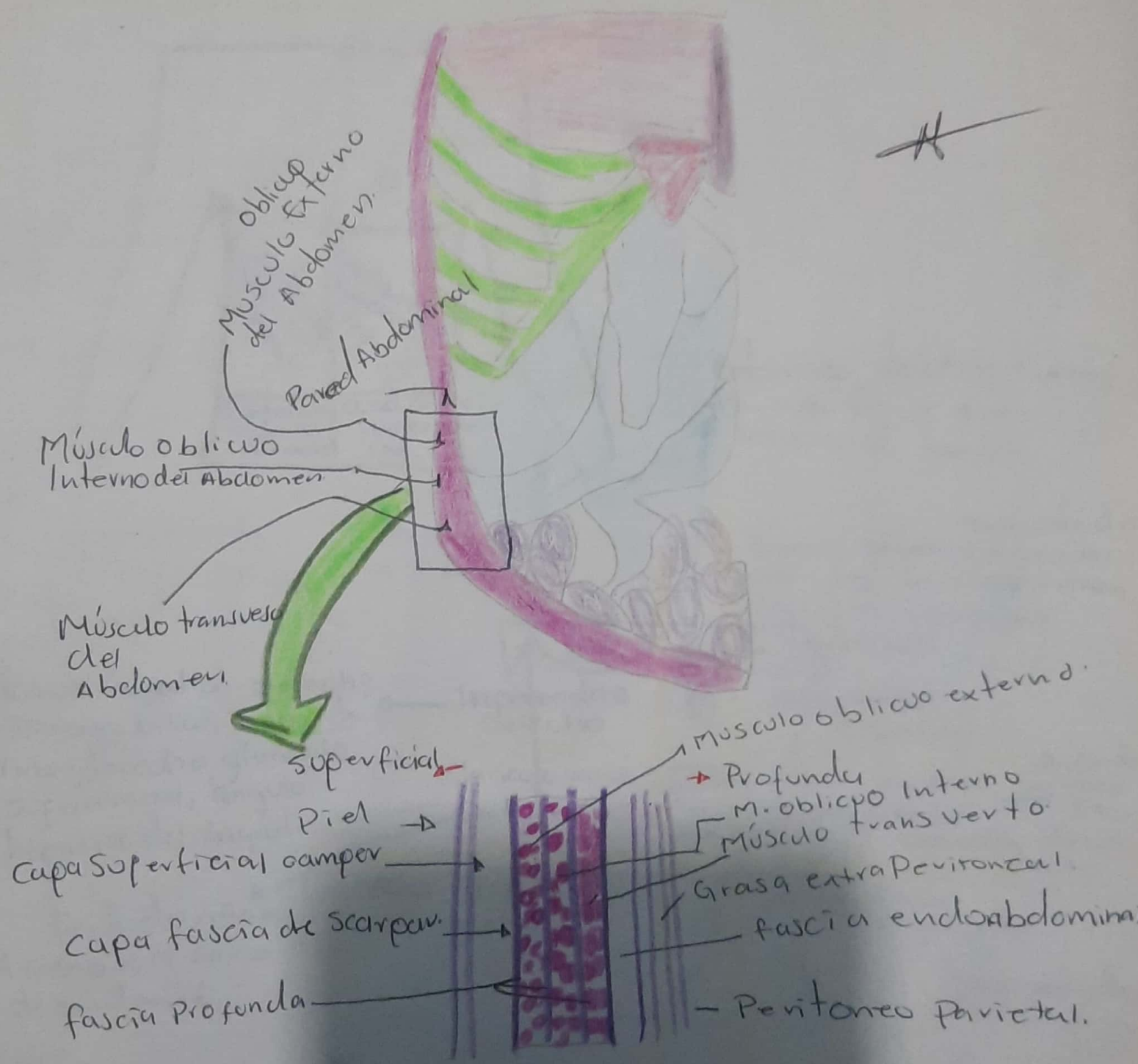


Morfología
05-09-21

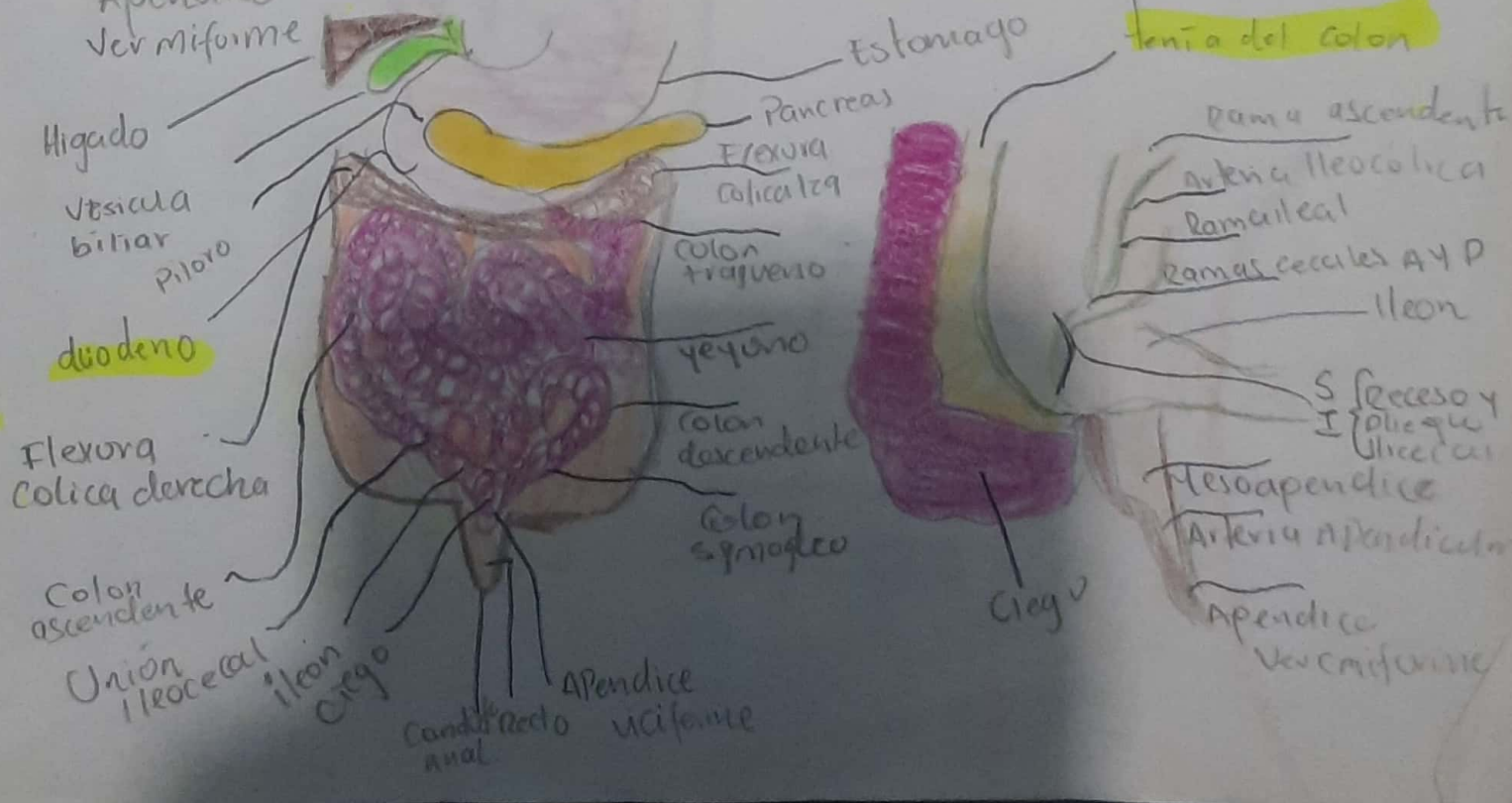
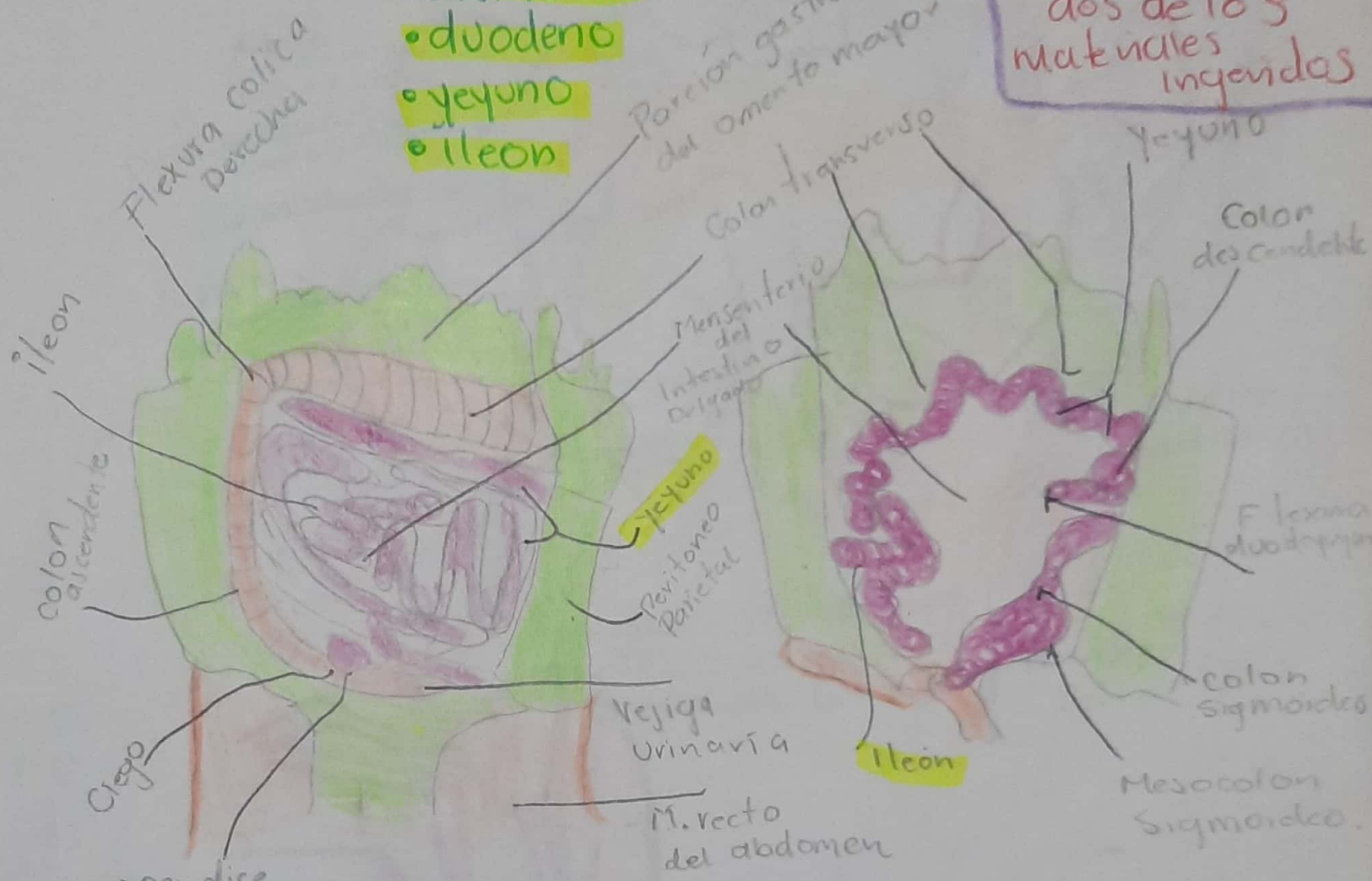
Fascias de la Pared Anterolateral del Abdomen.


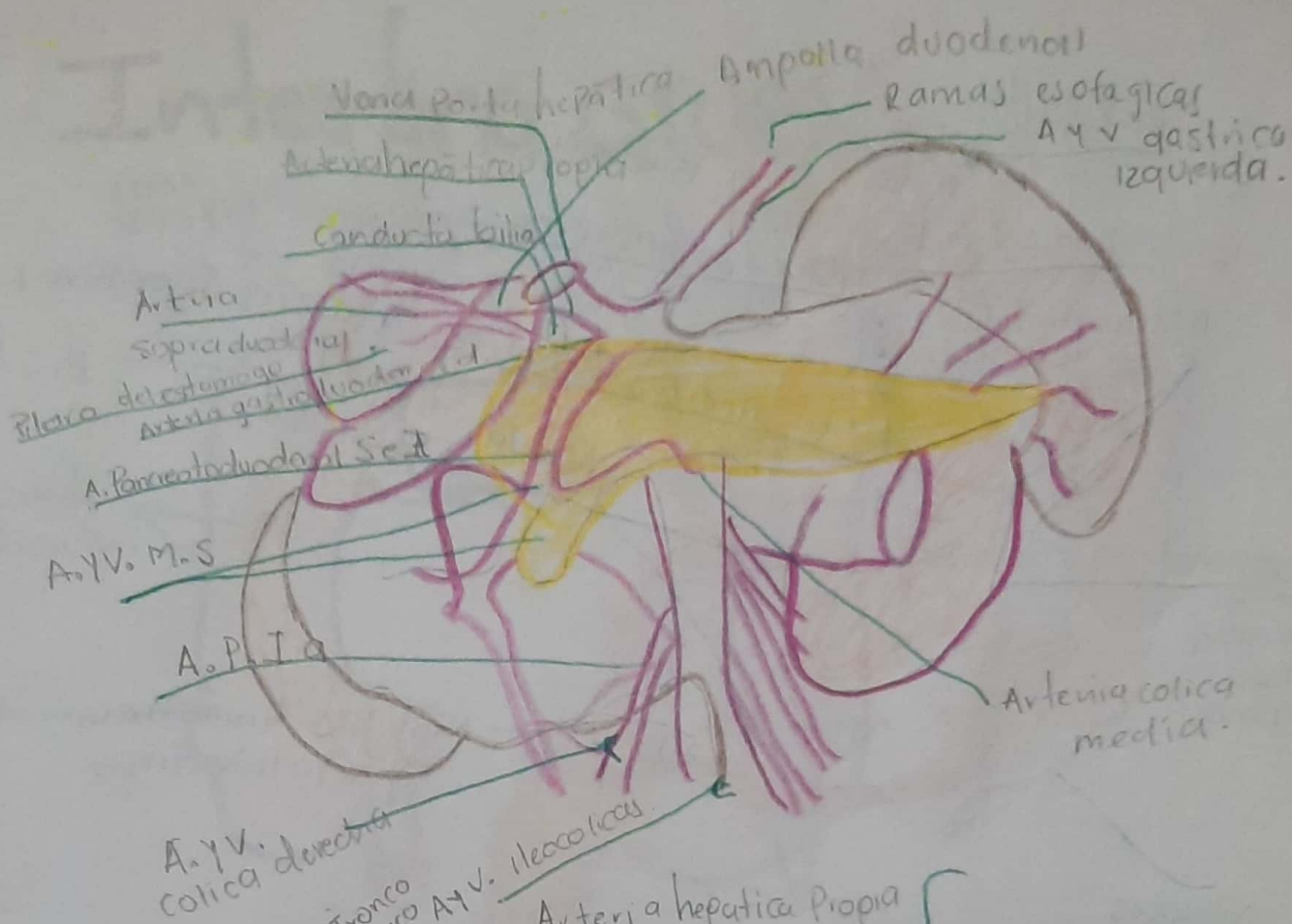


Intestino Delgado.

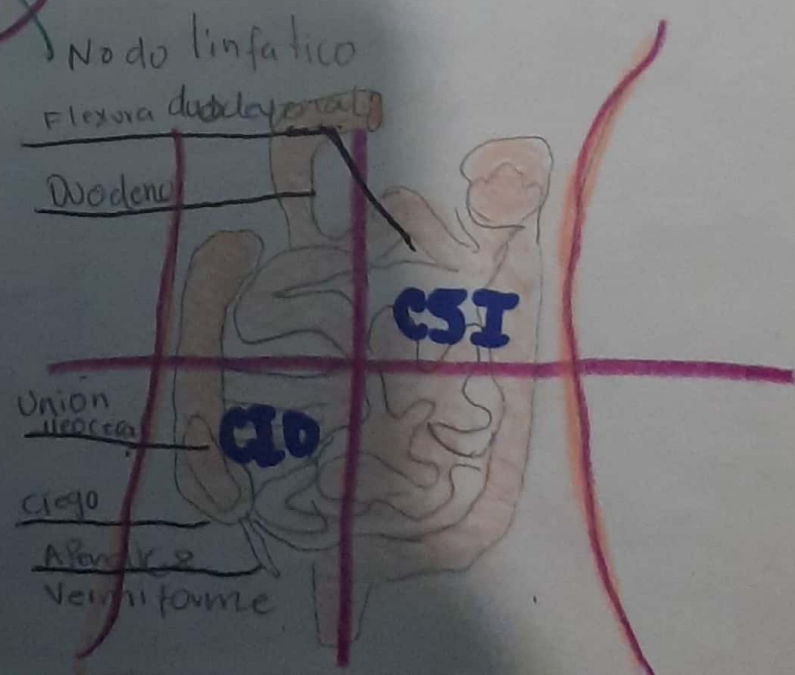
Donde se absorben los nutrientes obtenidos de los materiales ingeridos

- Constituido
- duodeno
 - yeyuno
 - ileon

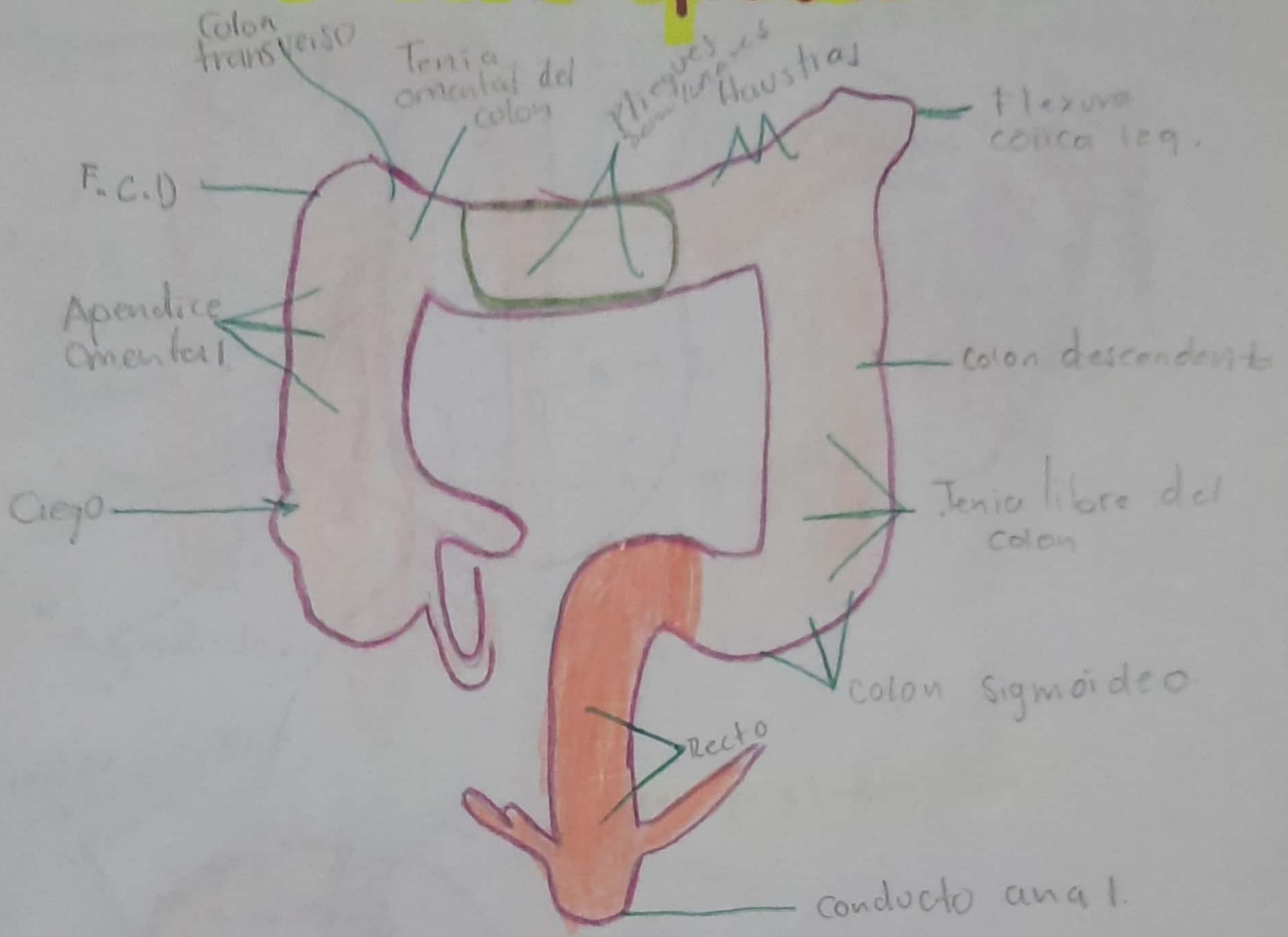




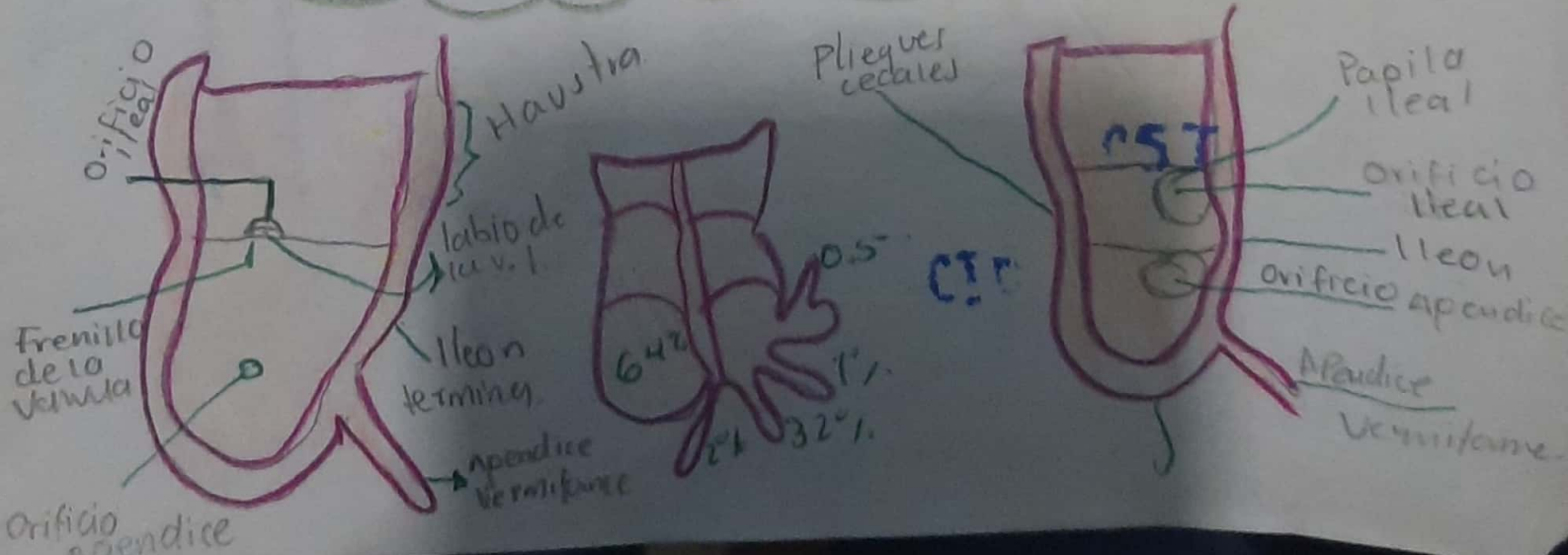
YEYUNO
 Y
 ILEON



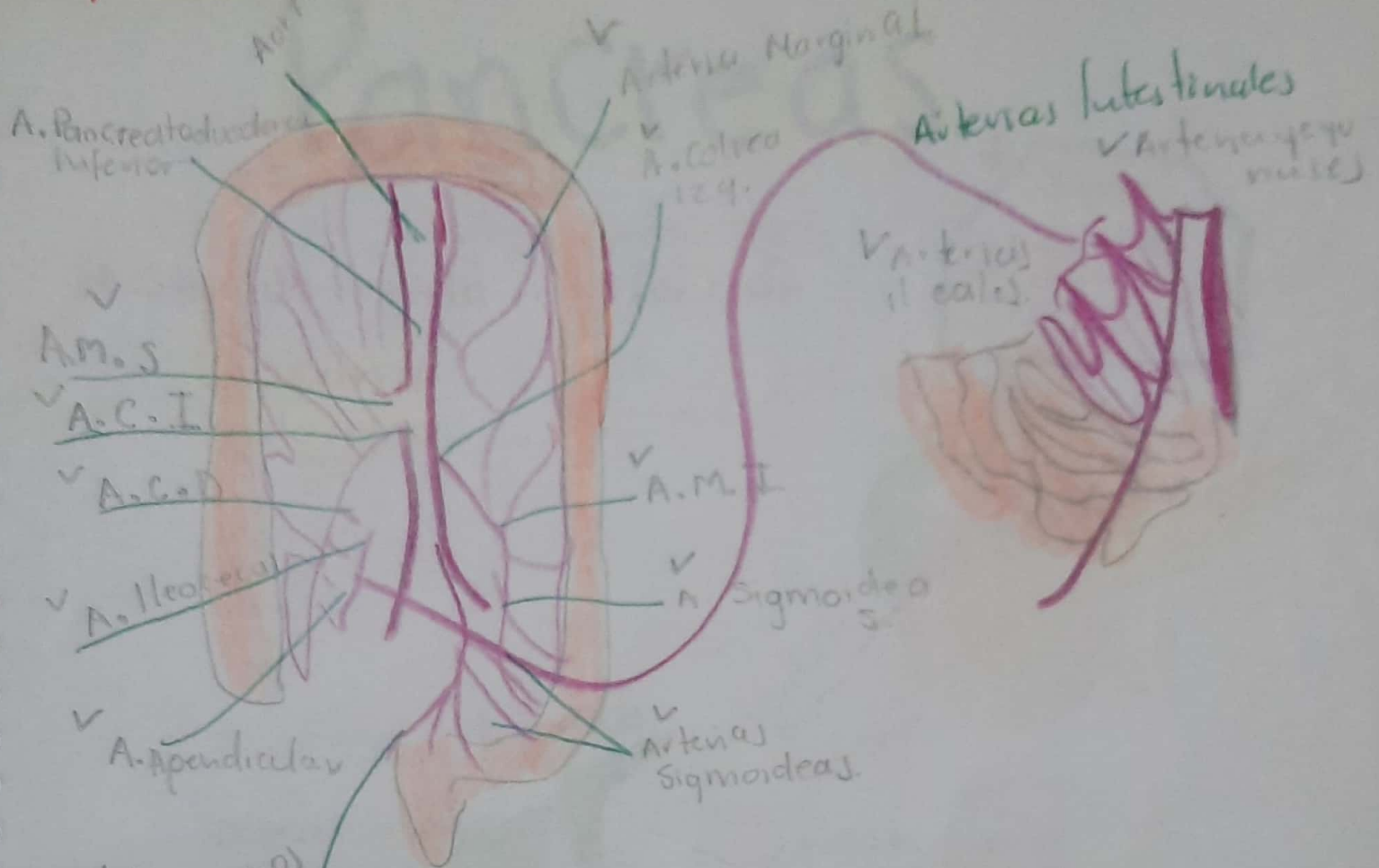
Intestino grueso...



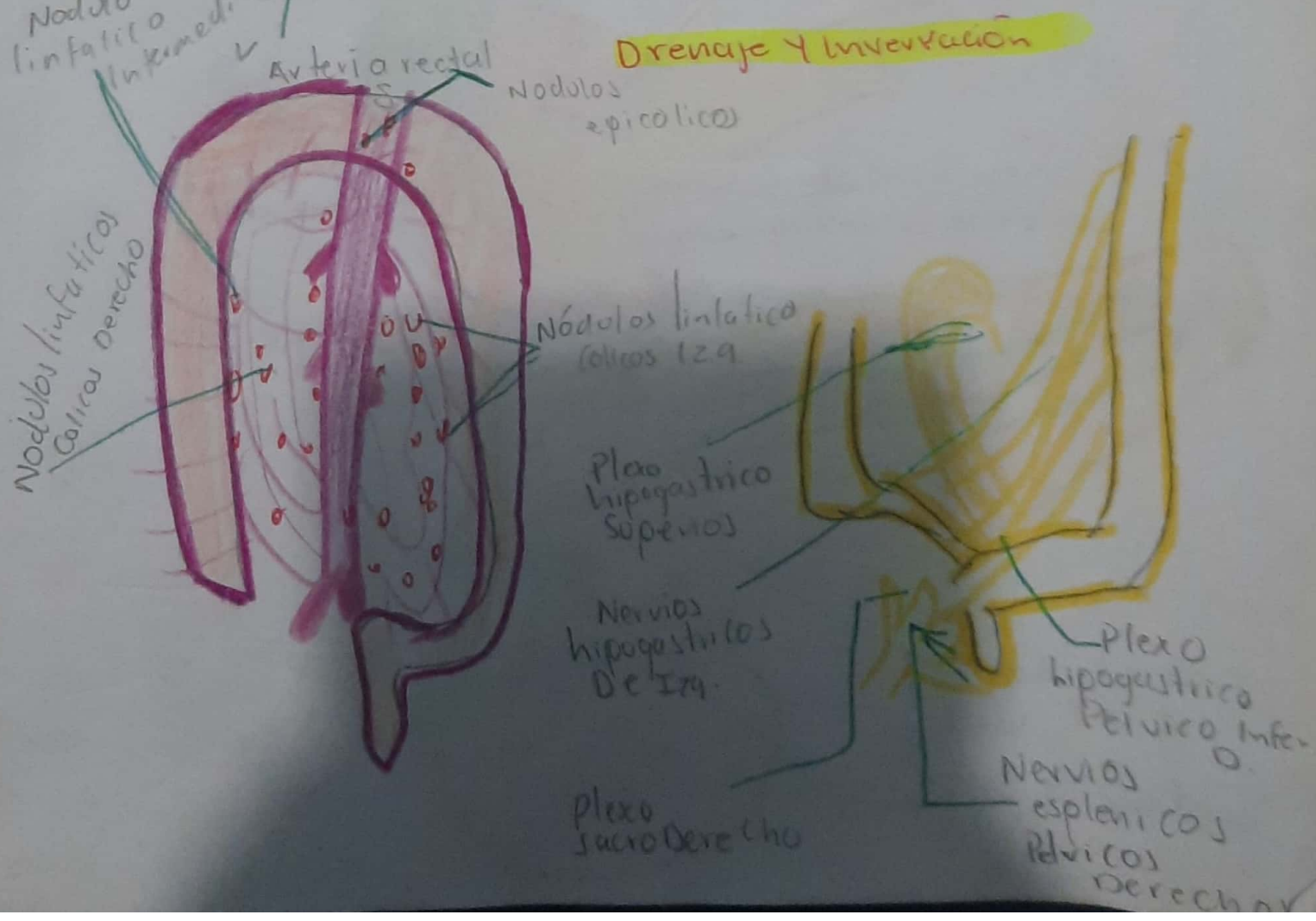
- Se absorbe el agua de los residuos no ingeridos del quimo liquido, convirtiendolo en heces.



Irrigación y Drenaje.



Drenaje y Inervación



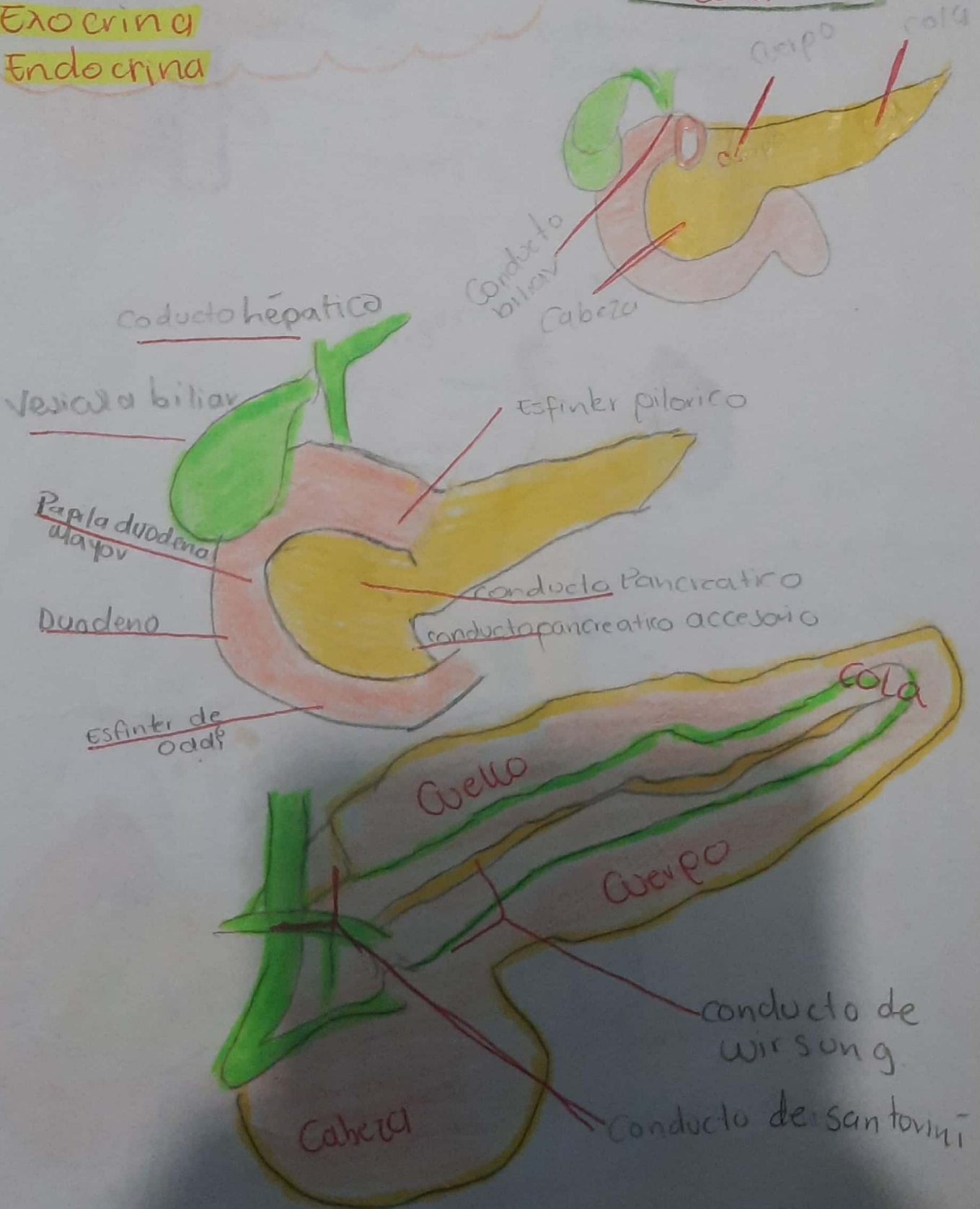
Pancreas

→ Glandula Mixta de función

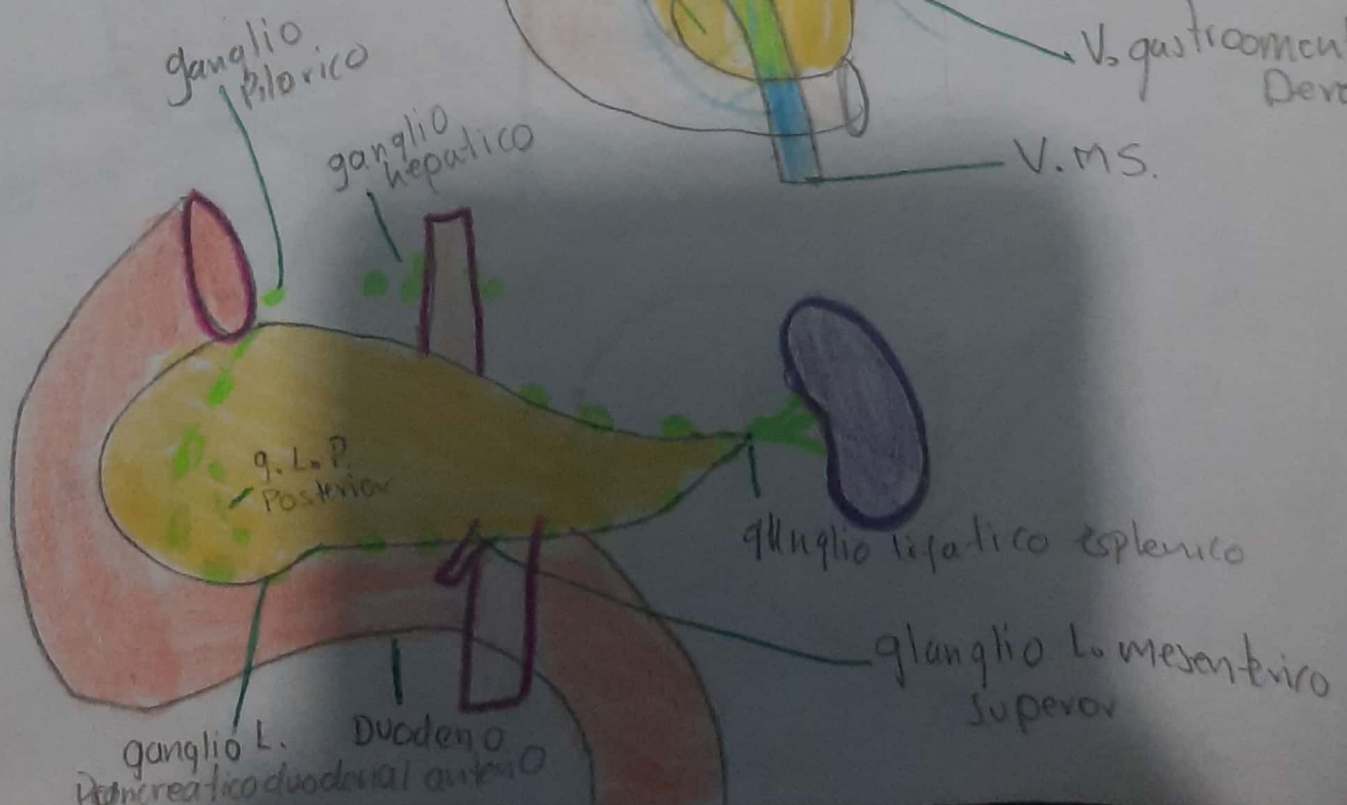
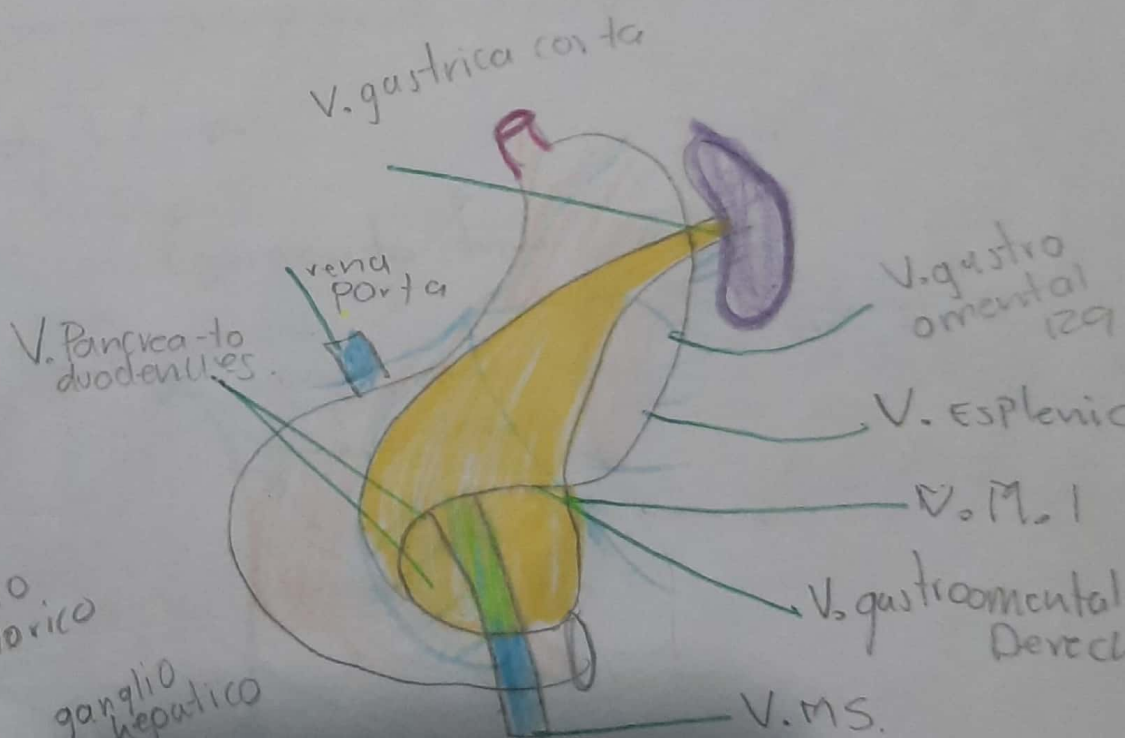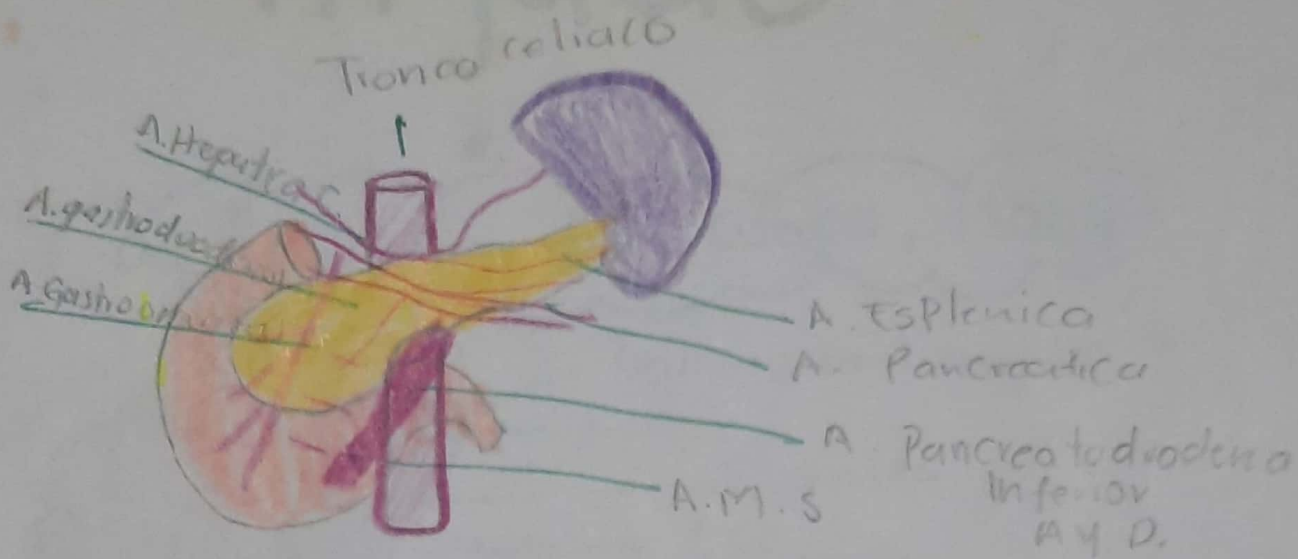
Exocrina

Endocrina

- Tiene
- Cabeza
 - Cuello
 - cuerpo
 - Cola

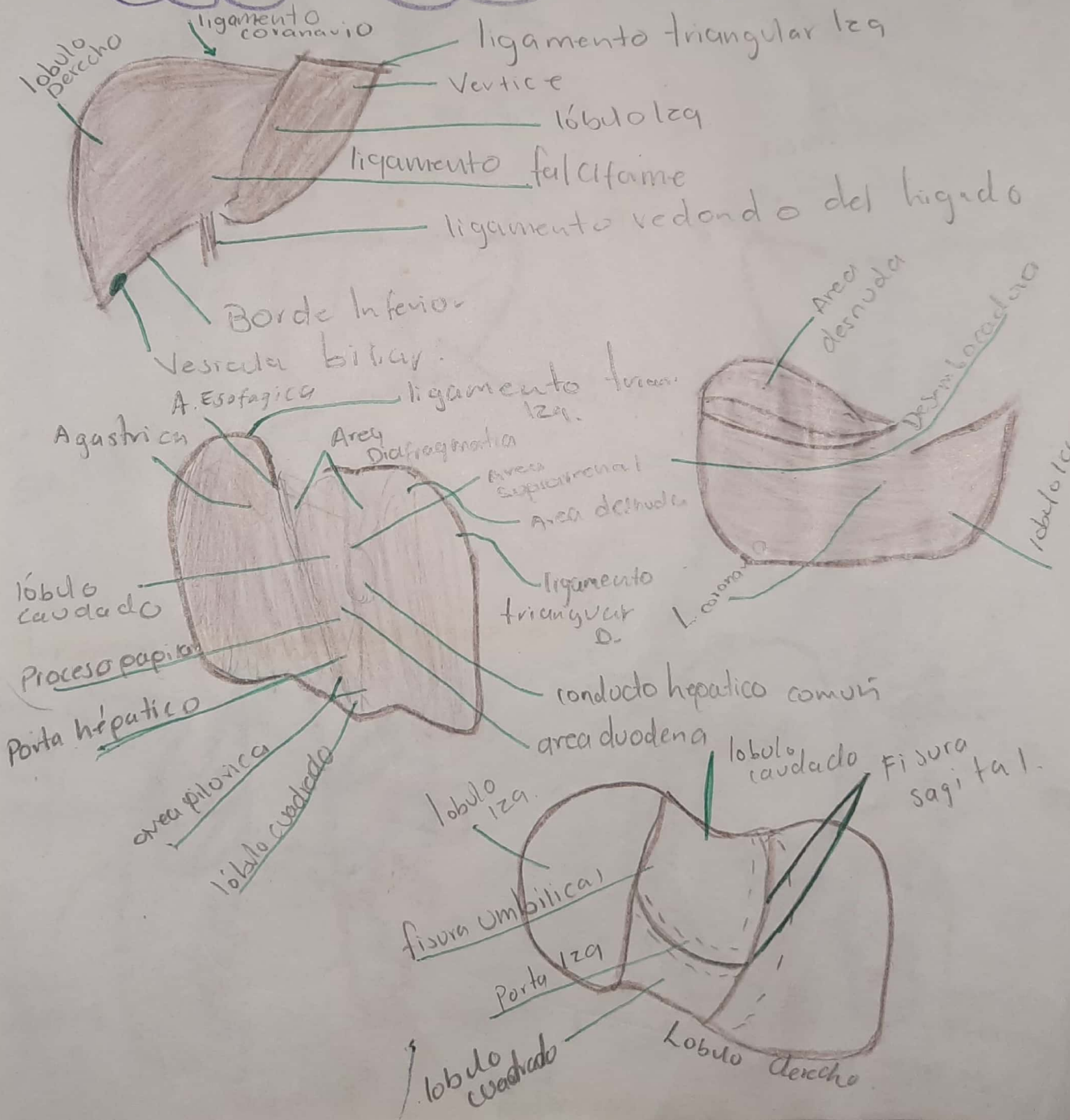


Irrigación, Drenaje, Inervación



Higado

-organo mayor del cuerpo, 1500g.



Segmentos

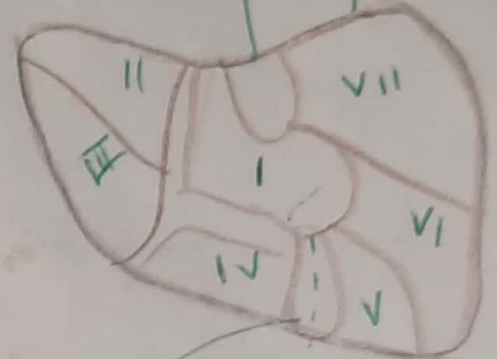
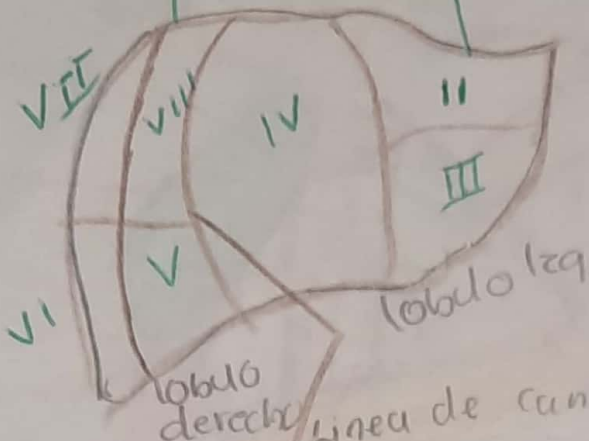
P.O.H.D

División Medial

O.M. IZq

Porción hepática IZq

Porción Posteri del hígado



Fisura Sagital Derecha

S.P.M.D

S.M.I

S.P. lateral IZq

S.L.P. IZq

S.P.L.D

S.P.L.D

S.A.L. IZq

S.A.L. IZq

S.A.L.D

S.A.M.D

S.M. IZq

S.A.M.I

Irrigación, Inervación y Drenaje.

Foramé de la Vena Cava en el diafragma

Vena Hepática

Hiato esofágico del Diafragma

A. gástrica IZq

A. Hepática Propia

vena porta H.

A. Esplénica

A.H.C.

A. renal IZq

A.M.S

plexo hepático

Aorta Abdominal

Vena Cava Inferior

Hígado

Esófago

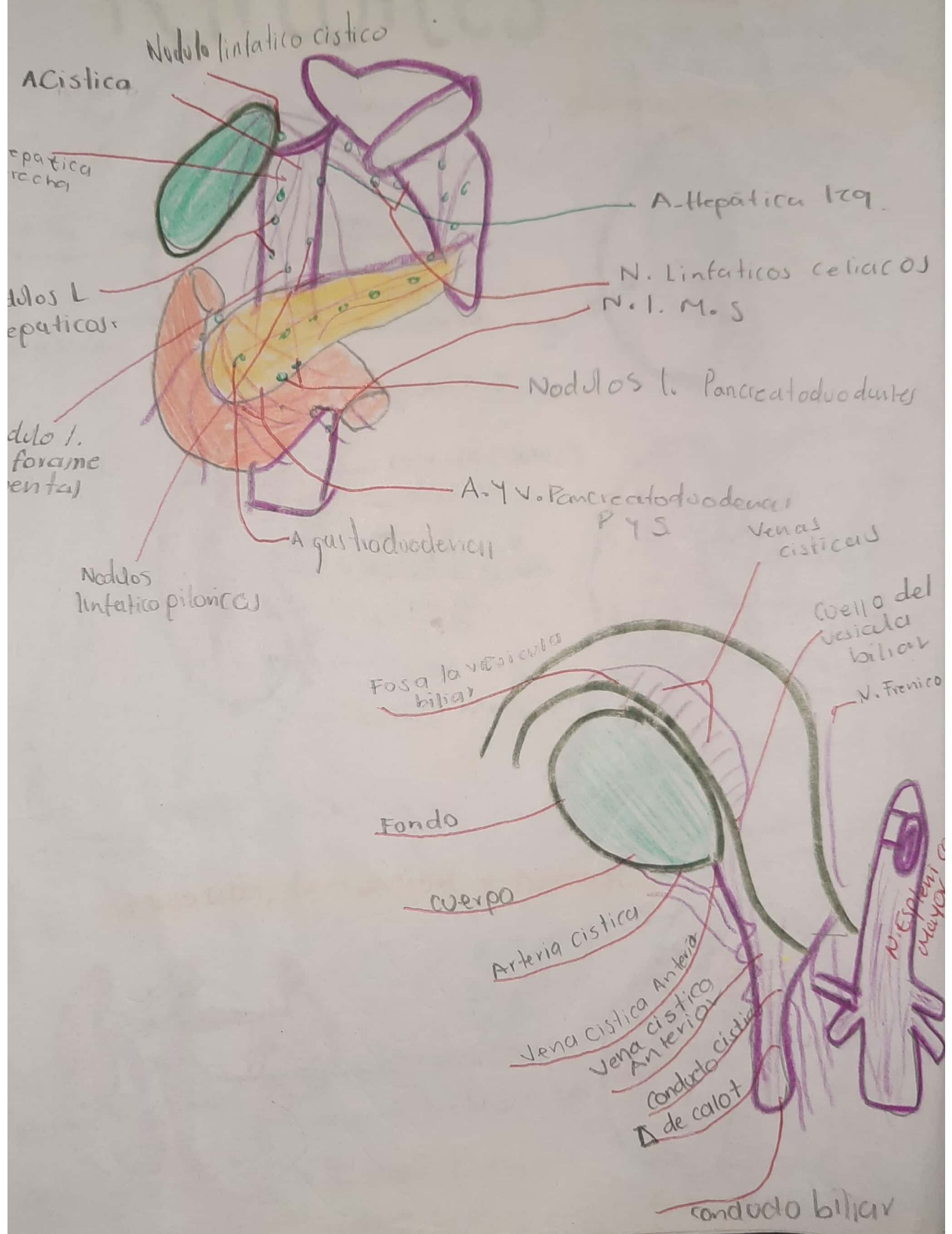
Tronco Anter. Vag.

tronco Vagal

ganglio plexocelíaco

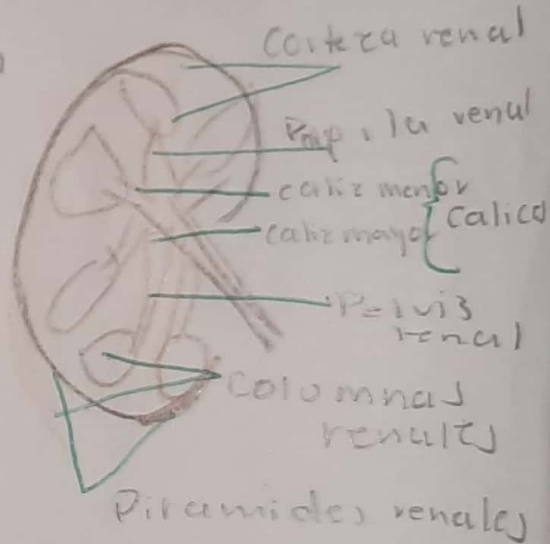
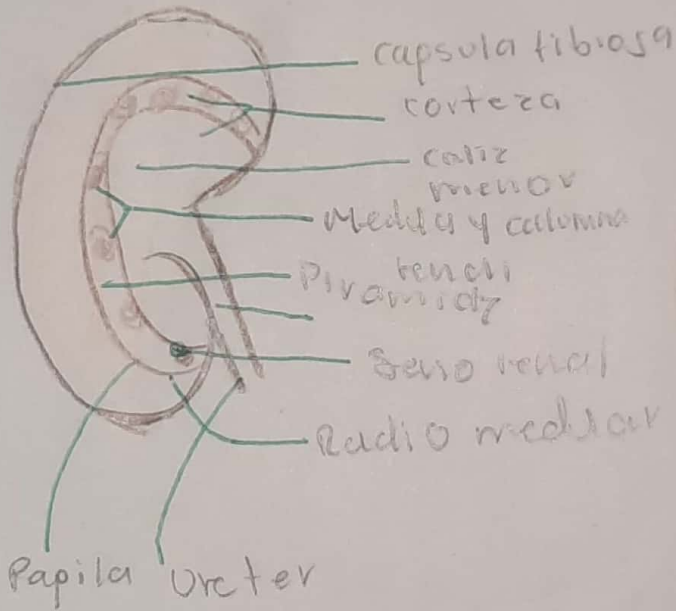
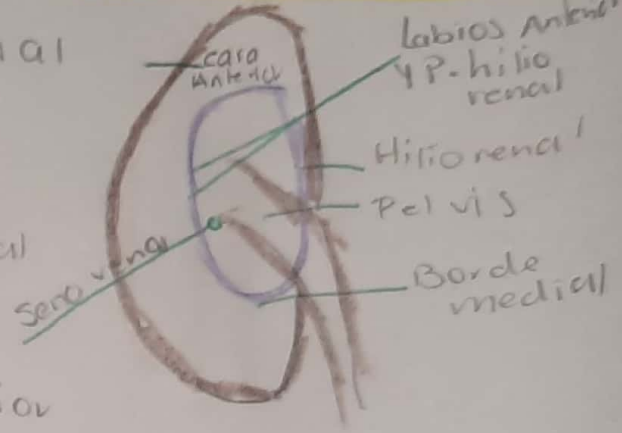
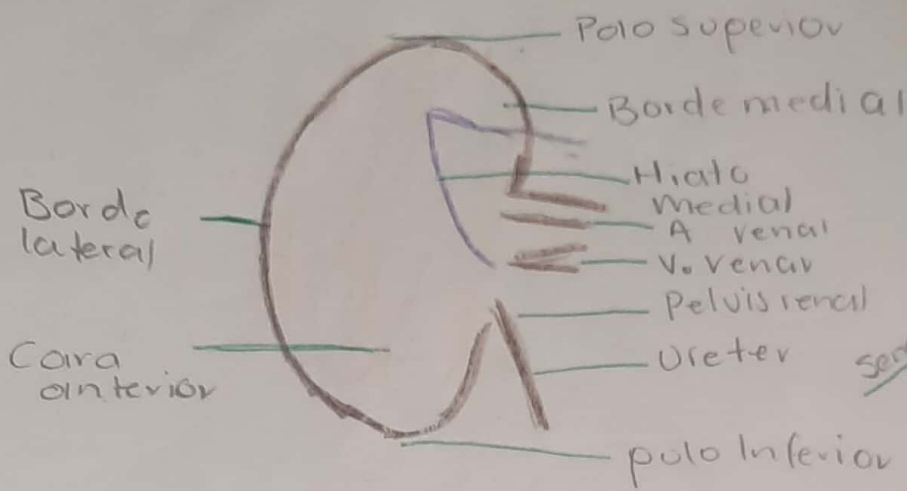
g.Y.P.M.S

Conductos biliares y vesícula biliar



Riñones

Eliminan la Sangre, el exceso de agua, sales y desecho del metabolismo



Irrigación, Inervación y Drenaje.

Nodulo Linfatico
Ispicos (Comunes)

