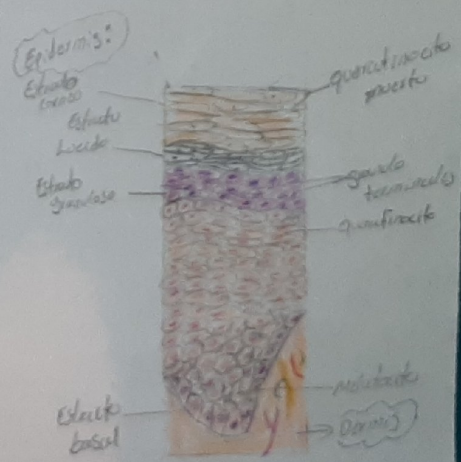
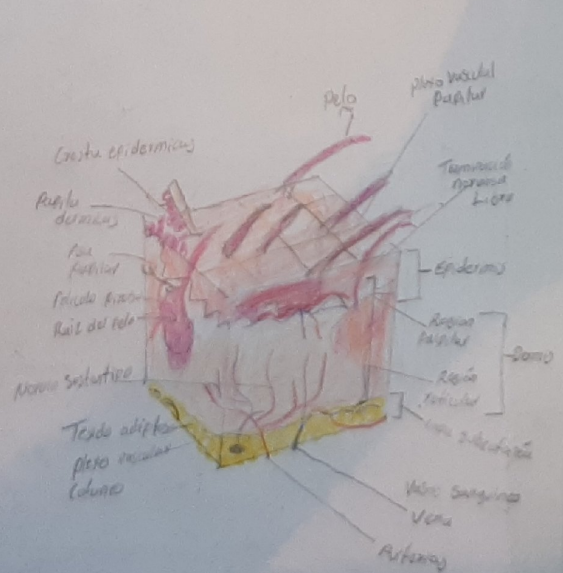
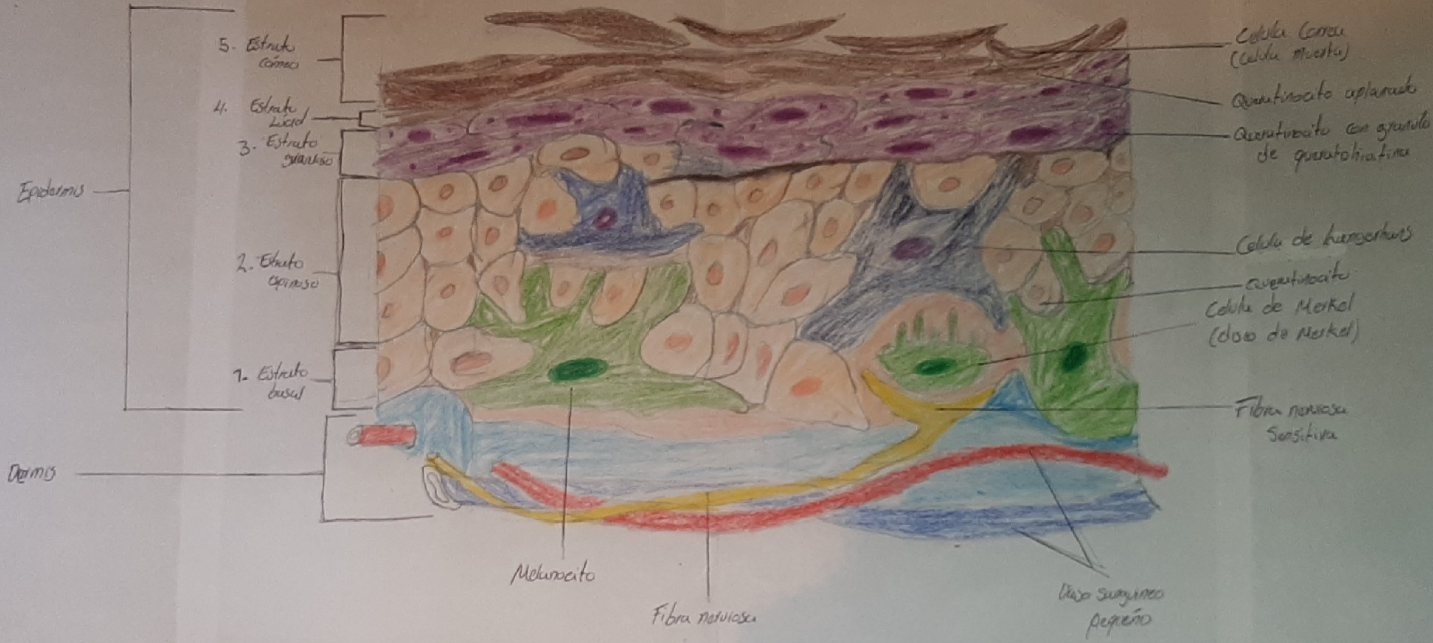
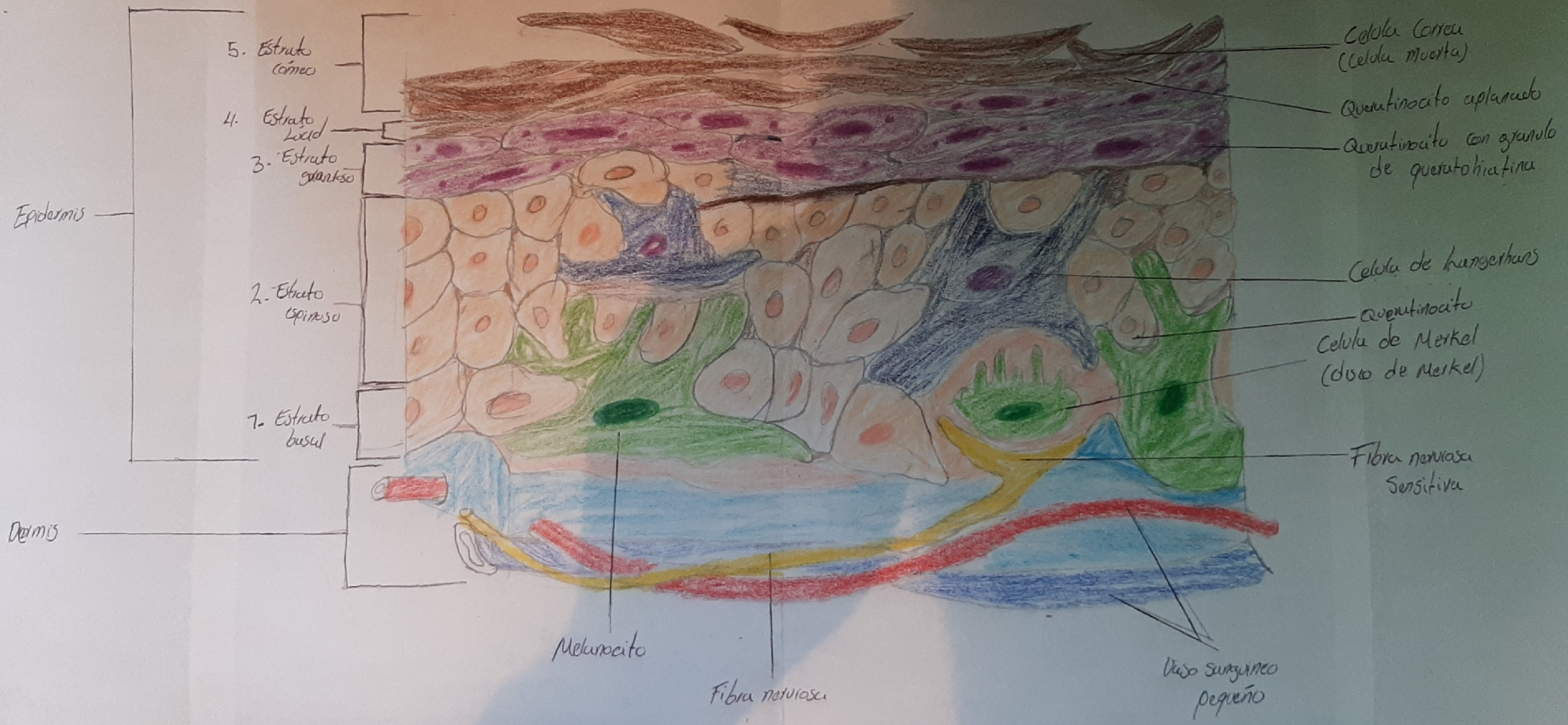


Esquema de epitelio de la piel

Josue Vazquez A.B

15 de Octubre 21





5. Estrato córneo

4. Estrato Lucid

3. Estrato granoso

2. Estrato Espinoso

1. Estrato basal

Epidermis

Dermis

Célula córnea (Célula muerta)

Queratinocito aplanado

Queratinocito con granulo de queratohialina

Célula de hemidesmosmos

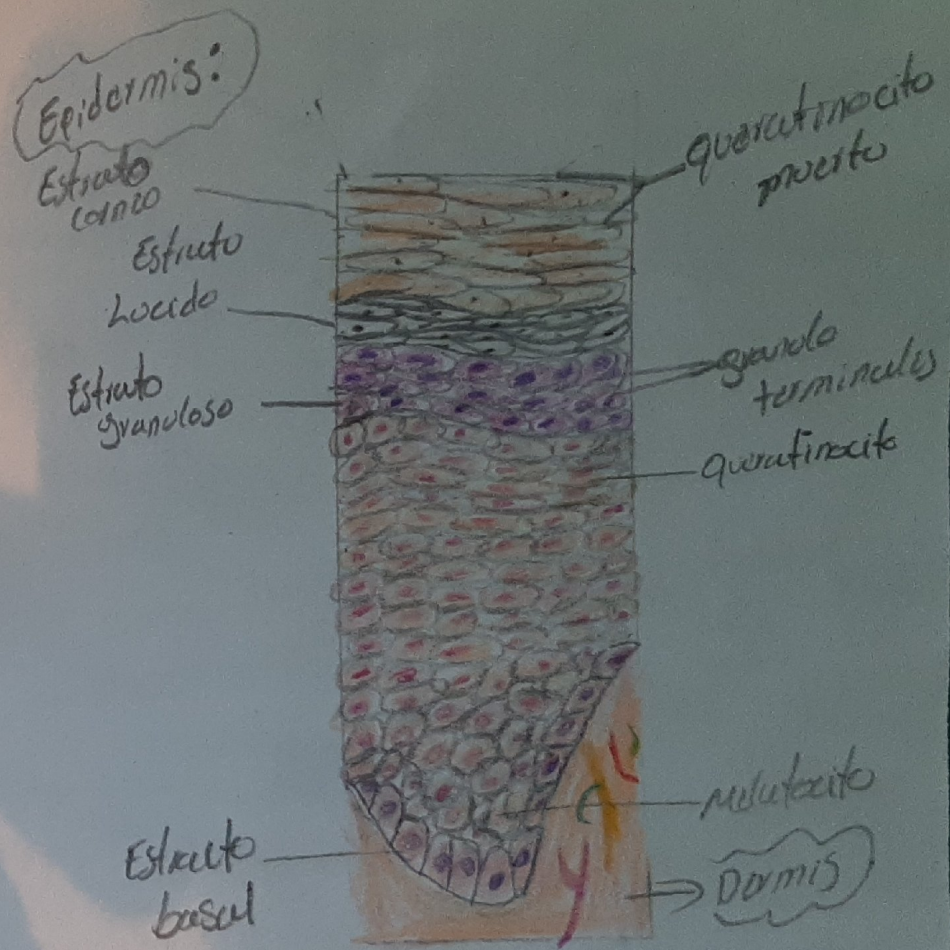
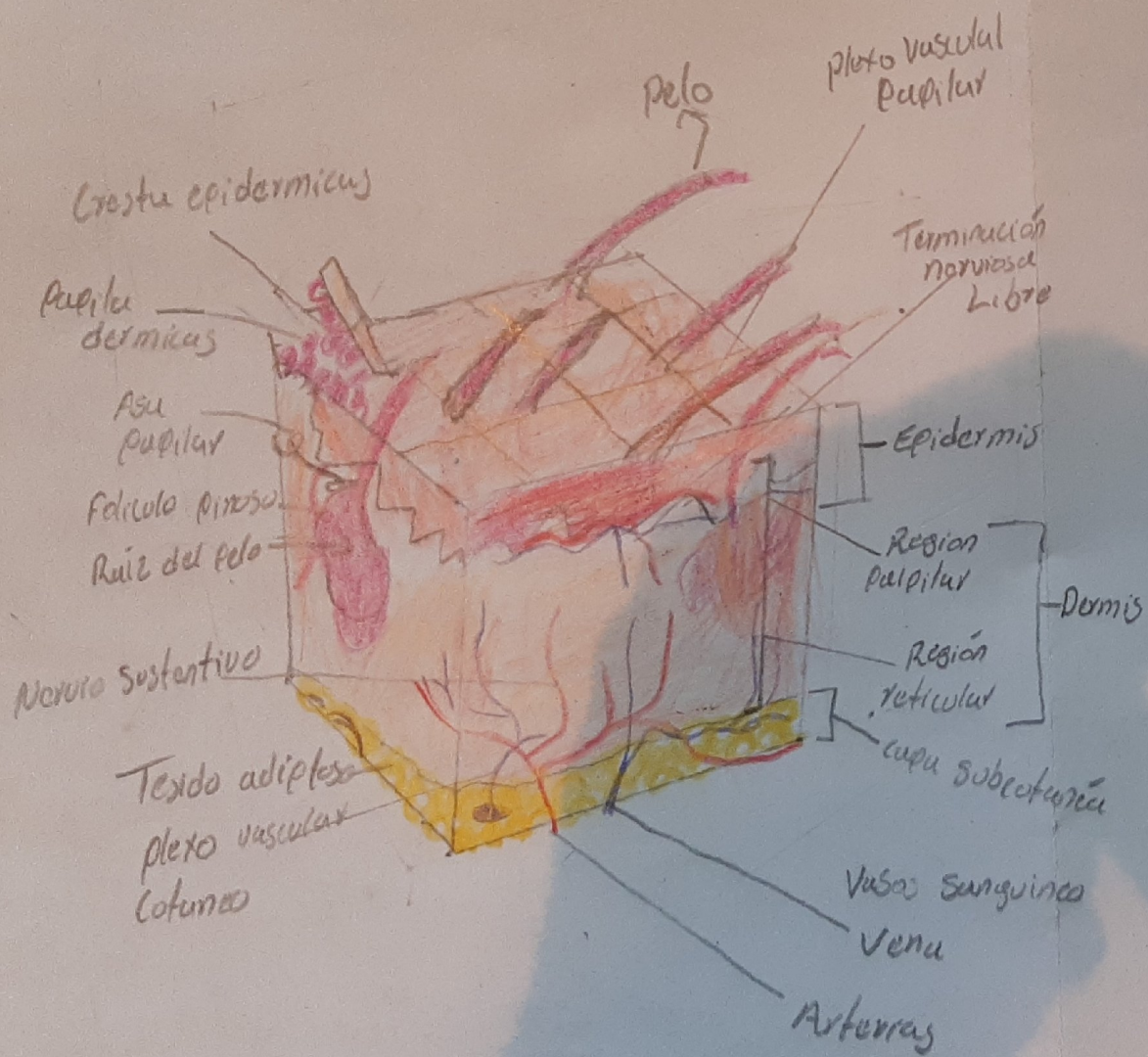
Queratinocito Célula de Merkel (dorso de Merkel)

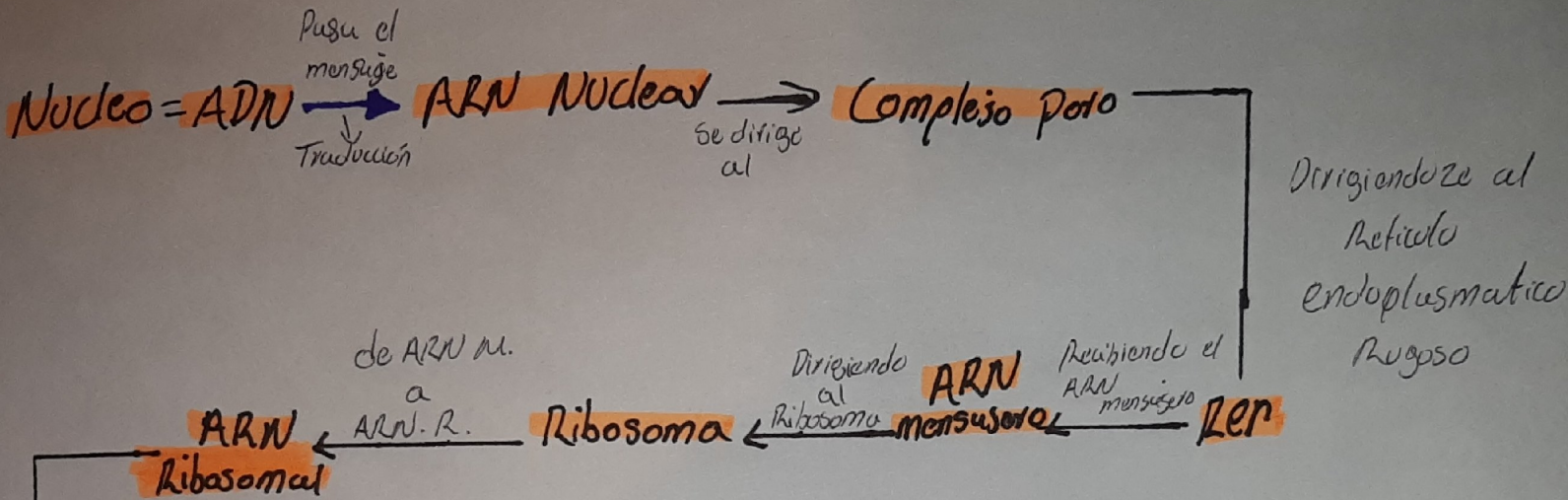
Fibra nerviosa Sensitiva

Melanocito

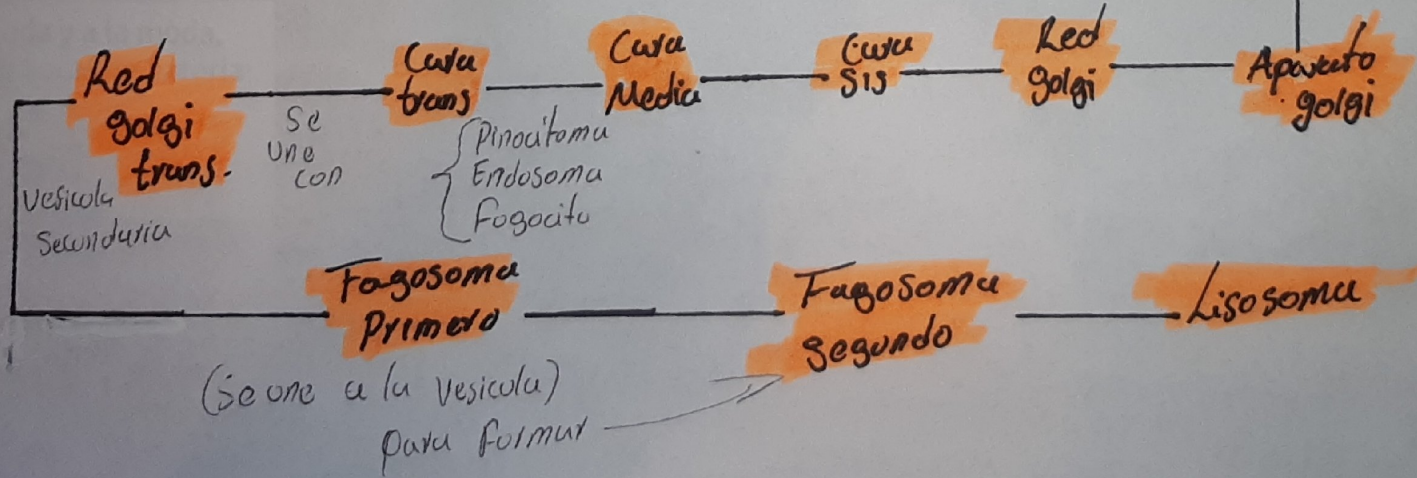
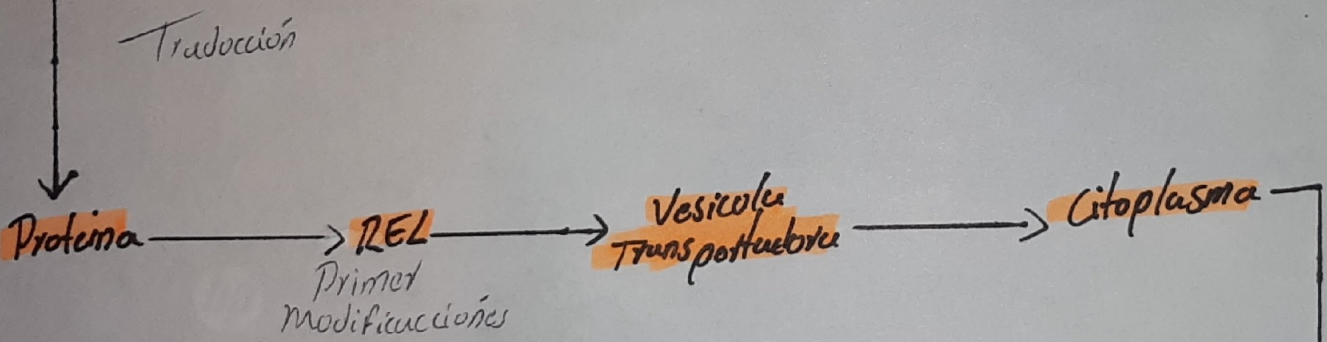
Fibra nerviosa

Vaso sanguíneo pequeño





Ciclo de vida



Josue Vaizquez
1B
15 de oct.

Epitelio...

