

Nombre del Alumno: Luis Antonio Meza
Puon

Nombre del Profesor: Darío Cristiaderit
Gutiérrez Gómez

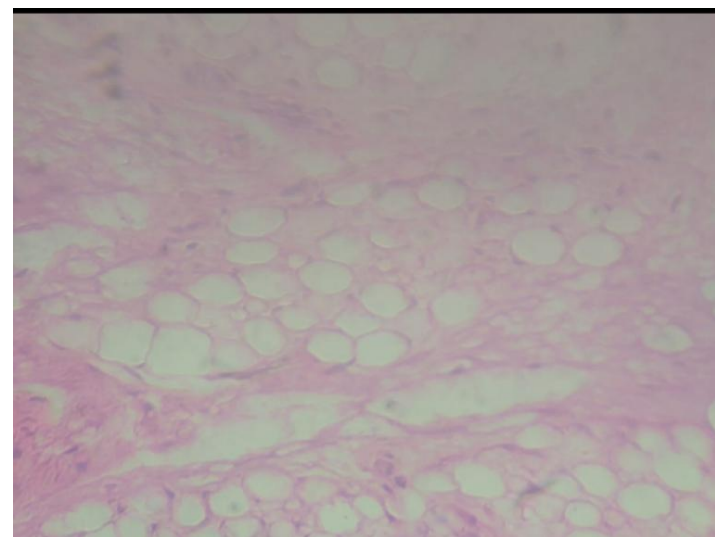
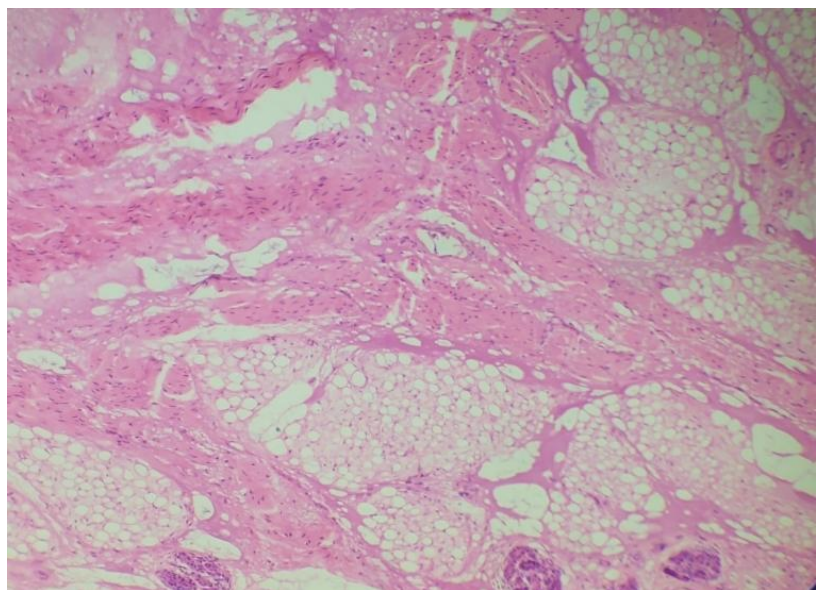
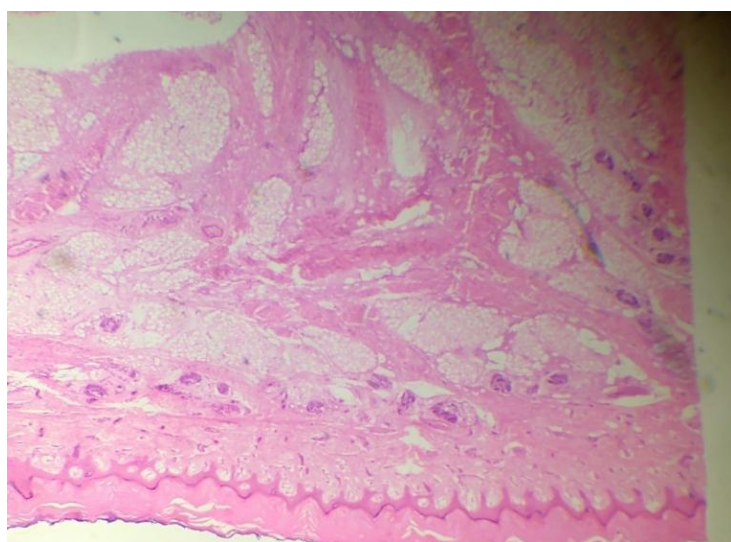
Nombre del Trabajo: Practica Muestras de
Diferentes Tejidos

Materia: Microanatomía

Grado: 1º

Grupo: A

Equipo: 3



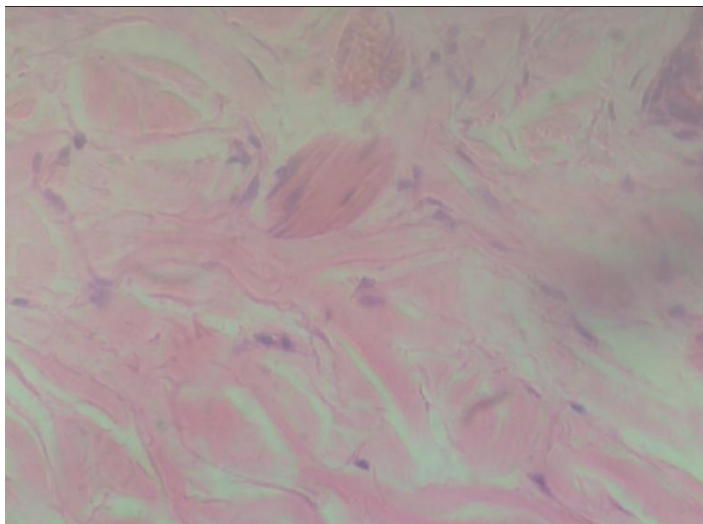
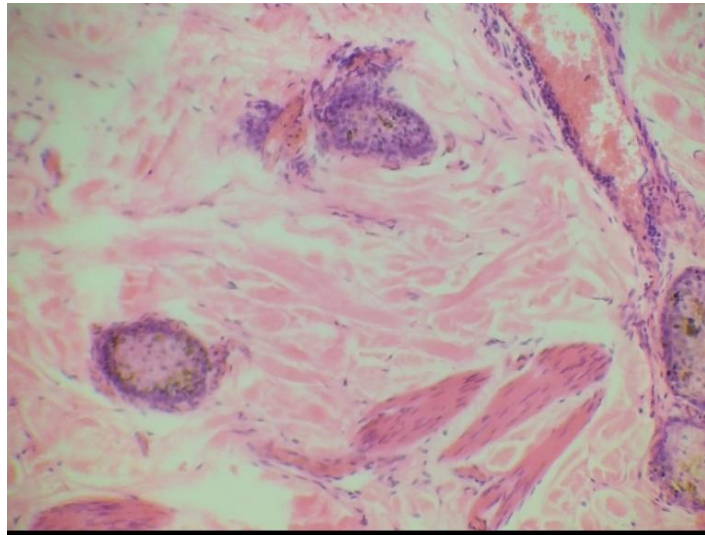
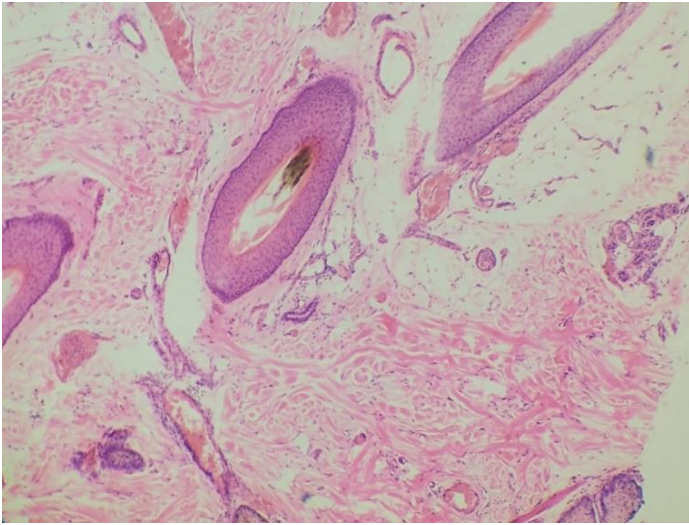
4987 • n° 1

Pelle avec glandes
 follicules pileux
 mit Schweißdrüsen
 ein

- Skin from axillary showing sweat glands, hair follicles
- Кожа подмышечной впадины с потовыми железами и волосяными фолликулами



- Δέρμα από μασχालιαίους αδένες και τριχοθυλάκια
- Pele do sovaco com glândulas sudoríferas e folículos pilíferos
- Piel de la axila con glándulas sudoríparas y folículos pilosos
- Pelle dell'ascella con ghiandole sudoripare e follicoli piliferi




#4987 • n° 2

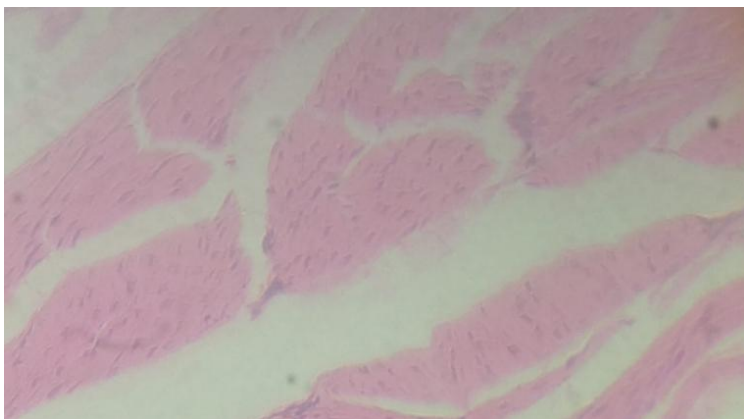
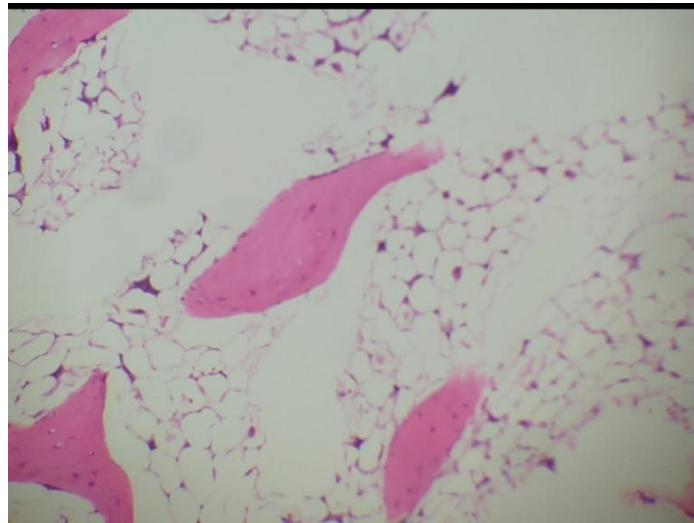
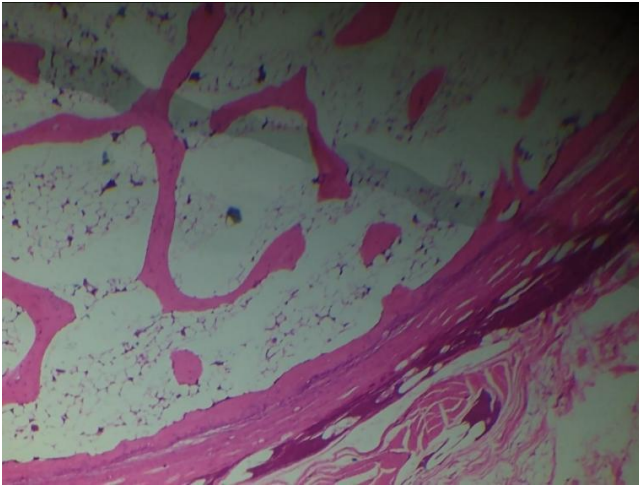
cu avec follicule
des sébacées
mit Haarfollikeln

una targarusen

- Scalp showing hair follicles and sebaceous glands
- Волосистая часть кожи головы с волосяными фолликулами и сальными железами

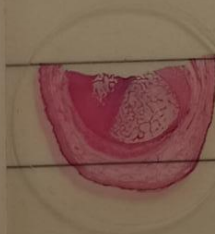

- Δέρμα κεφαλής με τριχοθυλάκια και σμηγματογόνους αδένες
- Couro cabeludo com folículos pilíferos e glândulas sebáceas
- Cuero cabelludo con folículos pilosos y glândulas sebáceas
- Cuoio capelluto con follicoli piliferi e ghiandole sebacee

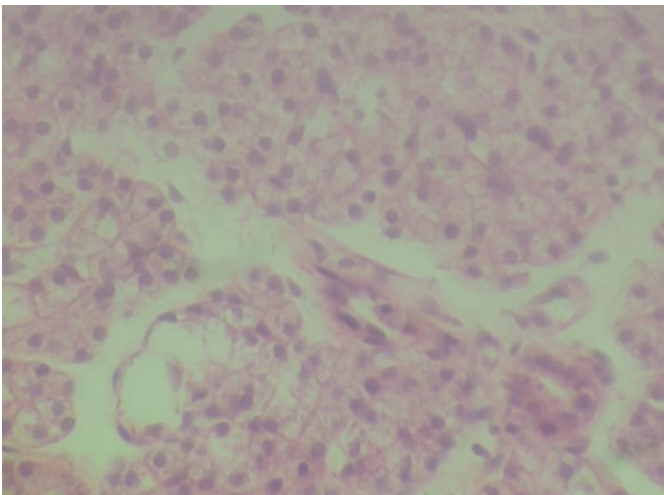
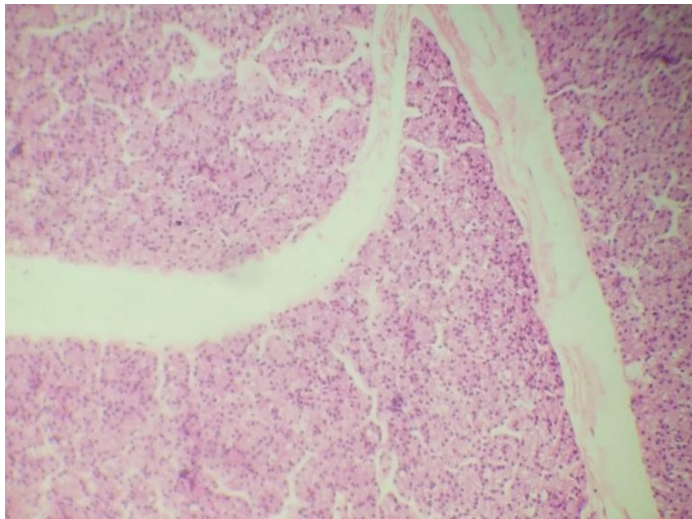
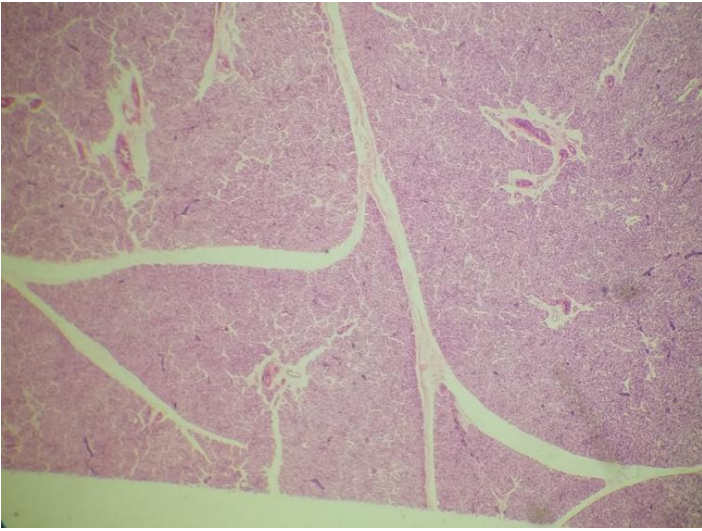


KONUS #4987 • n° 3

- *Ongle, s.t. du lit unguéale*
- *Fingernagel, Qs. durch das Nagelbett*
- *Finger nail, XS finger through the nail bed*
- *Ноготь, попереч. р-р ногтевого ложа*



- *Νύχι, Εγ.Τ. της κοίτης νυχιού*
- *Unha, s.t. do leito ungueal*
- *Uña, s.t. del lecho ungueal*
- *Unghia, s.t. del letto ungueale*

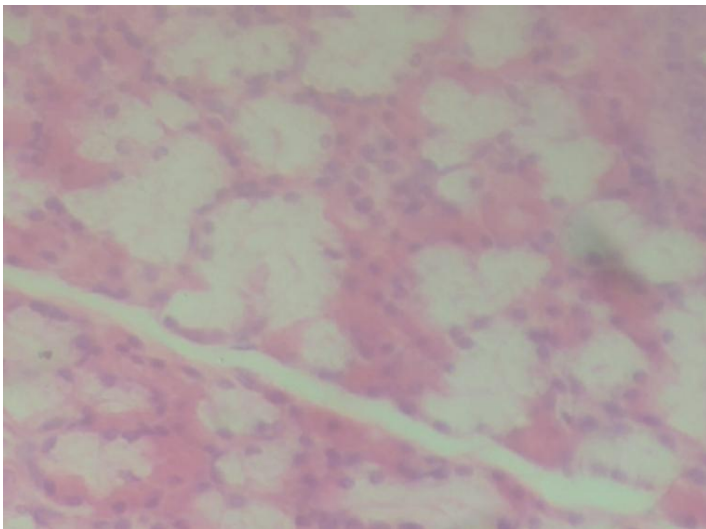
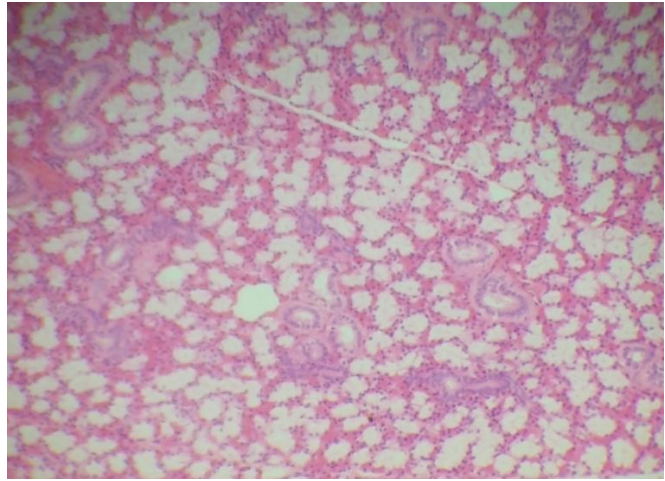
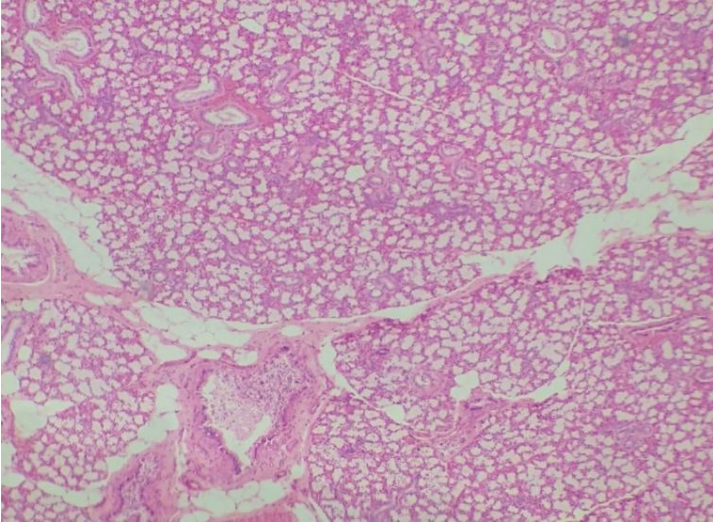


987 • n° 4

- *Glande parotide, glande séreuse pure*
- *Ohrspeicheldrüse, reine Speicheldrüse*
- *Parotid gland, a purely serous gland*
- *Околоушная железа, серозная железа*



- *Αδένας παρωτίδας, καθαρός ορογόνος αδένας*
- *Glândula parótida, glândula serosa pura*
- *Glándula parotida, glándula serosa pura*
- *Ghiandola parotide, ghiandola sierosa pura*

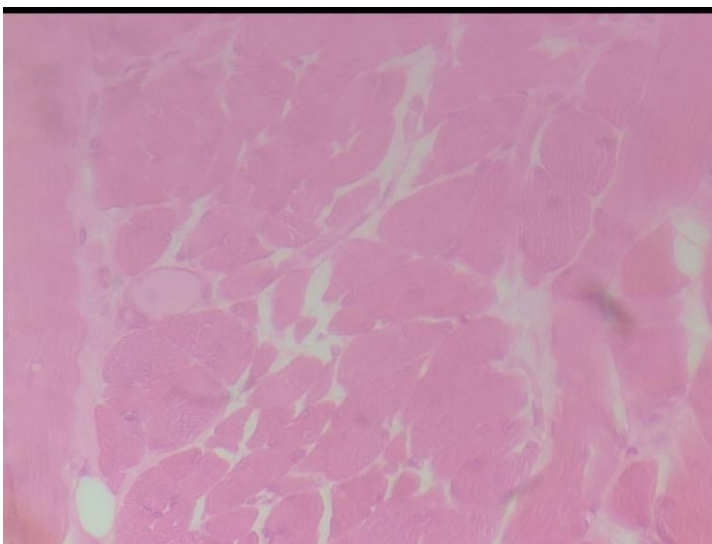
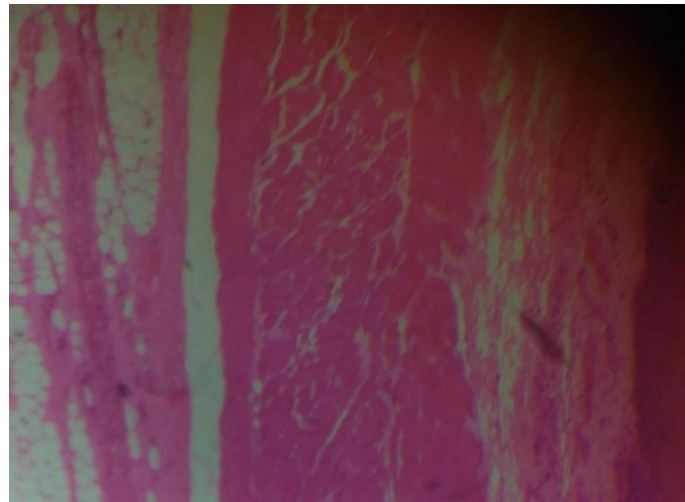
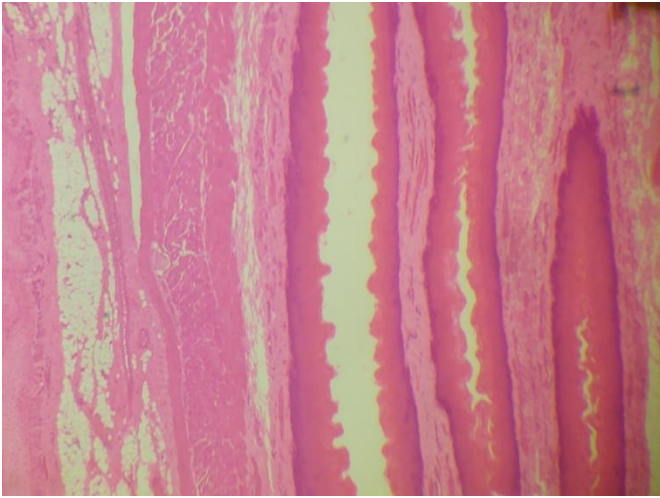


S #4987 • n° 5

- Glande sublinguale, glande séro-muqueuse
- Unterzungenspeicheldrüse, gemischte Drüse
- Sublingual gland, a mixed gland
- Подъязычная смешанная слюнная железа



- Υπογλώσσιος αδέννας, μικτός αδέννας
- Glândula sublingual, glândula mista
- Glândula sublingual, glândula mixta
- Ghiandola sottolinguale, ghiandola mista

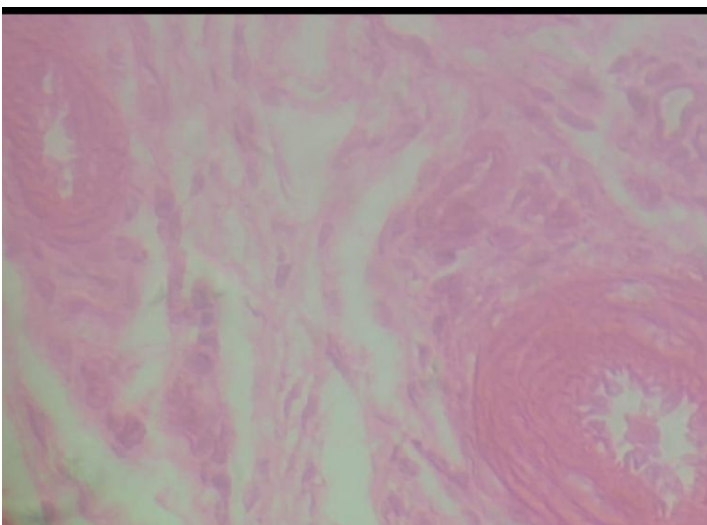
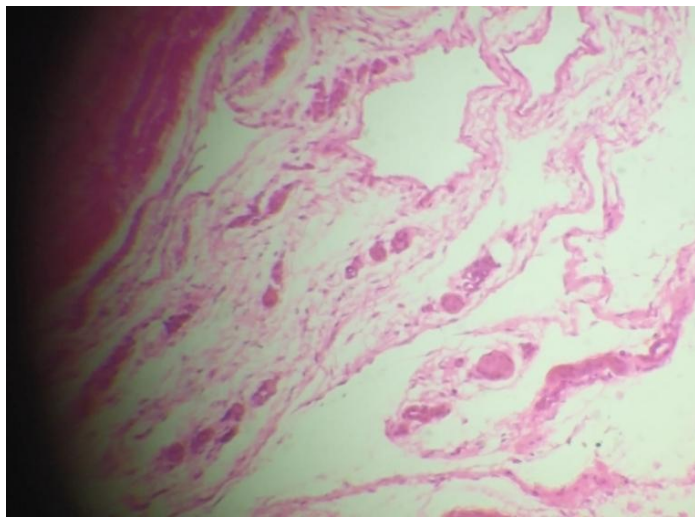
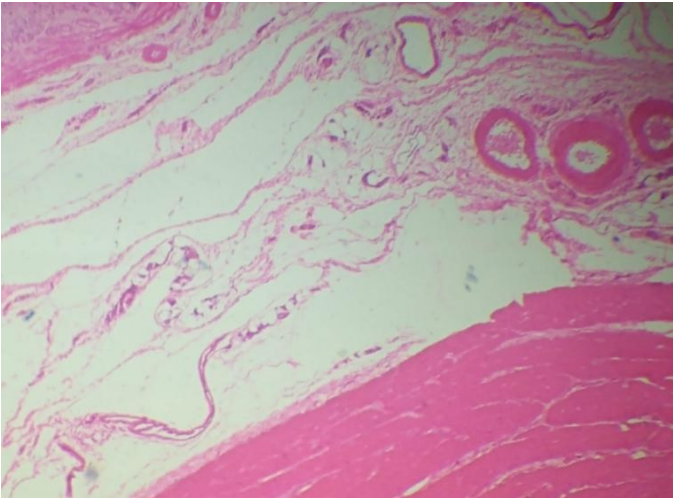


#4987 • n° 6

- Oesophago et trachée, s.l. des deux organes
- Speiseröhre und Luftröhre, Ls. beider Organe
- Esophagus and trachea, LS of both organs
- Пищевод и трахея, продольн. р-р



- Οισοφάγος και τραχεία, Εγ.Τ. και των δύο οργάνων
- Esófago e traqueia, s.l. dos dois órgãos
- Esófago y traquea, s.l. de ambos órganos
- Esofago e trachea, LS di ambedue gli organi

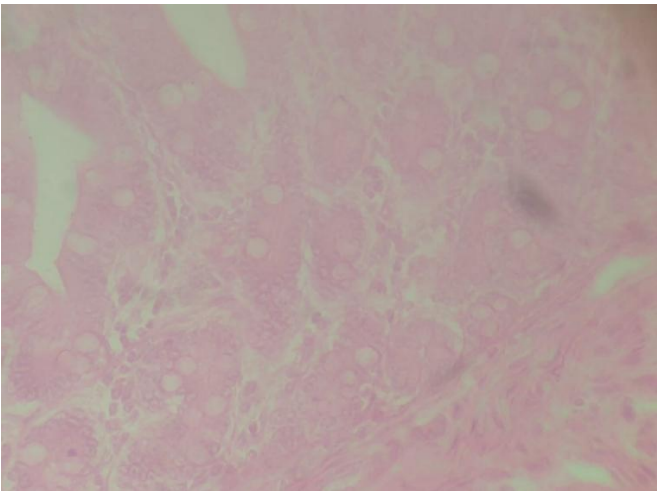
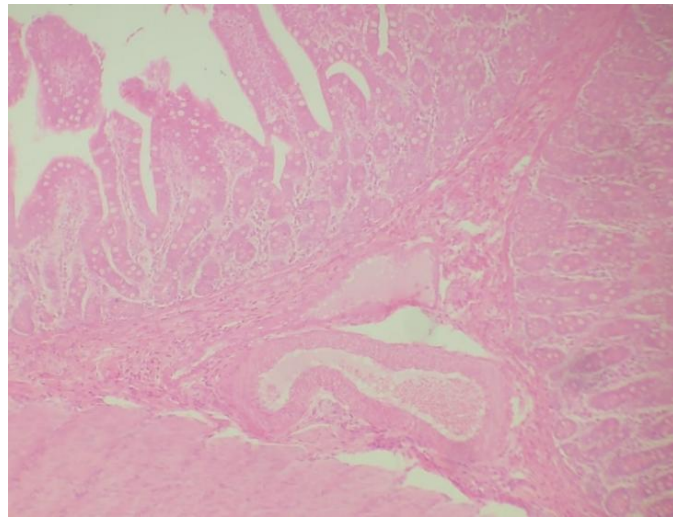
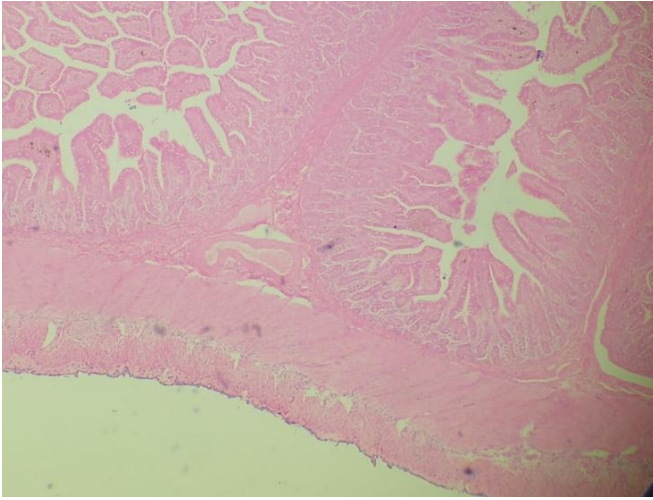


1987 • n° 7
estomac

- Magenwand
- Gastric wall
- Стенка желудка



- Τοίχωμα στομάχου
- Parede do estômago
- Pared del estómago
- Parete dello stomaco

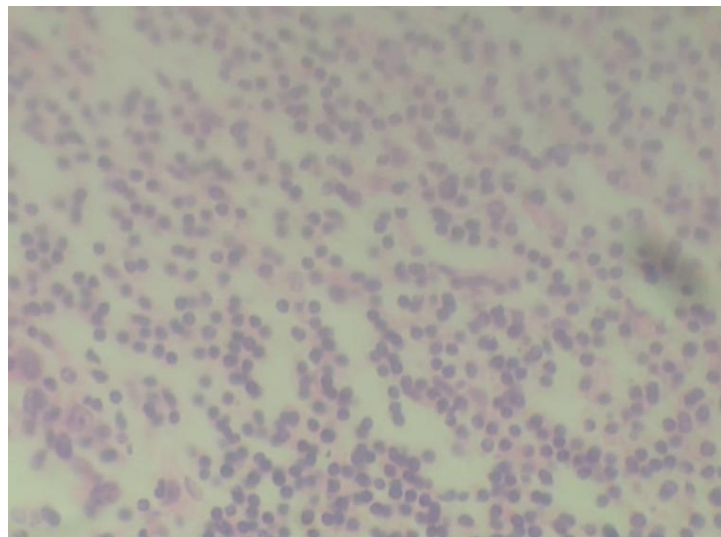
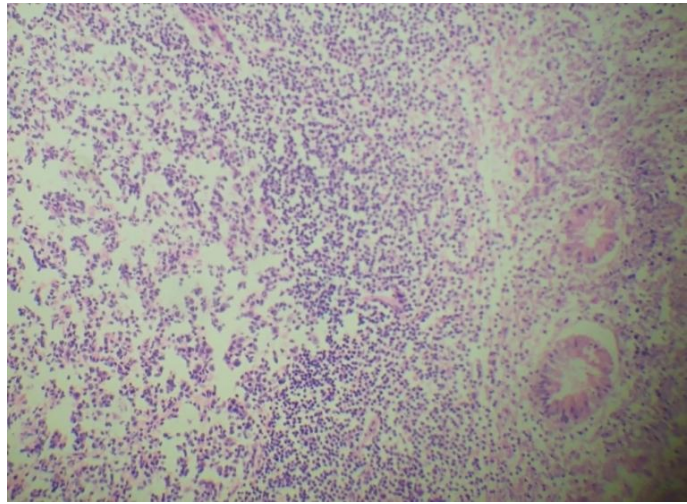
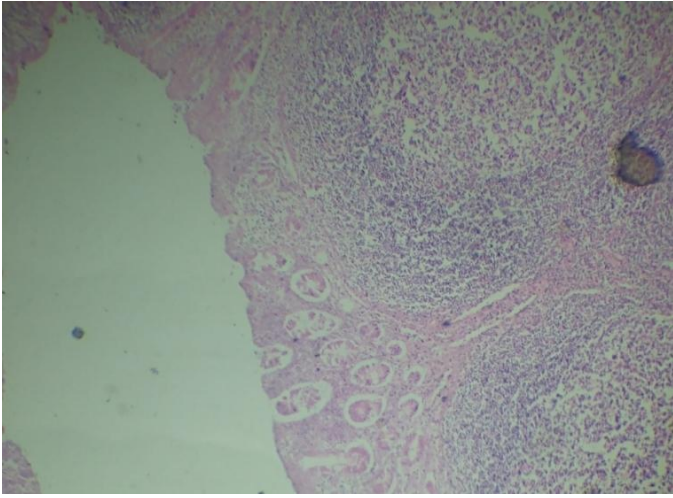


#4987 • n° 8

- Darm
- Intestine
- Кишка



- Έντερο
- Intestino
- Intestino
- Intestino



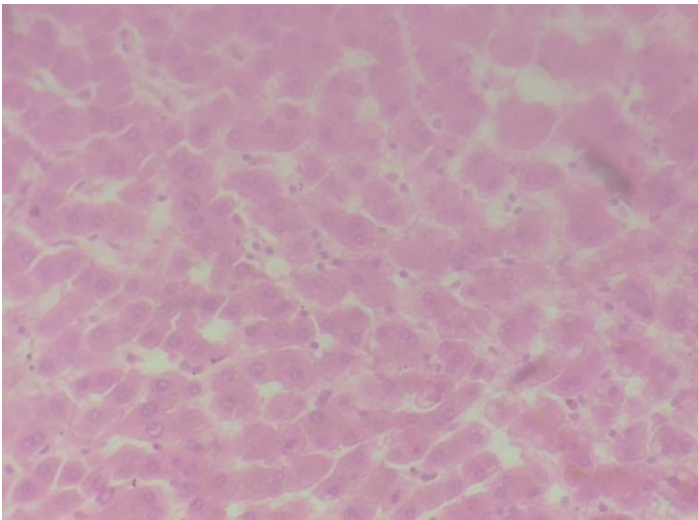
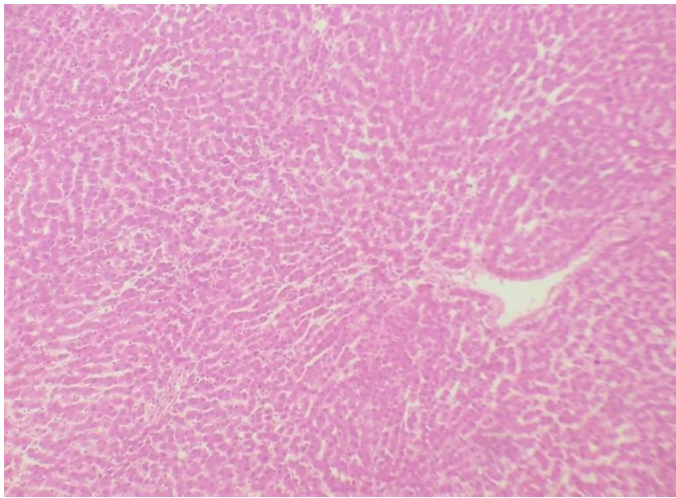
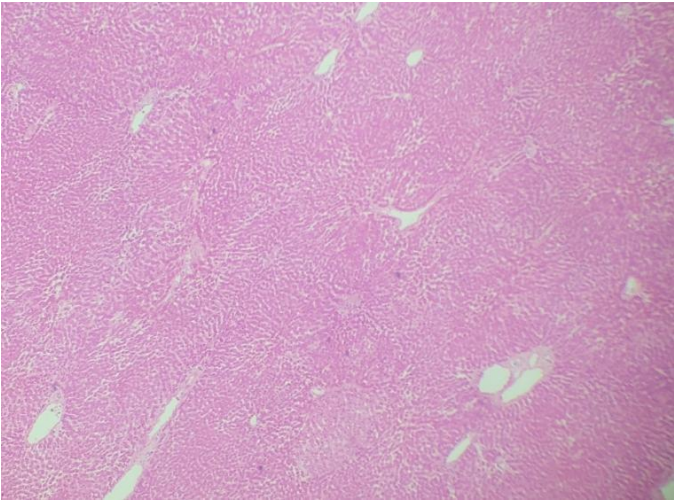
987 • n° 9
 léo-caecal,

Qs.

- Appendix, XS
- Червеобразный отросток, попереч. р-р




- Ειλεοτυφλική απόφυση, Εγ.Τ.
- Apêndice ileo-cecal, s.t.
- Apêndice ileocecal, s.t.
- Appendice ileo-cecale, s.t.

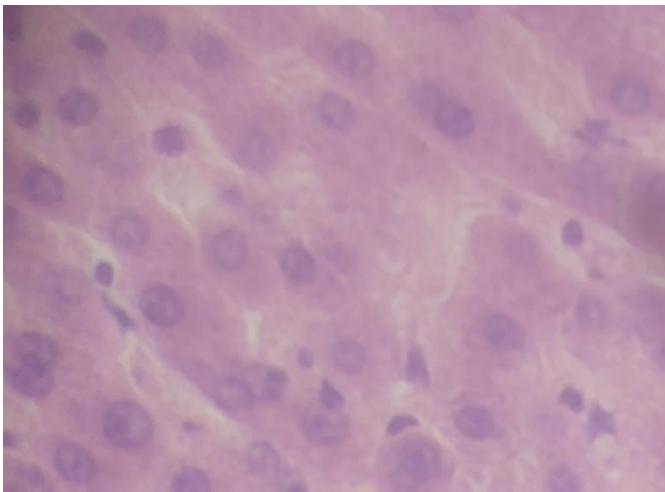
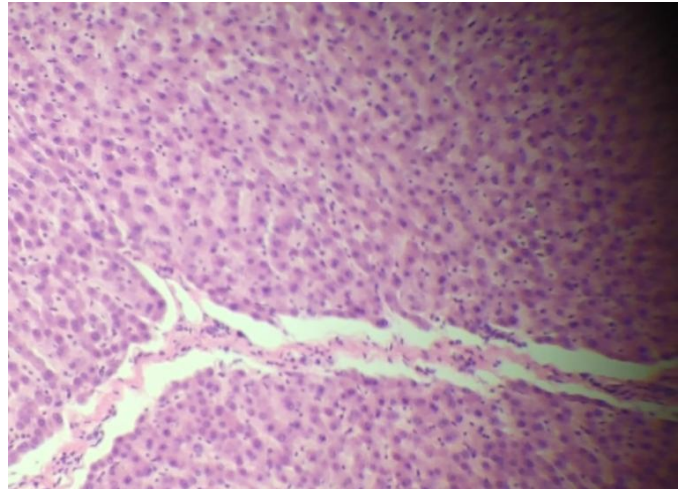
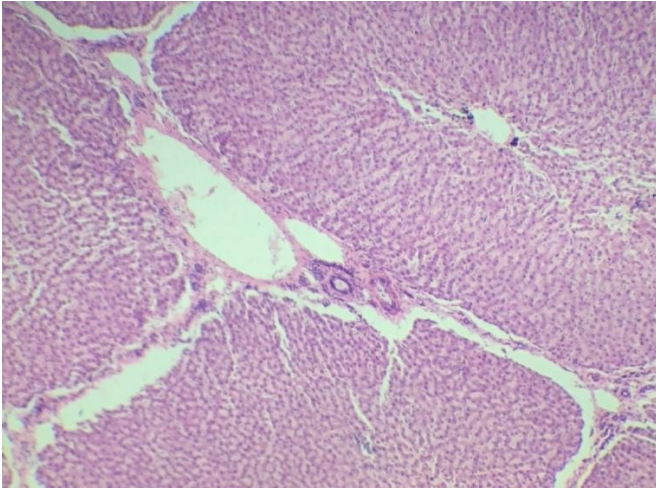


4987 • n° 10

- Leber
- Liver
- Печень




- Ήπαρ
- Fígado
- Hígado
- Fegato



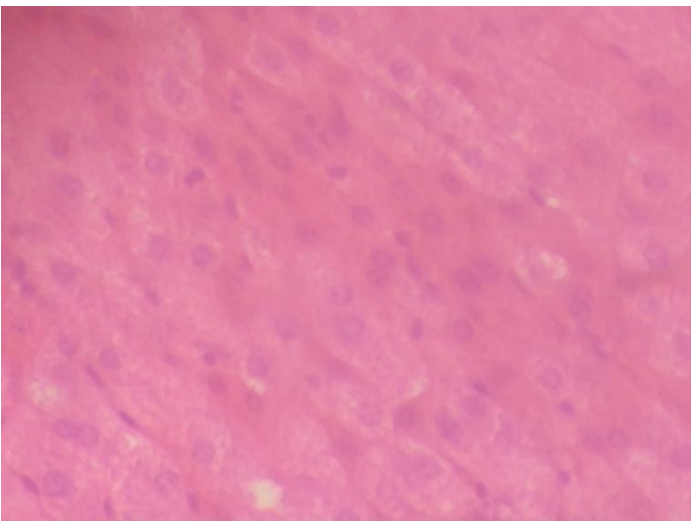
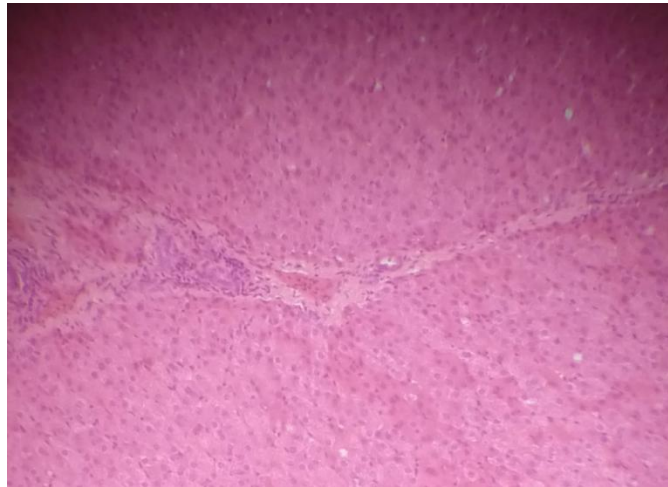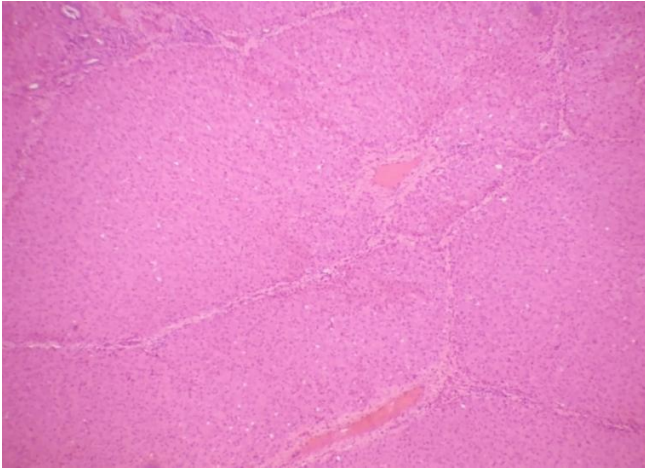
1987 • n° 11

avec lobules
entourés de connectif

- Schweineleber mit Läppchen (Lobuli) umgeben von Bindegewebe
- Liver, pig fibrous trabeculae between lobules
- Доли свиной печени, окруженные соединительной тканью




- Ήπαρ χοίρου με λοβία που περιβάλλονται με συνδετικό
- Fígado de porco com lóbulos circundados de conjuntivo
- Hígado de cerdo con lóbulos circundados de conectivo
- Fegato di maiale con lobuli circondati da connettivo

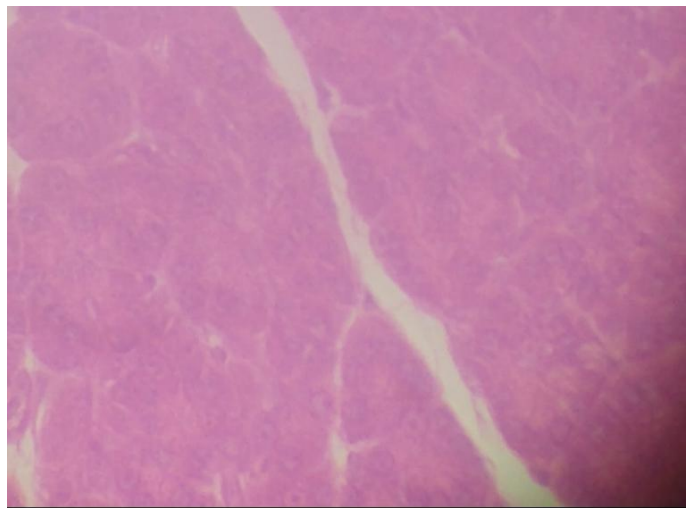
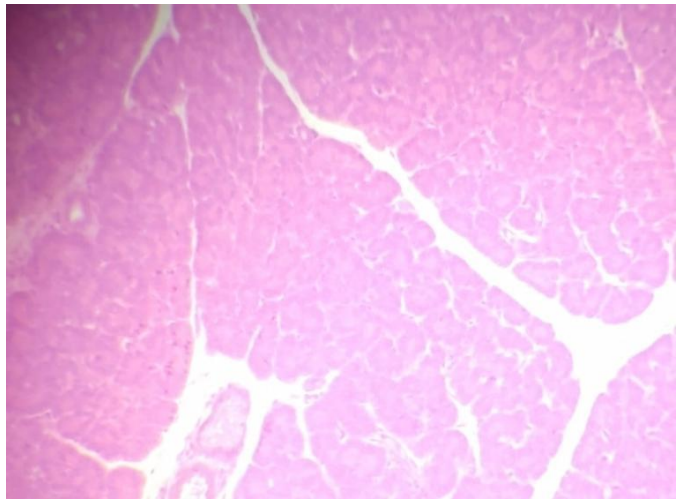
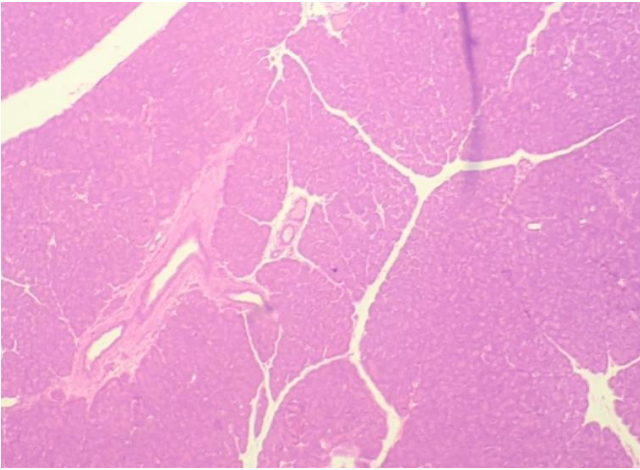


87 • n° 12
aire

- *Gallenblase*
- *Gall bladder*
- *Жёлчный пузырь*

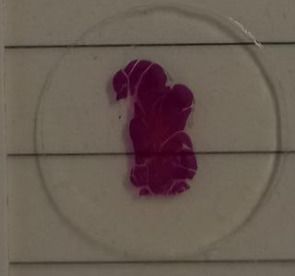

- *Χοληδόχος κύστη*
- *Vesícula*
- *Vesícula biliar*
- *Cistifellea*

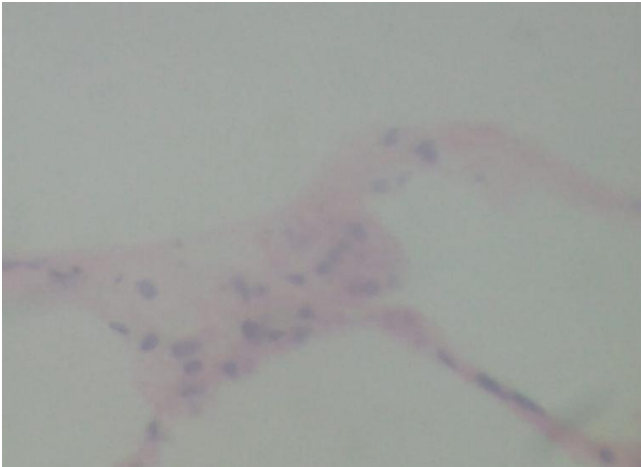
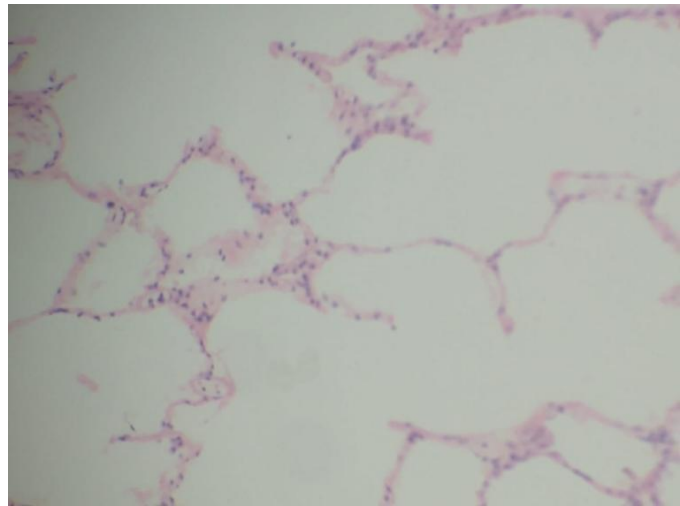
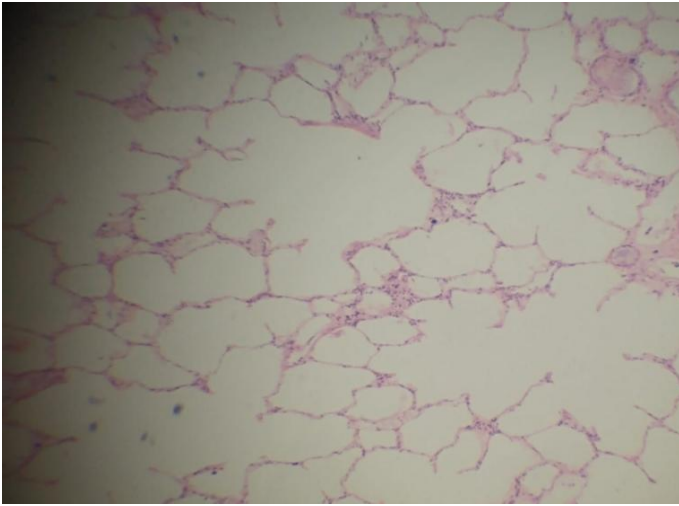


987 • n° 13

- *Pancreas, secreting acini and island of Langerhans*
- *Поджелудочная железа, ацинозная часть железы с островками Лангерганса*




- *Πάγκρεας, βοτρυοειδής αδένας με νησίδα Langerhans*
- *Pâncreas, glândula acinosa com ilhotas de Langerhans*
- *Pâncreas, glândula acinosa con islotes de Langerhans*
- *Pancreas, ghiandola acinosa con isolotti di Langerhans*

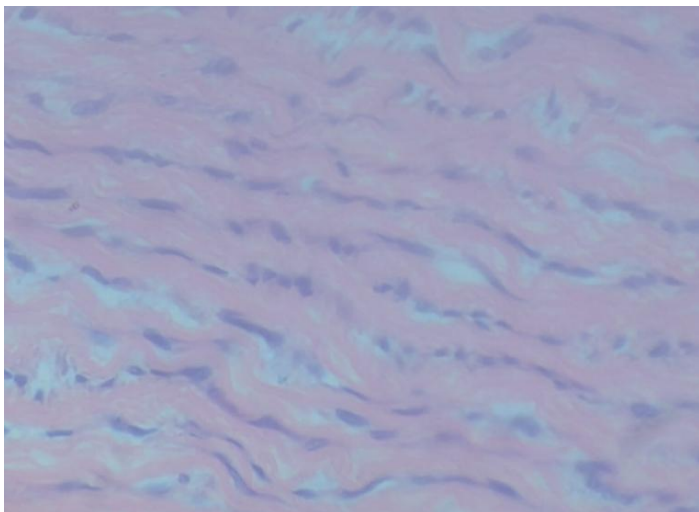
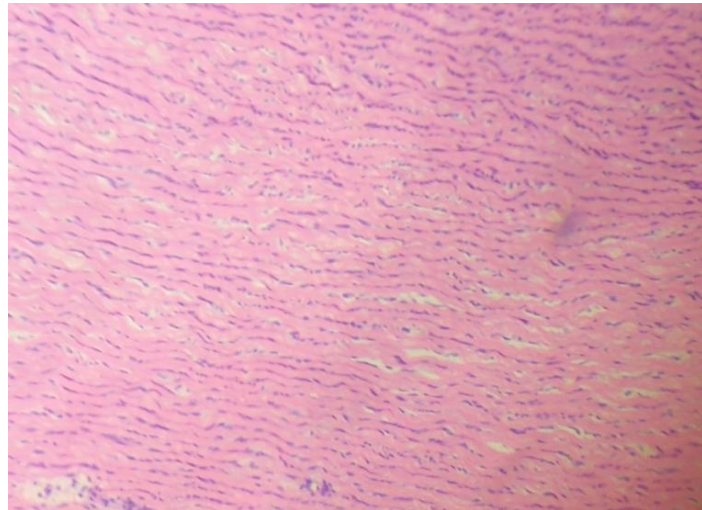
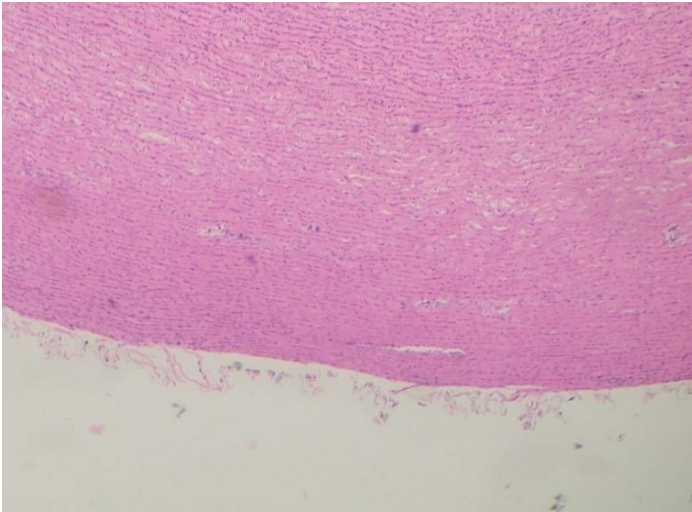


KONUS #4987 • n° 14

- Ρουμον
- Lunge
- Lung
- Легкое



- Πνεύμονας
- Pulmão
- Pulmón
- Polmone

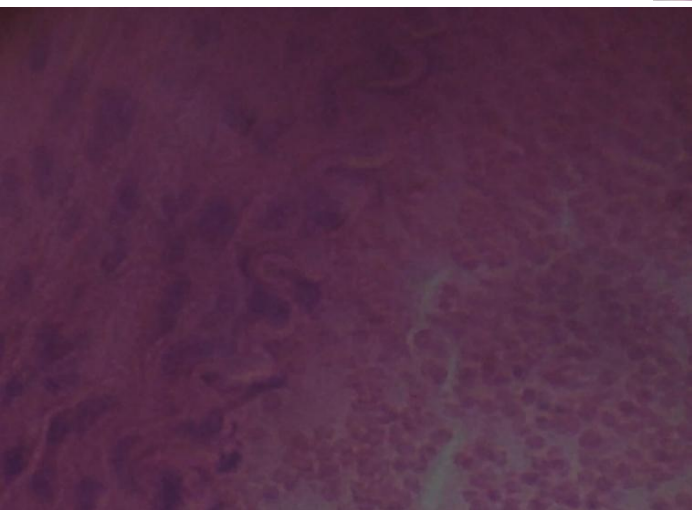
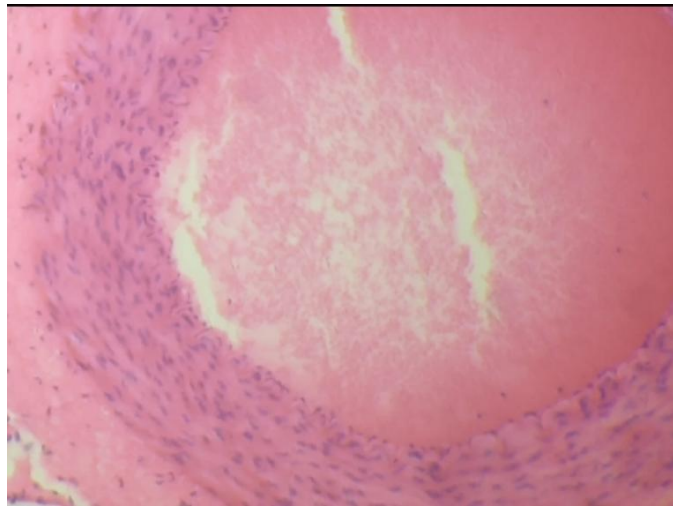
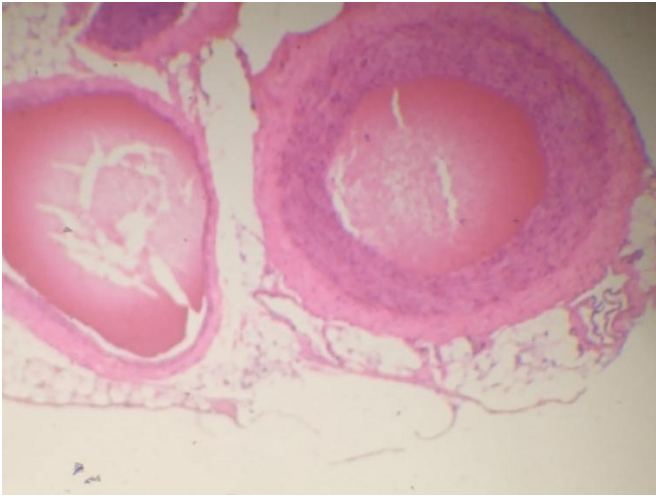


7 • n° 15

- Aorta, s.t., hemato-eosina et coloration pour le tissu élastique
- Aorta, Qs., HE und Elastica - Färbung
- Aorta, XS H&E and elastic tissue stain
- Аорта, попереч. р-р, окрашивание гематоксилин-эозином, эластические волокна



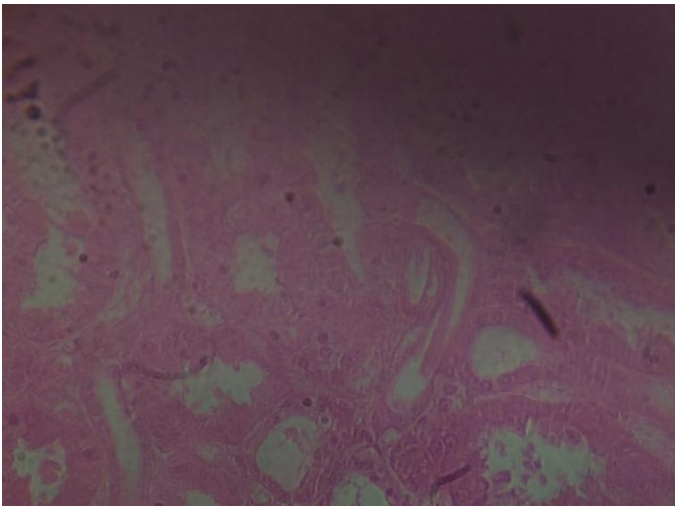
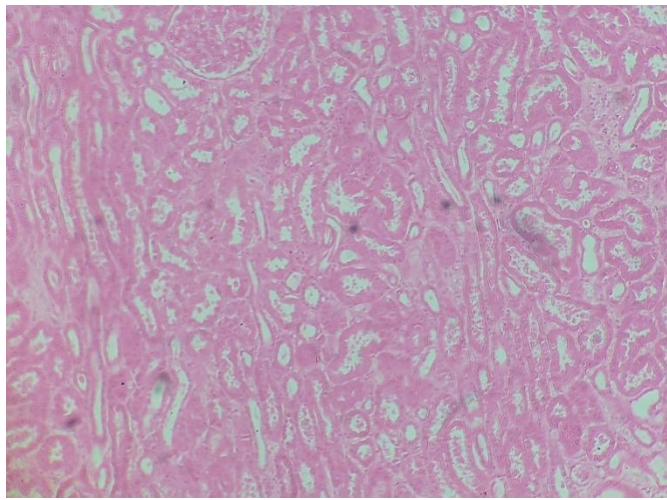
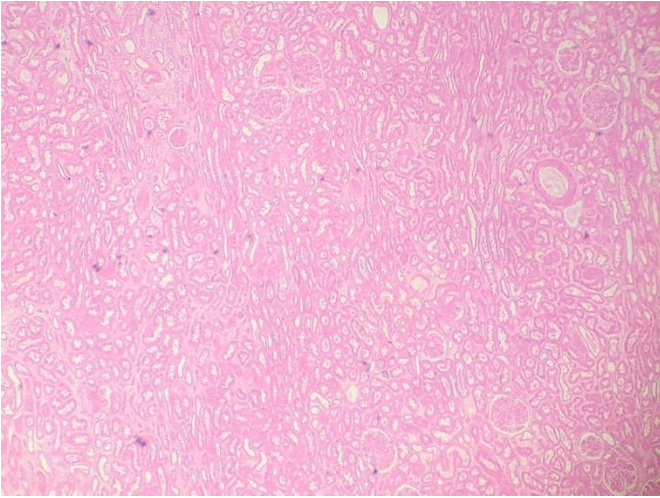
- Αορτή, Εγ.Τ., αιματεΐνη-ηωσίνη και χρώση για τον ελαστικό ιστό
- Aorta, s.t., ematos.eosina e coloração para o tecido elástico
- Aorta, s.t., hemato.eosina y coloración para el tejido elástico
- Aorta, s.t., ematos.eosina e colorazione per il tessuto elastico



4987 • n° 16

- Artere et veine avec coloration pour le tissu élastique
- Artherie und Vene, Elastica - Färbung
- Artery and vein elastic tissue stain
- Артерия и вена, окрашенный препарат с эластическими волокнами

- Αρτηρία και φλέβα με χρώση για τον ελαστικό ιστό
- Artéria e veia com coloração para o tecido elástico
- Arteria y vena con coloración para el tejido elástico
- Arteria e vena con colorazione per il tessuto elastico

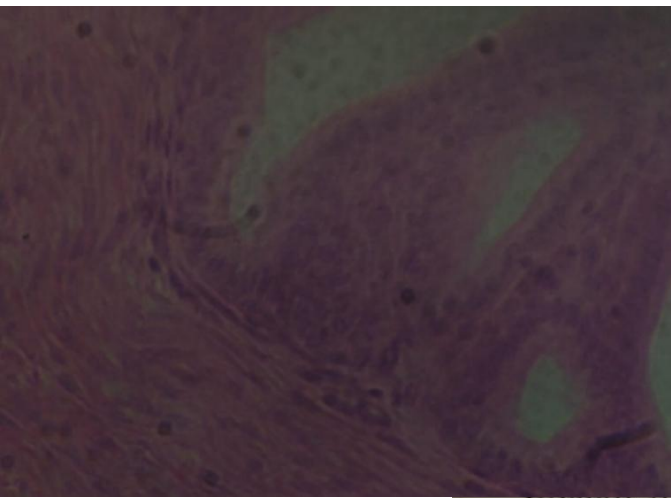
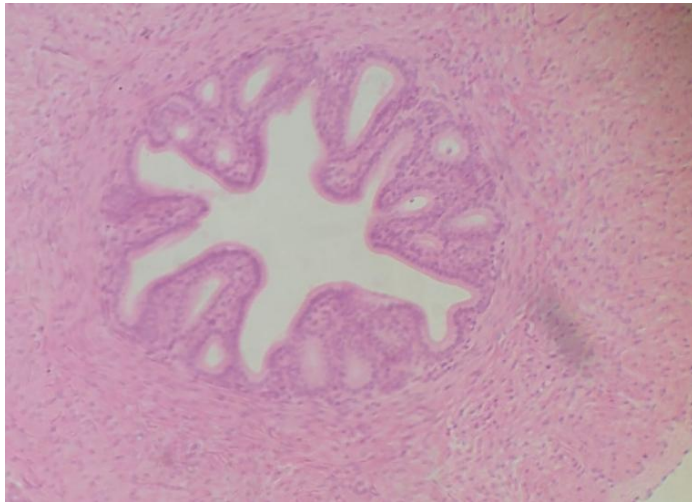
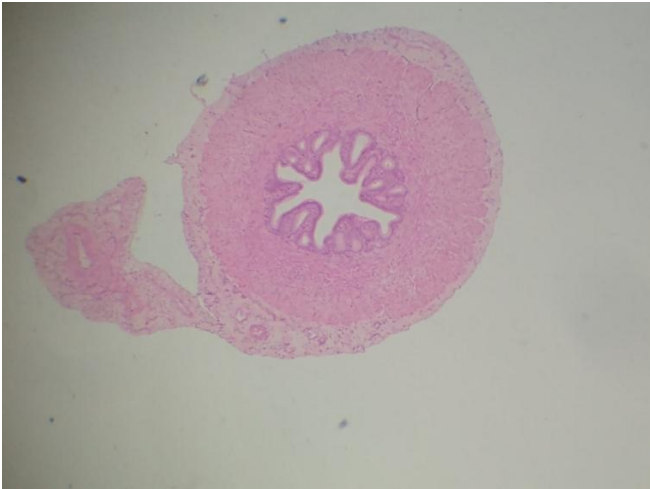


#4987 • n° 17

- Rein, section de la zone corticale
- Niere, Schnitt durch den Rindenbereich
- Kidney, section of cortical zone
- Разрез кортикального отдела почки

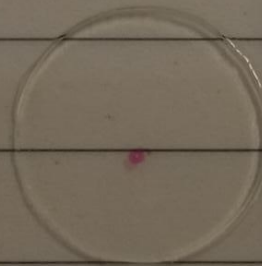

- Τομή νεφρού της ζώνης του φλοιού
- Rim, secção da zona cortical
- Riñón sección de la zona cortical
- Rene sezione della zona corticale


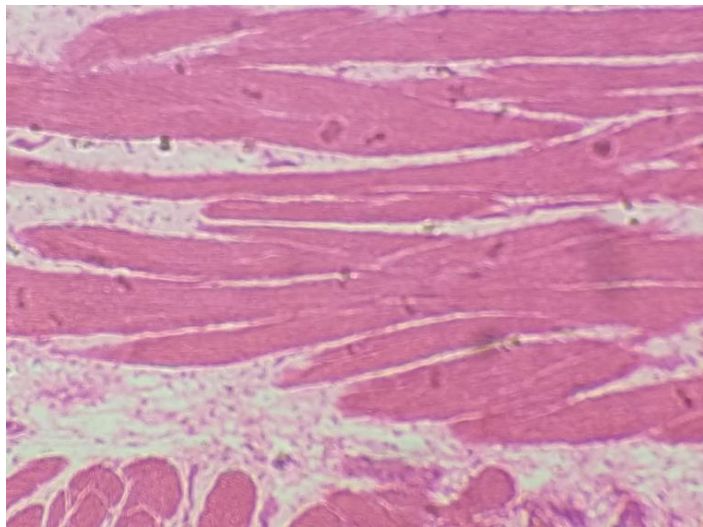
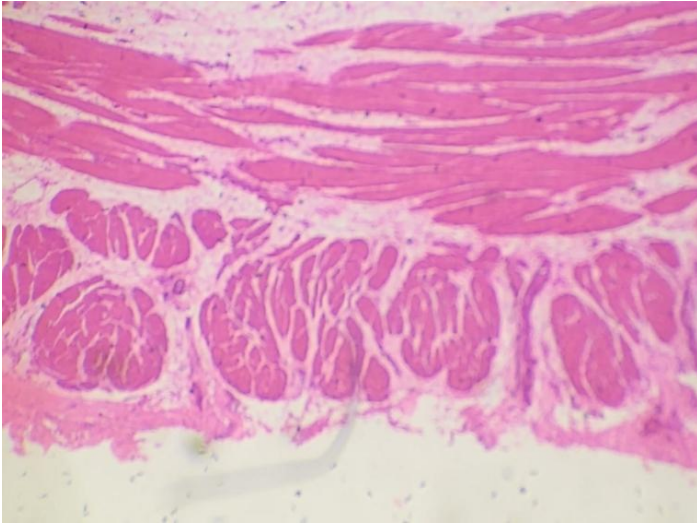


1987 • n° 18

- Uretere, s.t.
- Harnleiter, Qs.
- Ureter XS
- Мочеточник, попереч. р-р



- Ουρήθρα, Εγ.Τ.
- Uréter, s.t.
- Uretra, s.t.
- Uretere, s.t.

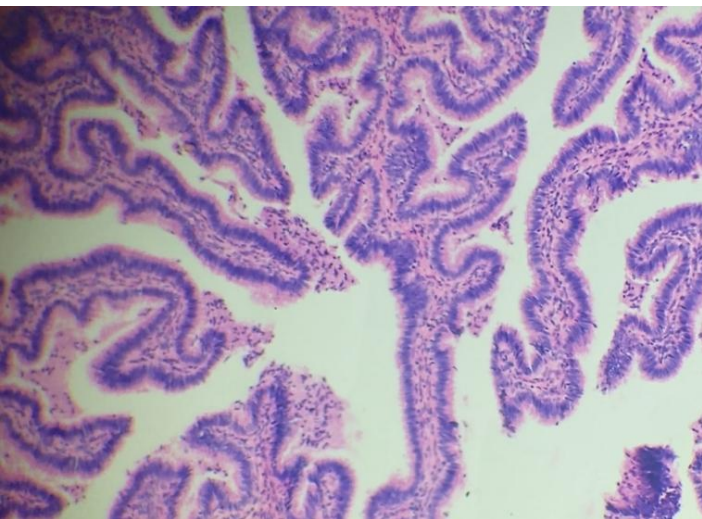
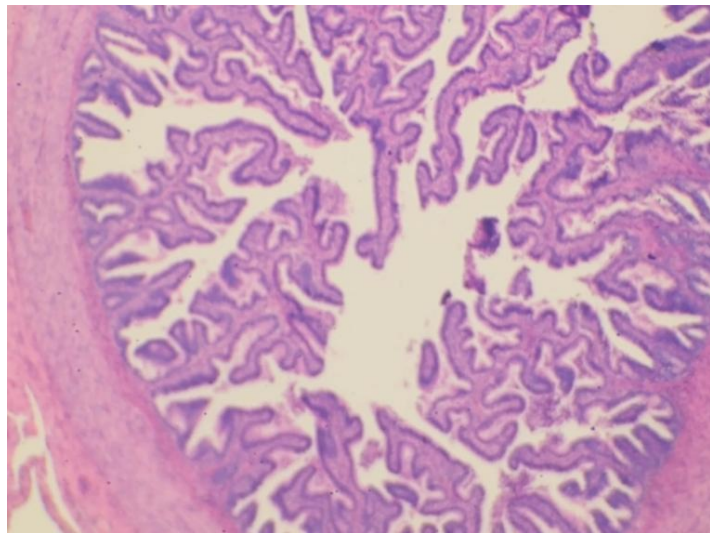
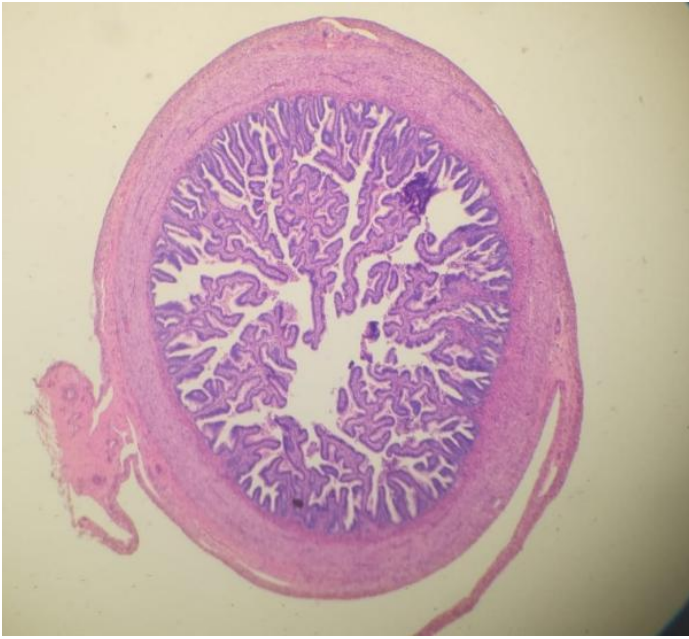

987 • n° 19

- Urinary bladder
- Мочевой пузырь



- Ουροδόχος κύστη
- Bexiga urinária
- Vejiga urinaria
- Vescica urinaria



7 • n° 20

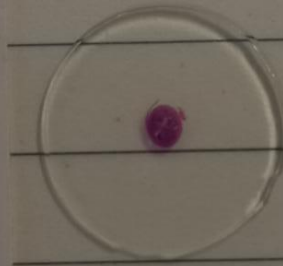ction à tra-

t durch die

Ampulla

• Uterine tube (oviduct), sec. through ampulla

• Разрез ампулярной части яйцевода

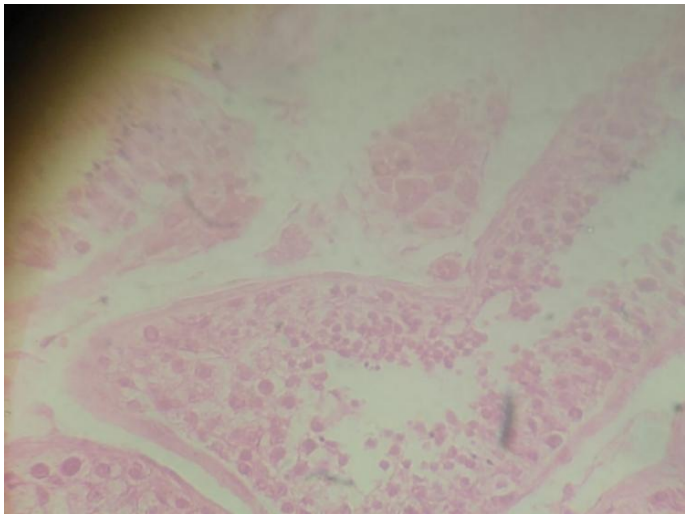
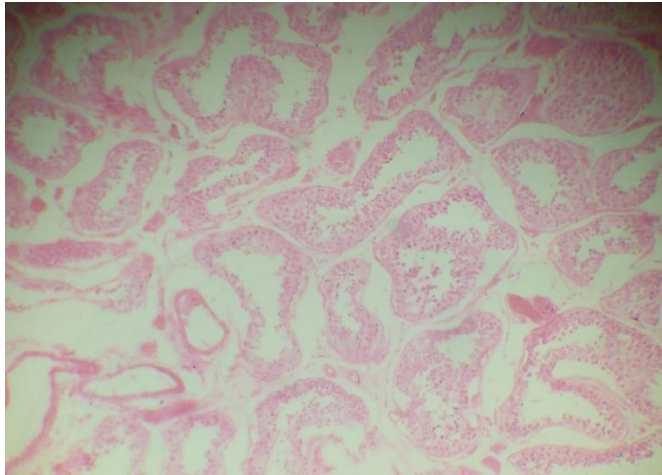
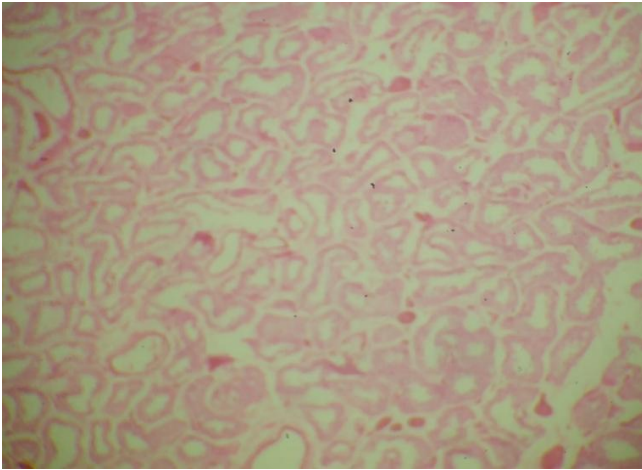


• Κέρασ μήτρασ, τομή μέσω φυσιγγασ

• Tubā uterina, secção através da ampola


• Tubo uterino (trompa de Falopio), sección a través la ampolla

• Tuba uterine, sezione attraverso l'ampolla

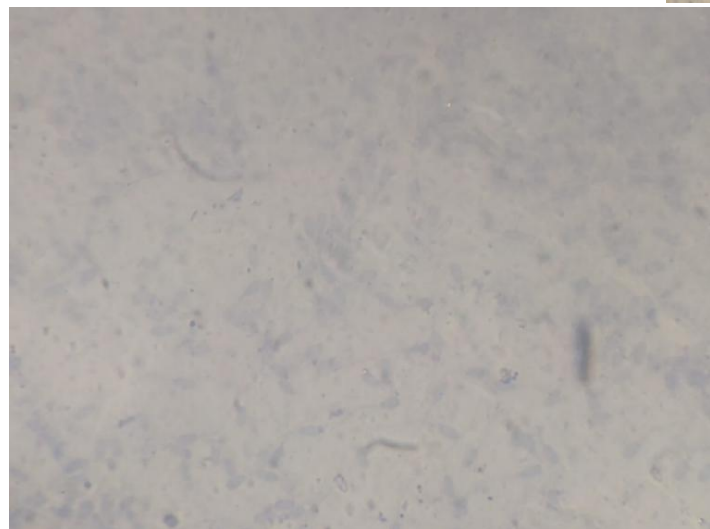
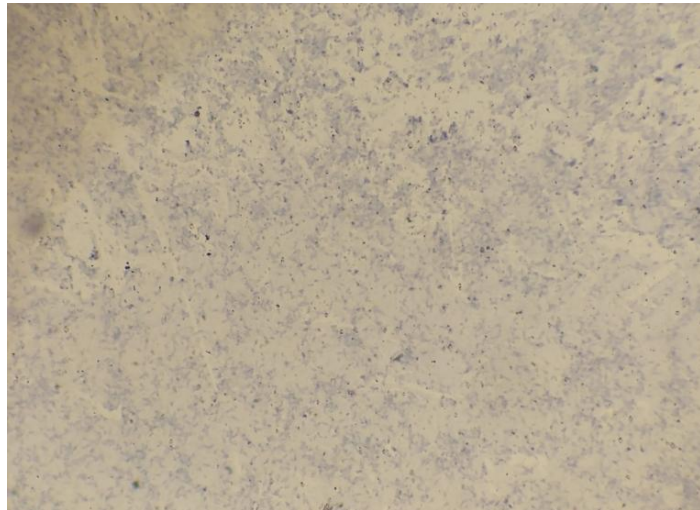
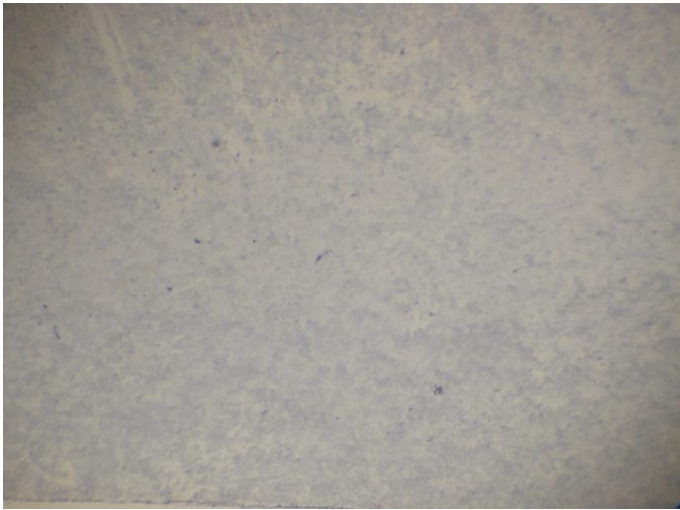


KORUS #4987 • n° 21

- Testicule, section transversale
- Querschnitt durch einen Hoden
- Male gonad, XS
- Поперечный разрез яичка



- Εγκάρσια τομή όρχεως
- Testículo secção transversal
- Testículo sección transversal
- Testicolo sezione trasversale

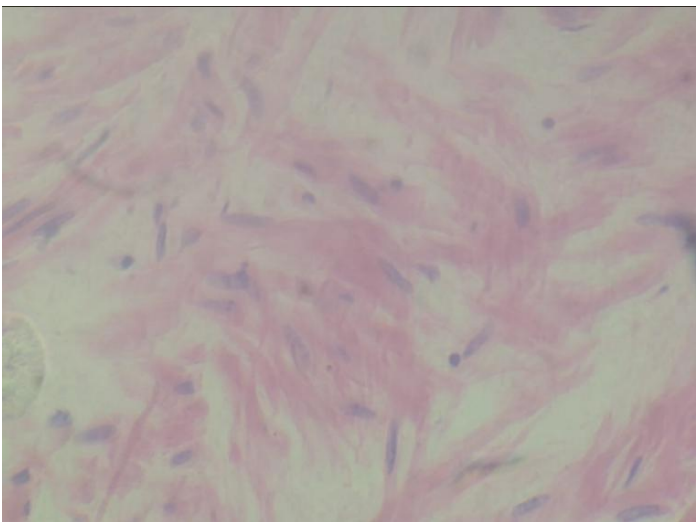
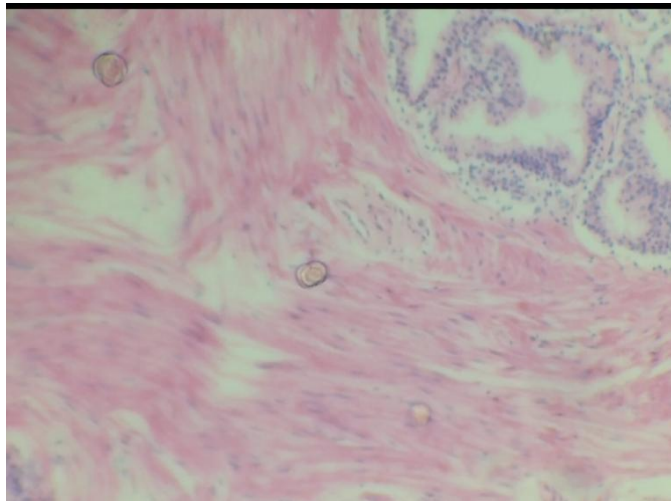
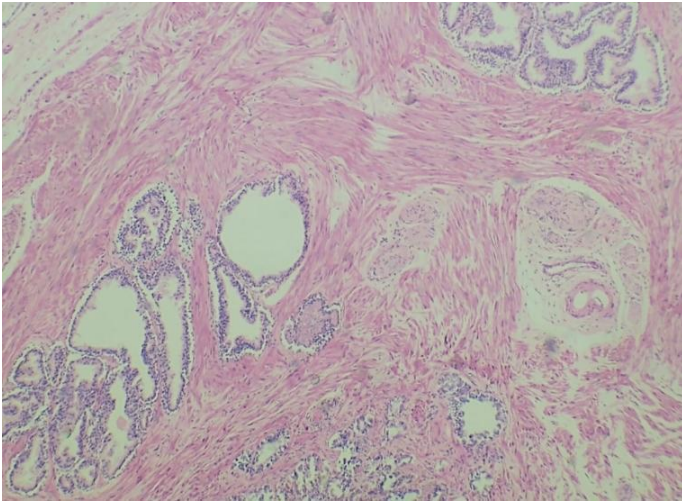


37 • n° 22

des


- Spermien-Abstrich
- Spermatozoa smear
- Мазок сперматозоидов

- Σπερματικό επίχρισμα
- Rasto de espermatozóides
- Frotis de espermatozoides
- Striscio di spermatozoi

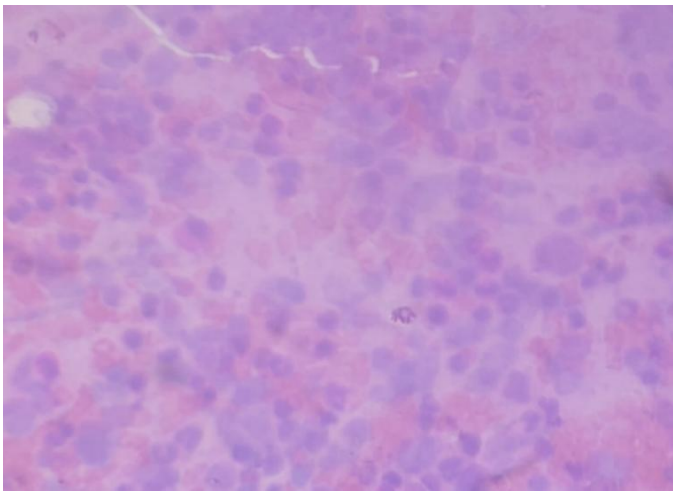
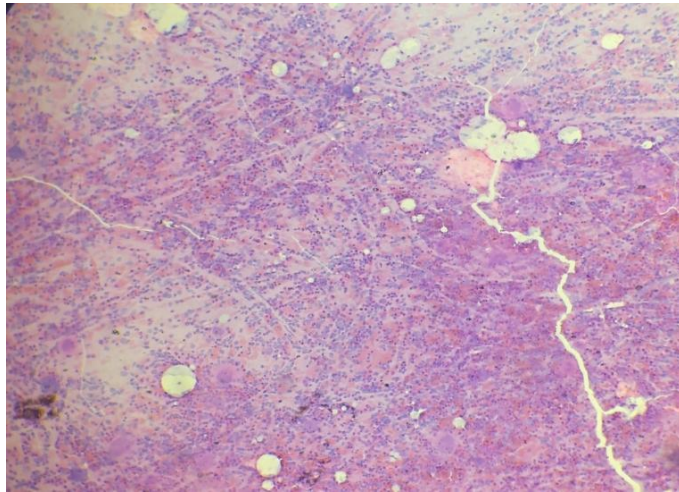
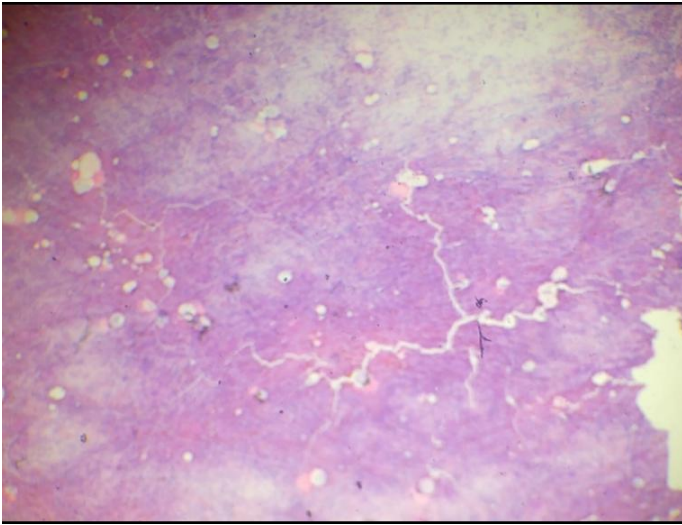


7 • n° 23

- Prostate
- Prostata
- Prostate
- Предстательная железа




- Προστάτης
- Próstata
- Próstata
- Prostata

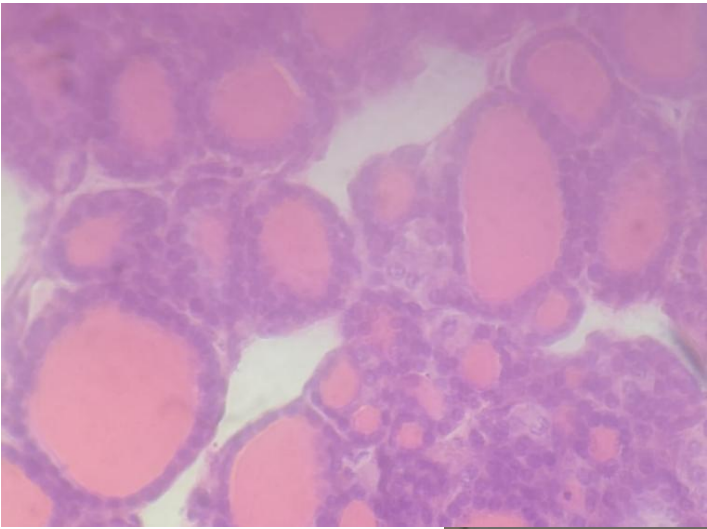
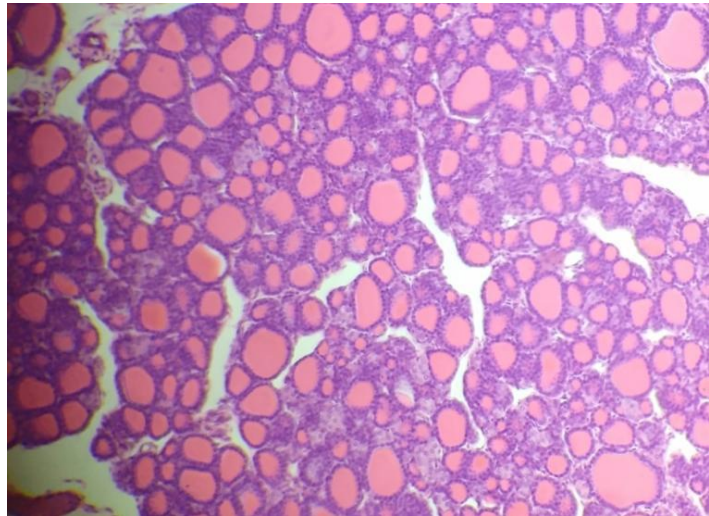
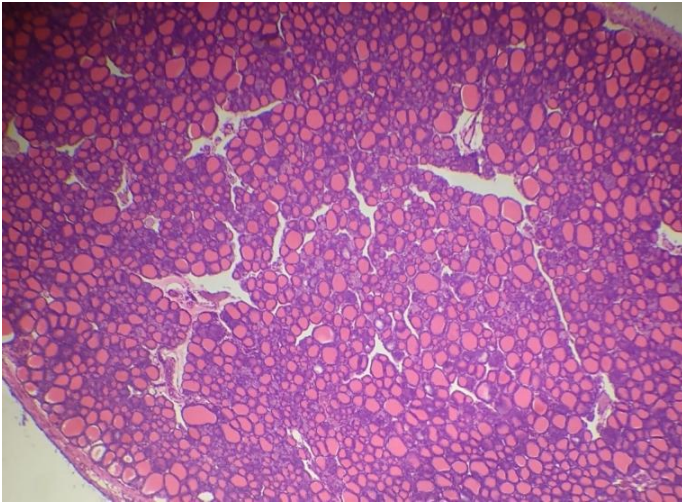


KORUS #4987 • n° 24

- Moelle osseuse rouge avec cellules de sang en phase de formation
- Rotes Knochenmark mit unreifen Blutzellen
- Bone marrow with developing blood cells
- Красный костный мозг с формирующимися клетками крови




- Κόκκινος νωτιαίος μυελός με κύτταρα του αίματος σε σχηματισμό
- Medula óssea vermelha com células do sangue em formação
- Medula ósea roja con células sanguíneas en formación
- Midollo osseo rosso con cellule del sangue in formazione



17 • n° 25

- *Schilddrüse*
- *Thyroid gland*
- *Щитовидная железа*



- *Θυροειδής*
- *Tiróide*
- *Tiroides*
- *Tiroide*