



**Nombre de alumno: Karen Paulina
López Gómez**

Nombre del profesor: Darío Gutiérrez

Nombre del trabajo: Practica digital

Materia: Microanatomía

Grado: 1

Grupo: A

Comitán de Domínguez Chiapas a 4 de enero de 2022.

Introducción

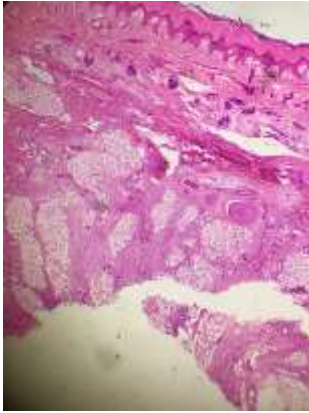
En la siguiente practica se muestran las fotos tomadas con la ayuda del microscopio de las diferentes muestras del “El cuerpo Humano: La estructura de los órganos”.

Se muestra tres imágenes de cada una con los diferentes objetivos:4x,10x y 40x

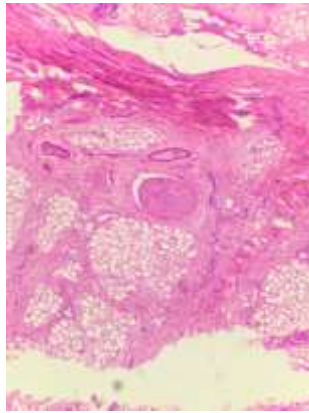
Las imagenes son de distintas partes del cuerpo, entre ellas:

- Piel de axila
 - Cuero cabelludo
 - Uña
 - Glándula parotida
 - Glándula sublingual
 - Esofago y traquea
 - Pared del estomago
 - Intestino
 - Apendice ilocecal
 - Hígado
 - Vesicula biliar
 - Pancreas
 - Pulmon
- Entre otros...

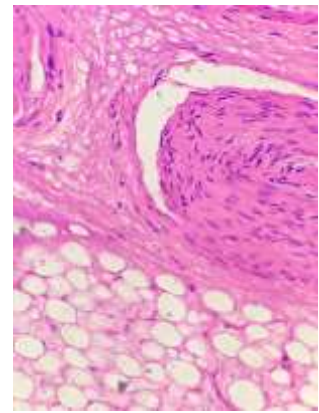
1. Piel de axila con glándulas sudoríparas y folículos pilosos



4x

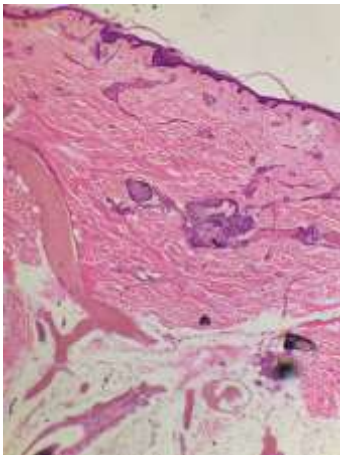


10x

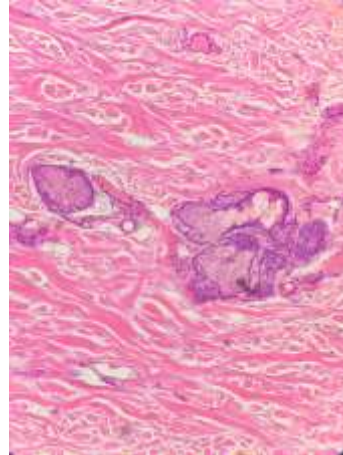


40x

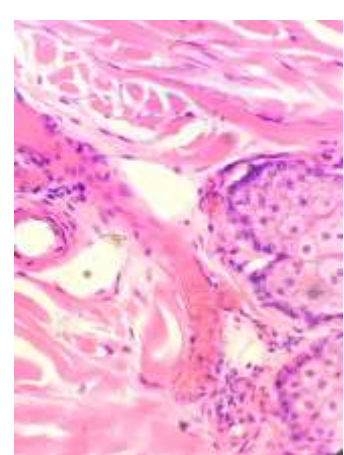
2. Cuero cabelludo con folículos pilosos y glándulas sebáceas



4x

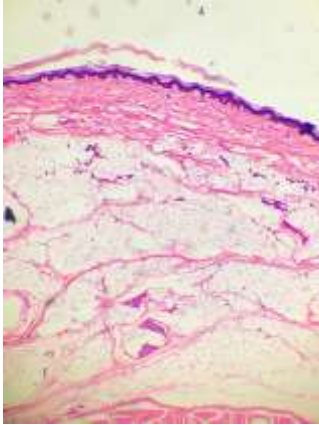


10x

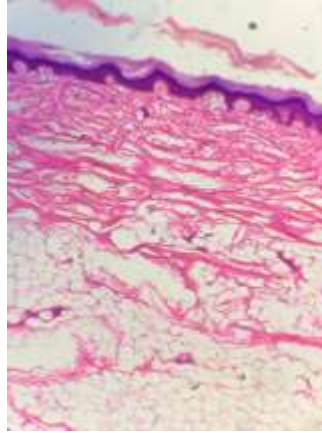


40x

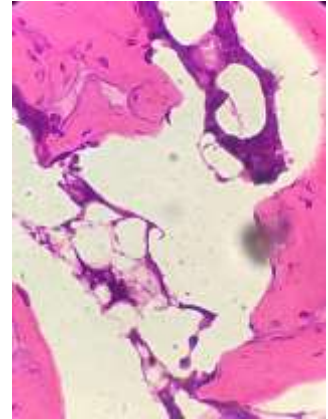
3. Uña del lecho ungueal



4x

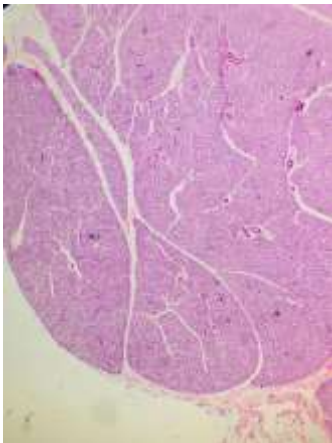


10x

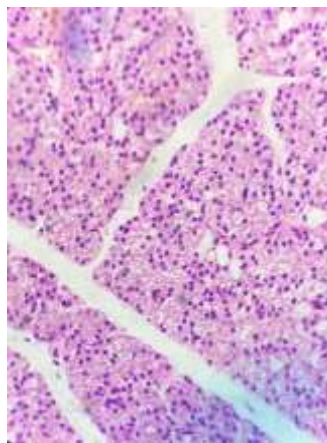


40x

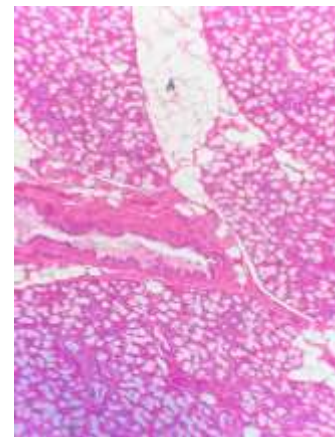
4. Glándula parótida, glándula serosa pura



4x

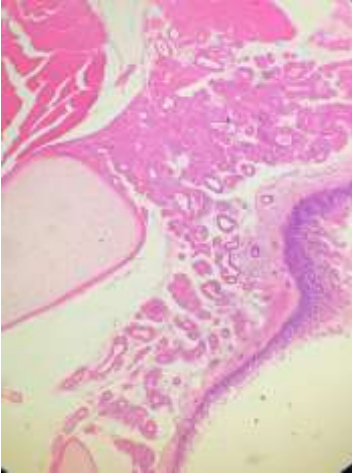


10x

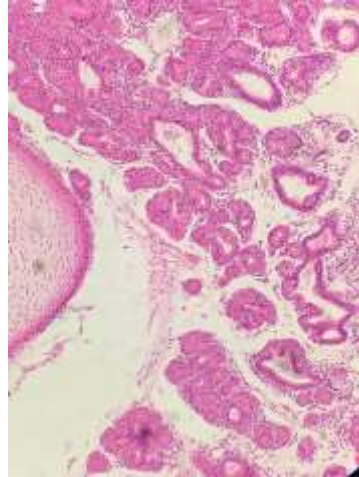


40x

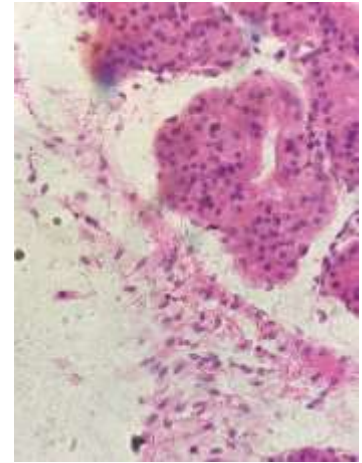
5. Glándula sublingual, glándula mixta



4x

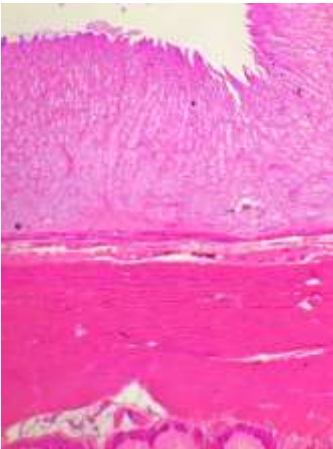


10x

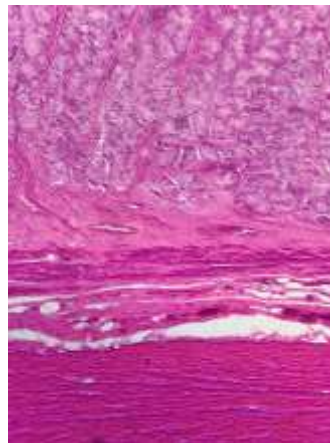


40x

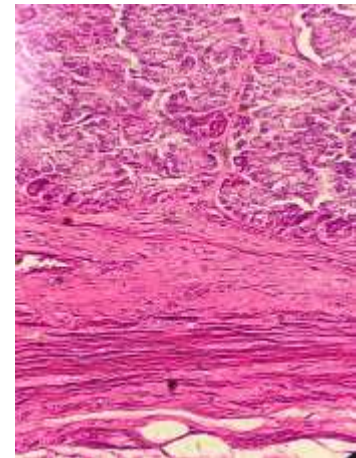
6. Esófago y tráquea de ambos órganos



4x

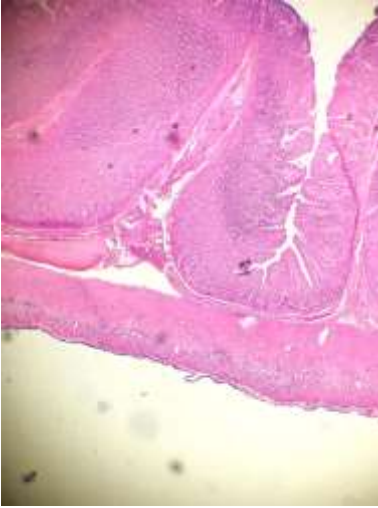


10x

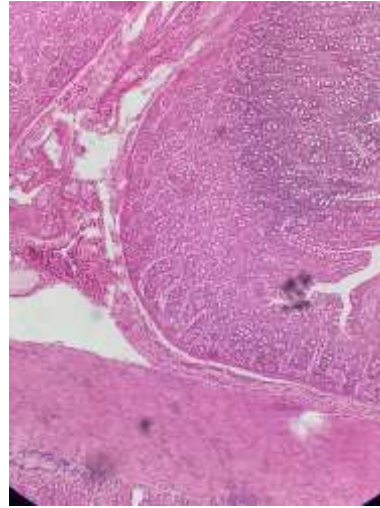


40x

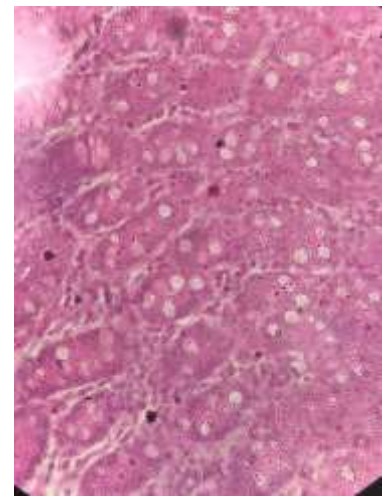
7.Pared del estomago



4x

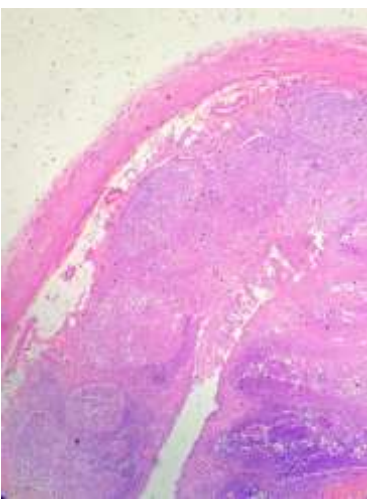


10x

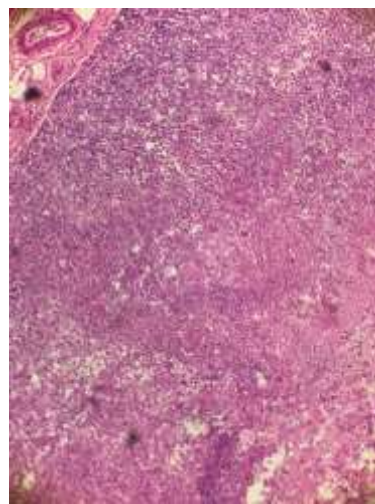


40x

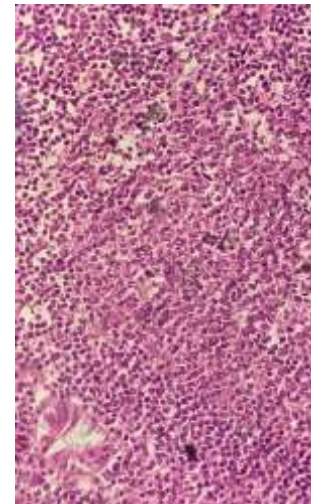
8. Intestino



4x

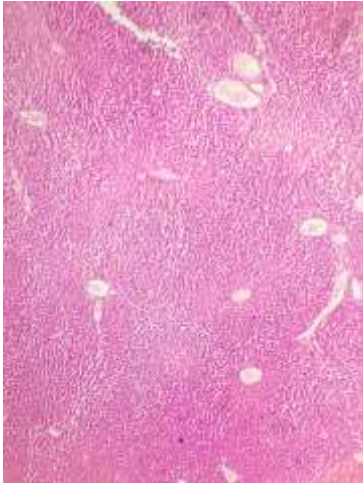


10x

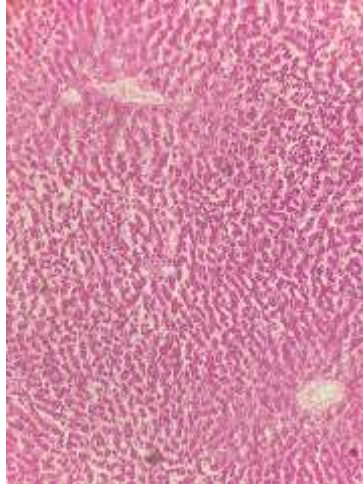


40x

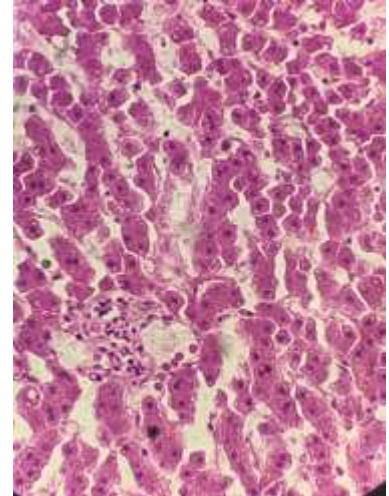
9. Apendice Ilocecal



4x

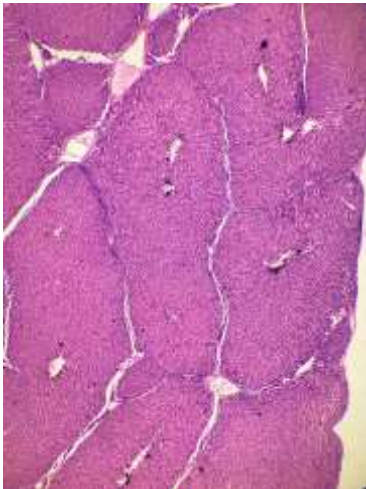


10x

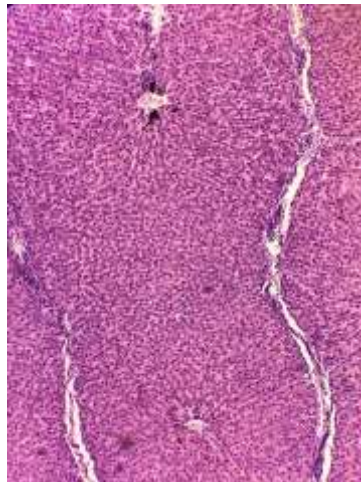


40x

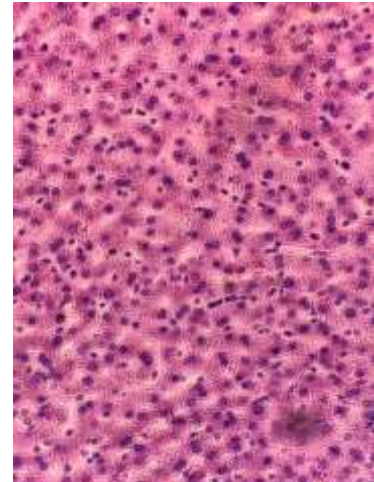
10. Hígado



4x

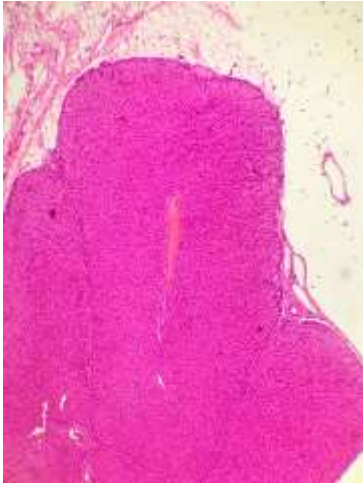

10x



40x

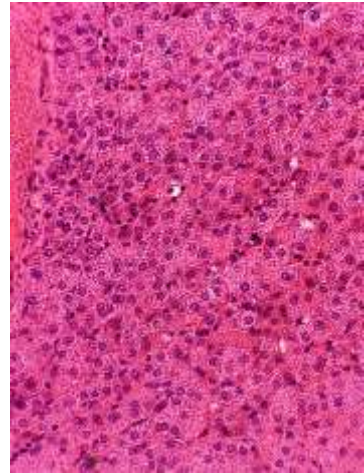
11. Hígado de cerdo con lóbulos circundados de conectivo



4x

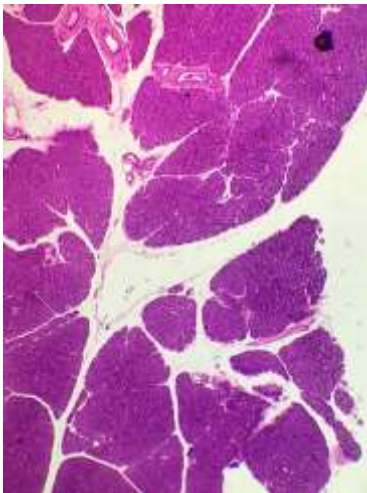


10x

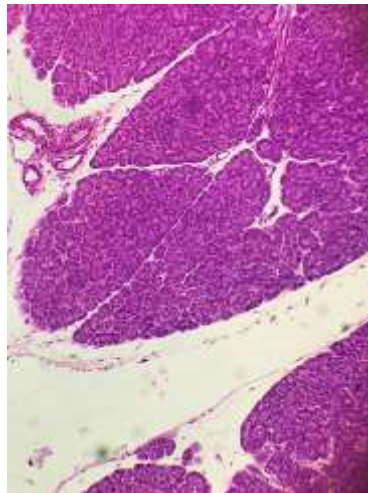


40x

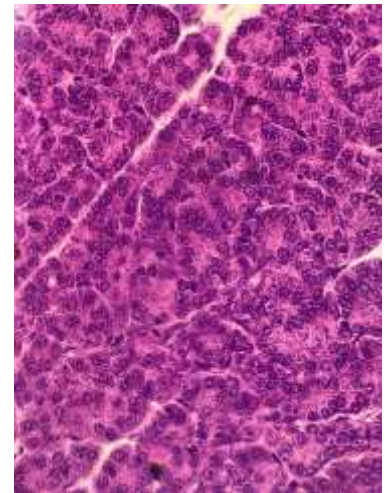
12. Vesícula biliar



4x

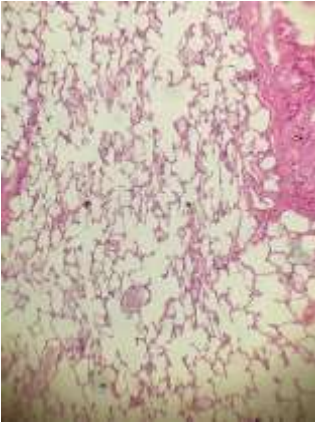


10x

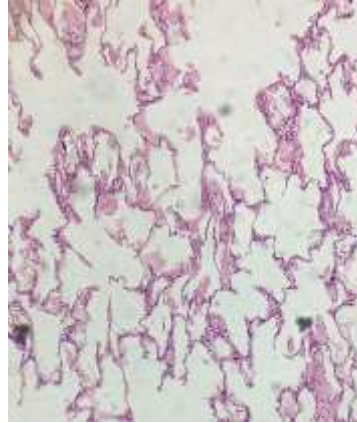


40x

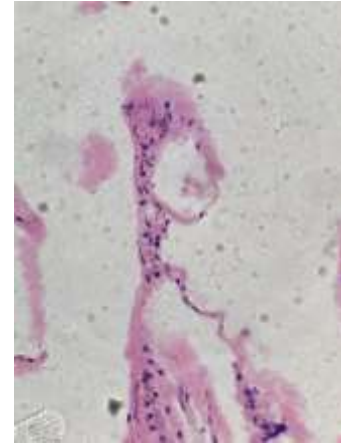
13. Páncreas, glándula acinosa con istoles de Langerhans



4x

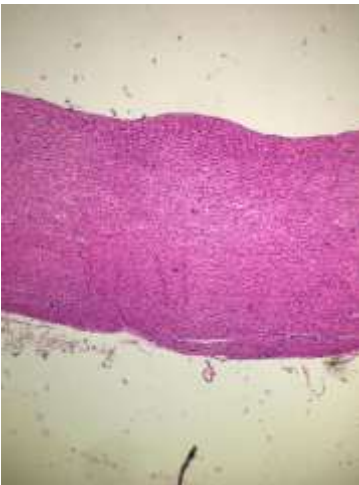

10x

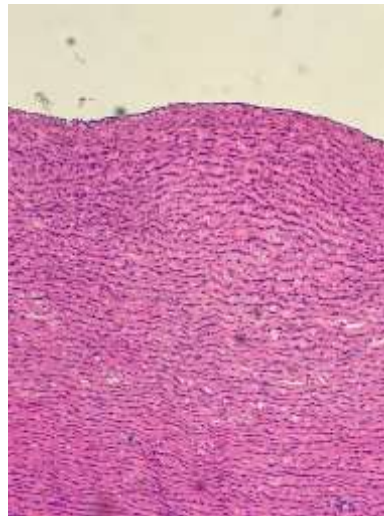


40x

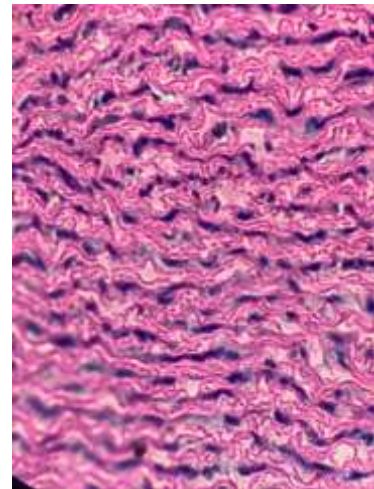
14. Pulmón



4x

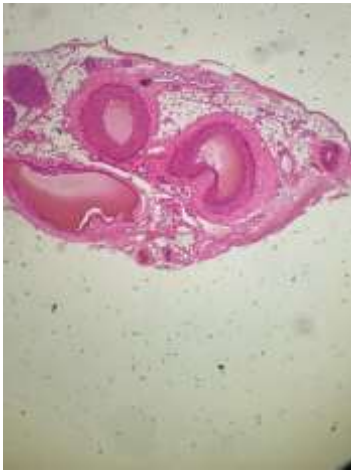

10x

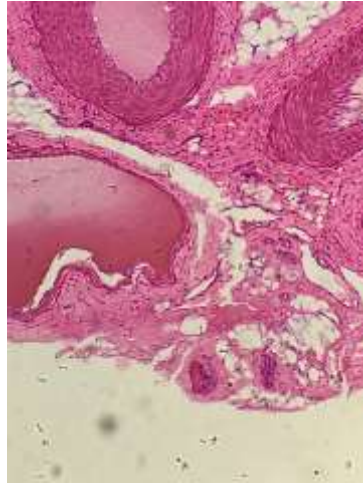


40x

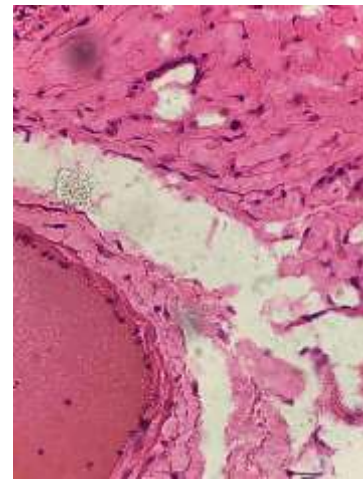
15. Aorta, hemato eosina y coloración para el tejido elástico



4x

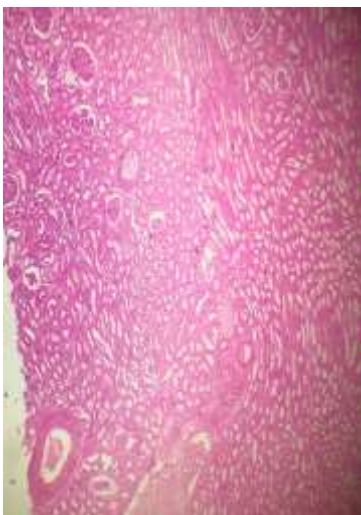


10x

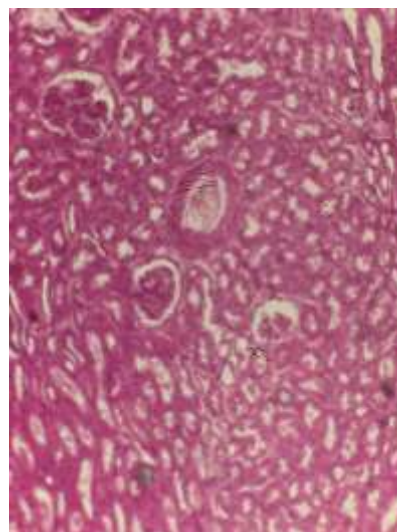


40x

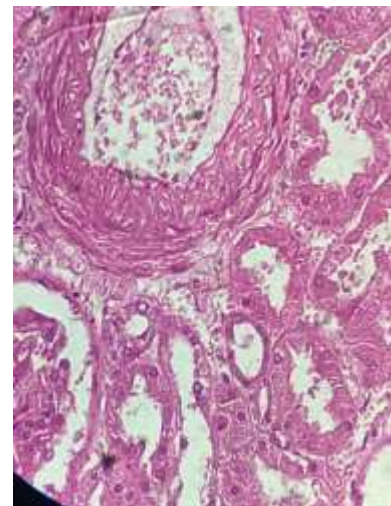
16. Arteria y vena con coloración para tejido elástico



4x

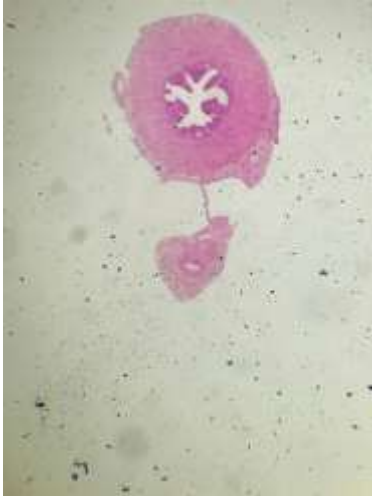

10x

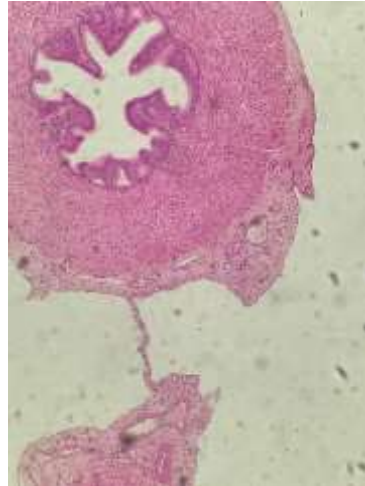


40x

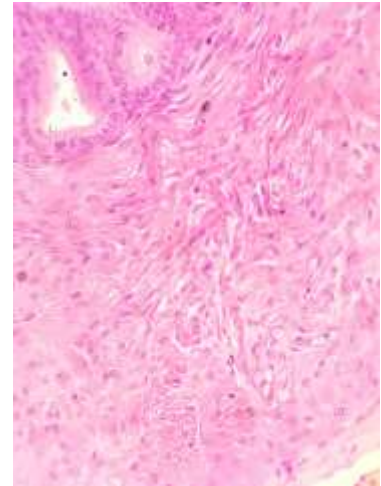
17. Riñón sección de la zona cortical



4x

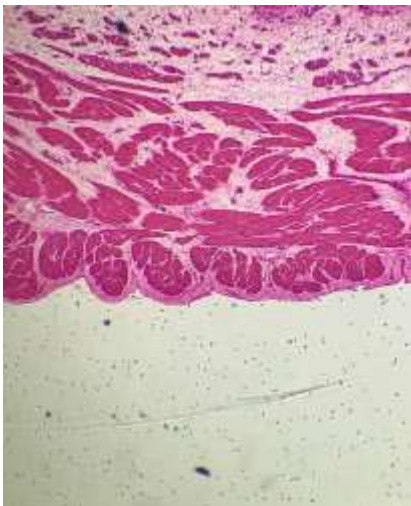


10x

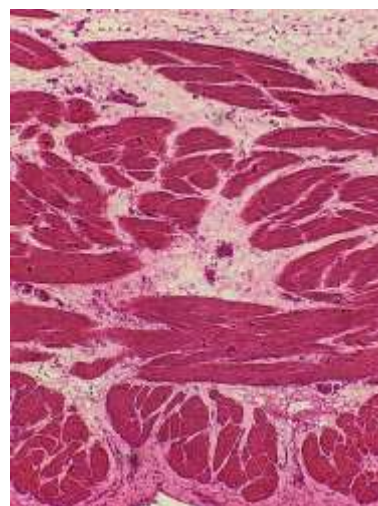


40x

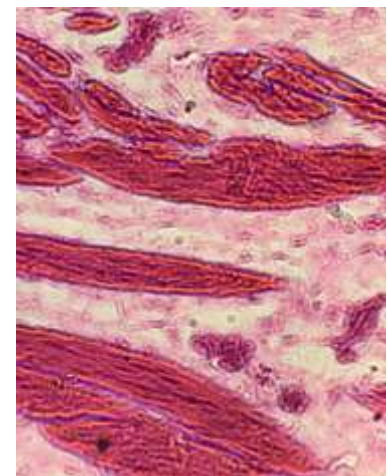
18. Uretra



4x

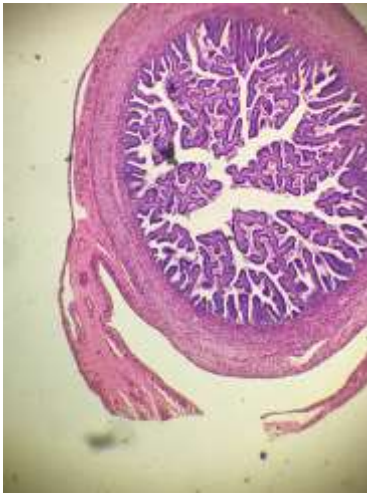

10x

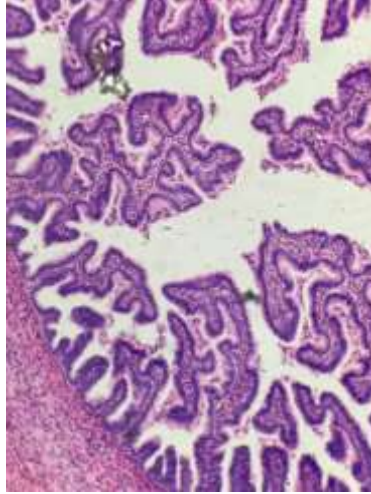


40x

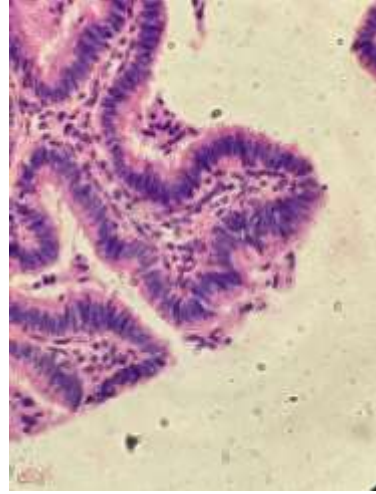
19. Vejiga Urinaria



4x

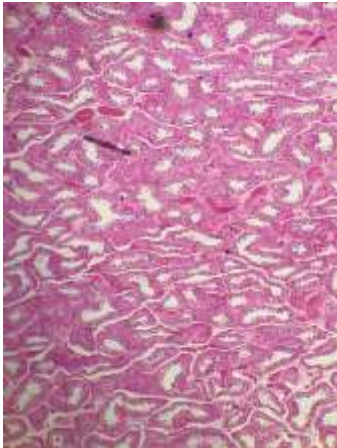


10x

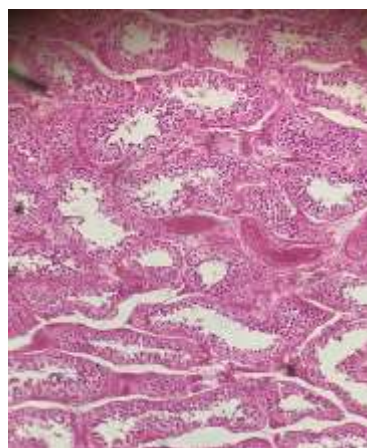


40x

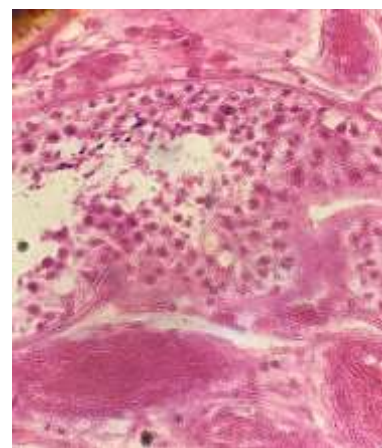
20. Tubo uterino (trompa de Falopio), sección a través de la ampolla



4x

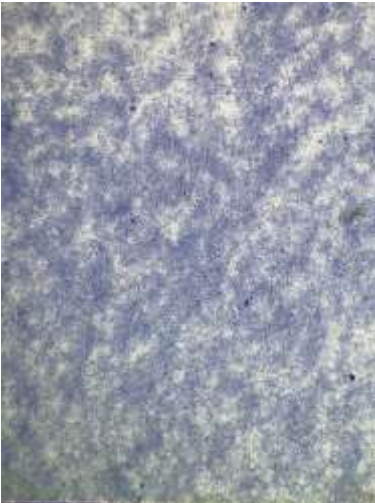


10x



40x

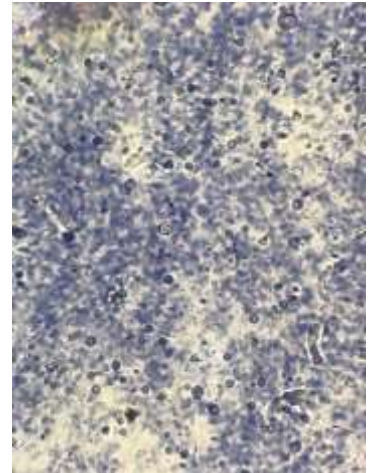
21. Testículo sección transversal



4x

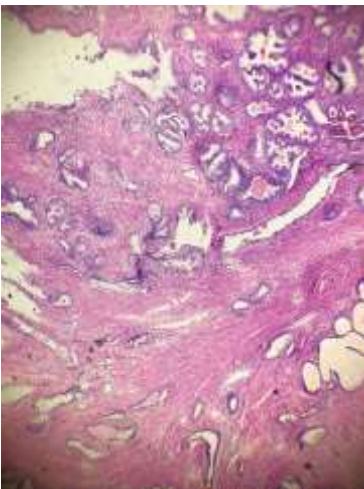


10x

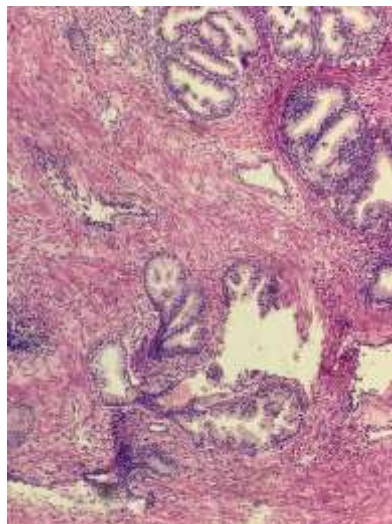


40x

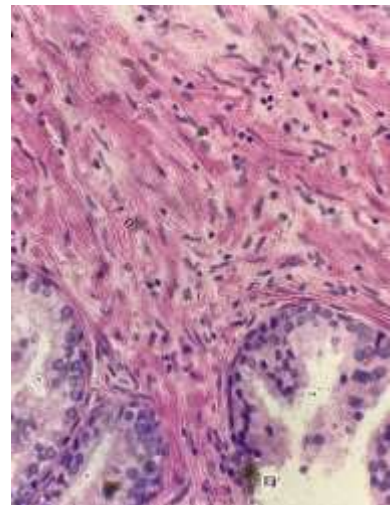
22. Frotis de espermatozoide



4x

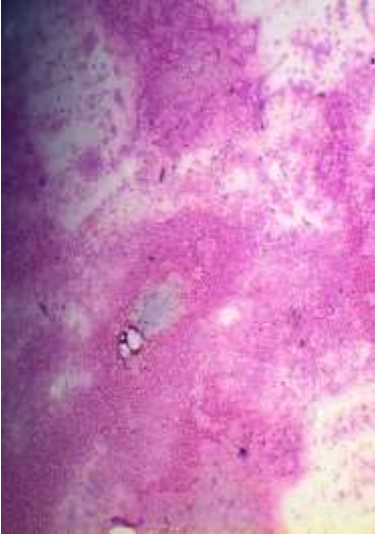


10x

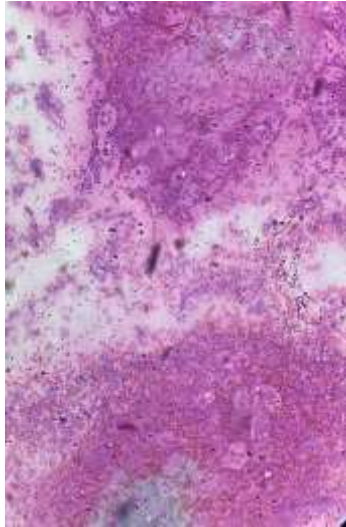


40x

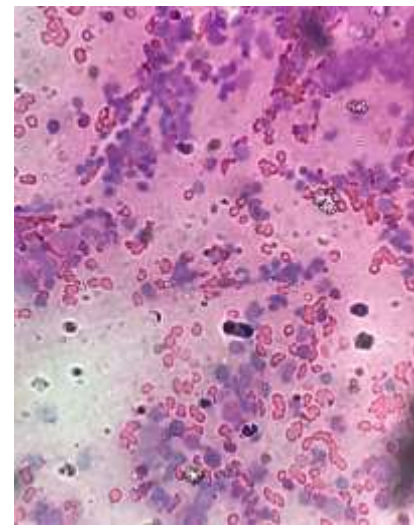
23. Próstata



4x

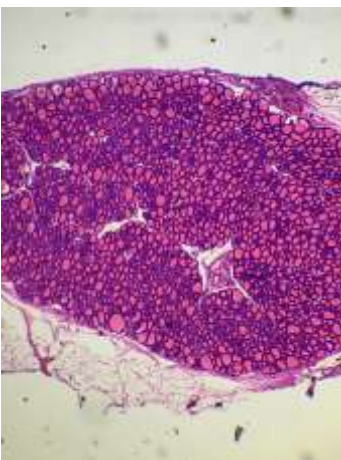


10x

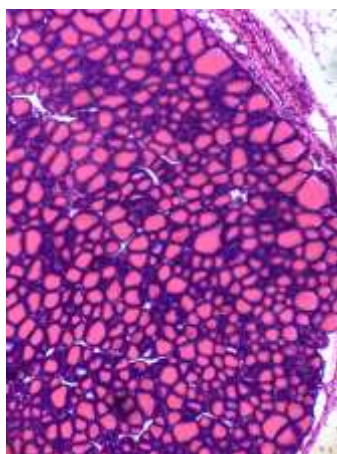


40x

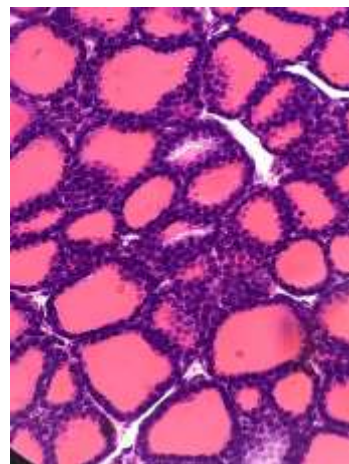
24. Medula ósea roja con células sanguíneas en formación



4x



10x



40x