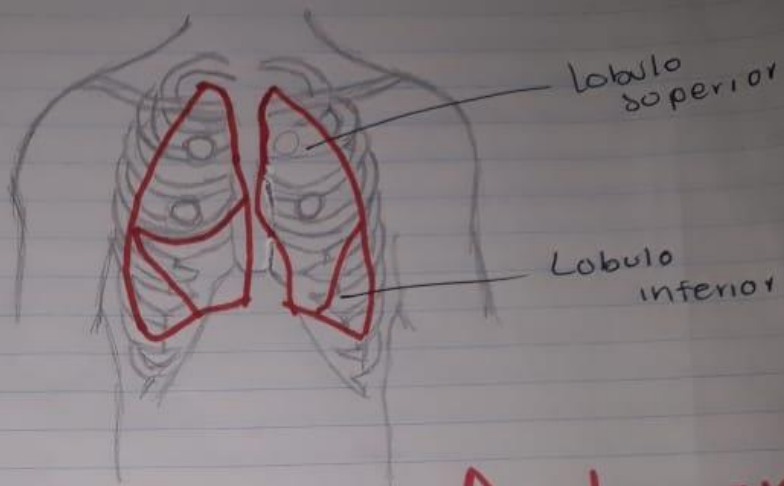
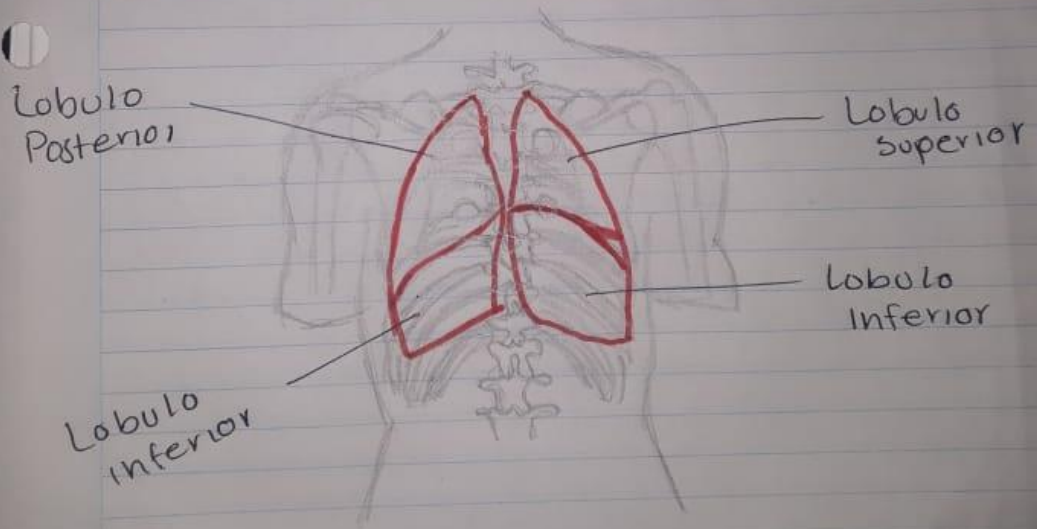


« Torax normal »



Anterior



Posterior