

Conducto  
cístico

Glandula Suprarenal  
Dextra

Arteria hepatica  
común

Vesicula  
Biliar

Linon Dirc.

Papila  
Judenal  
major

Conducto  
Pancreatico  
Accesorio

Conducto  
Pancreatico  
Principal

Conducto  
Biliar

Glandula  
Suprarenal Izq.  
Arteria Esplénica

Linon Izq.

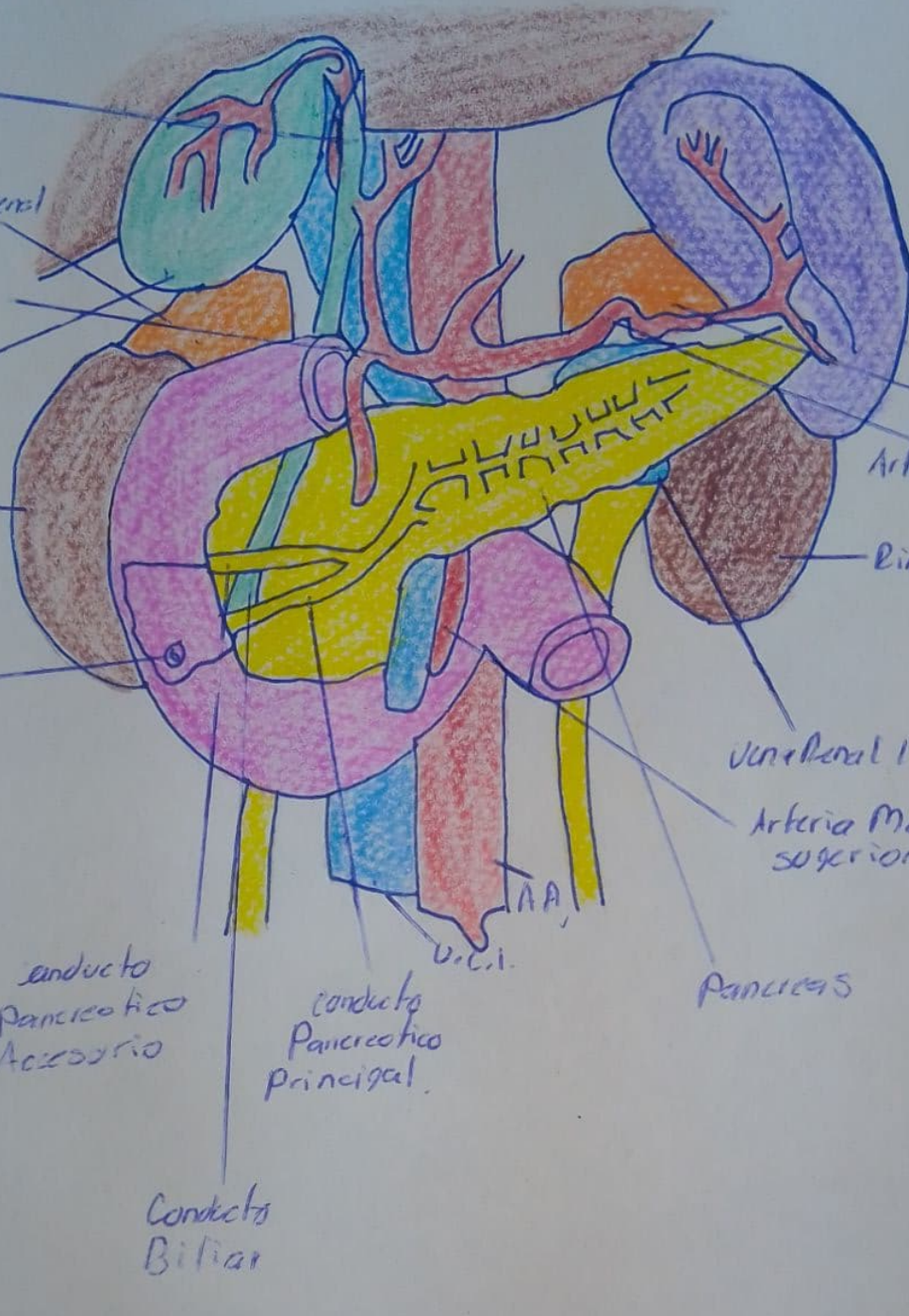
Vena Portal Izq.

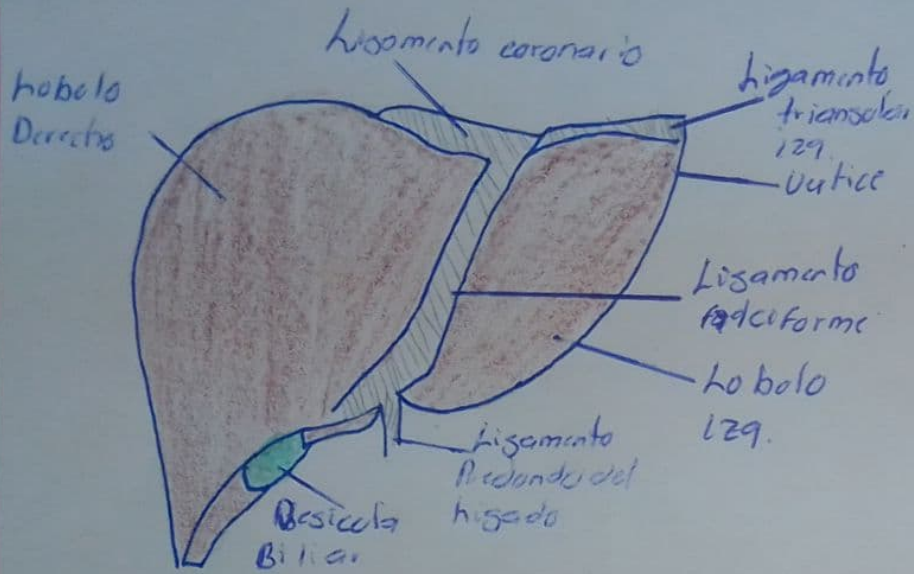
Arteria Mesenterica  
superior

PANCREAS

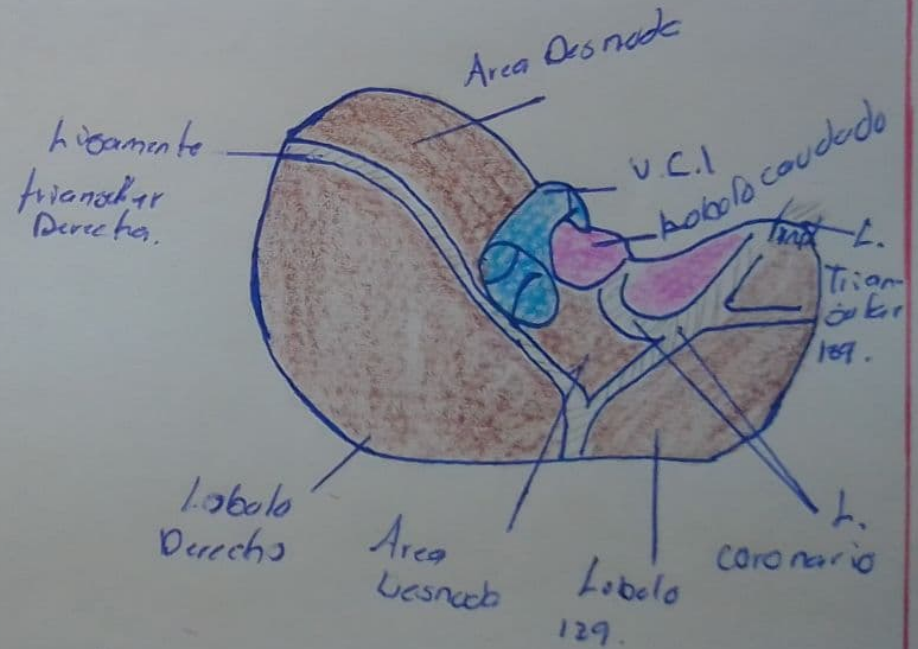
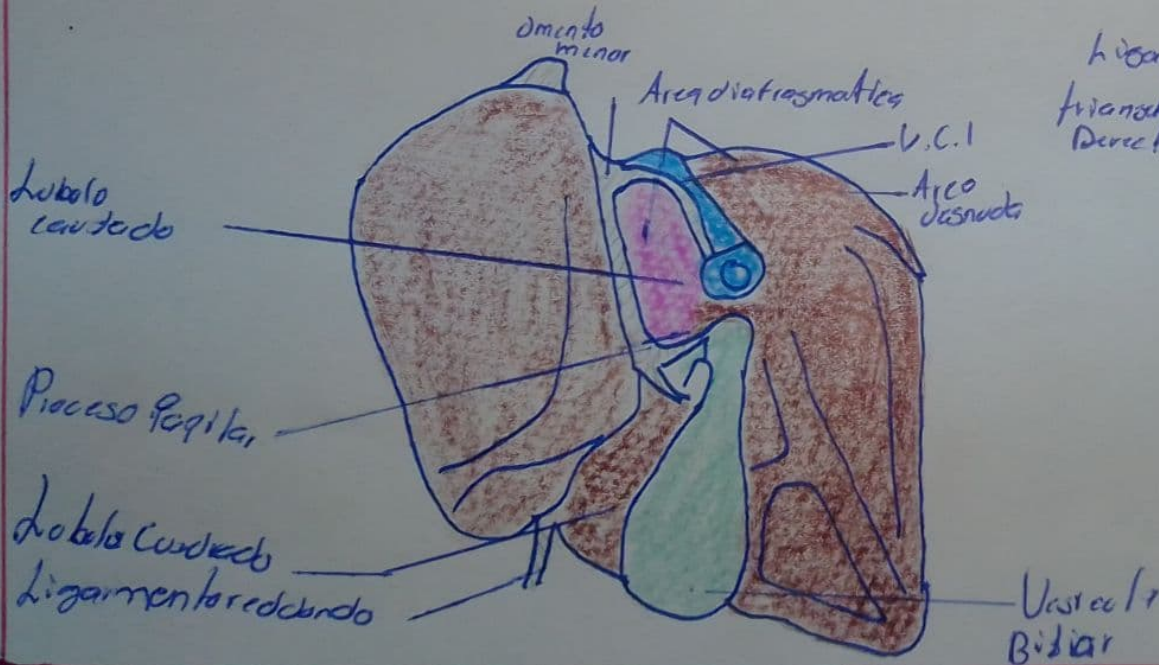
AA

U.C.I.

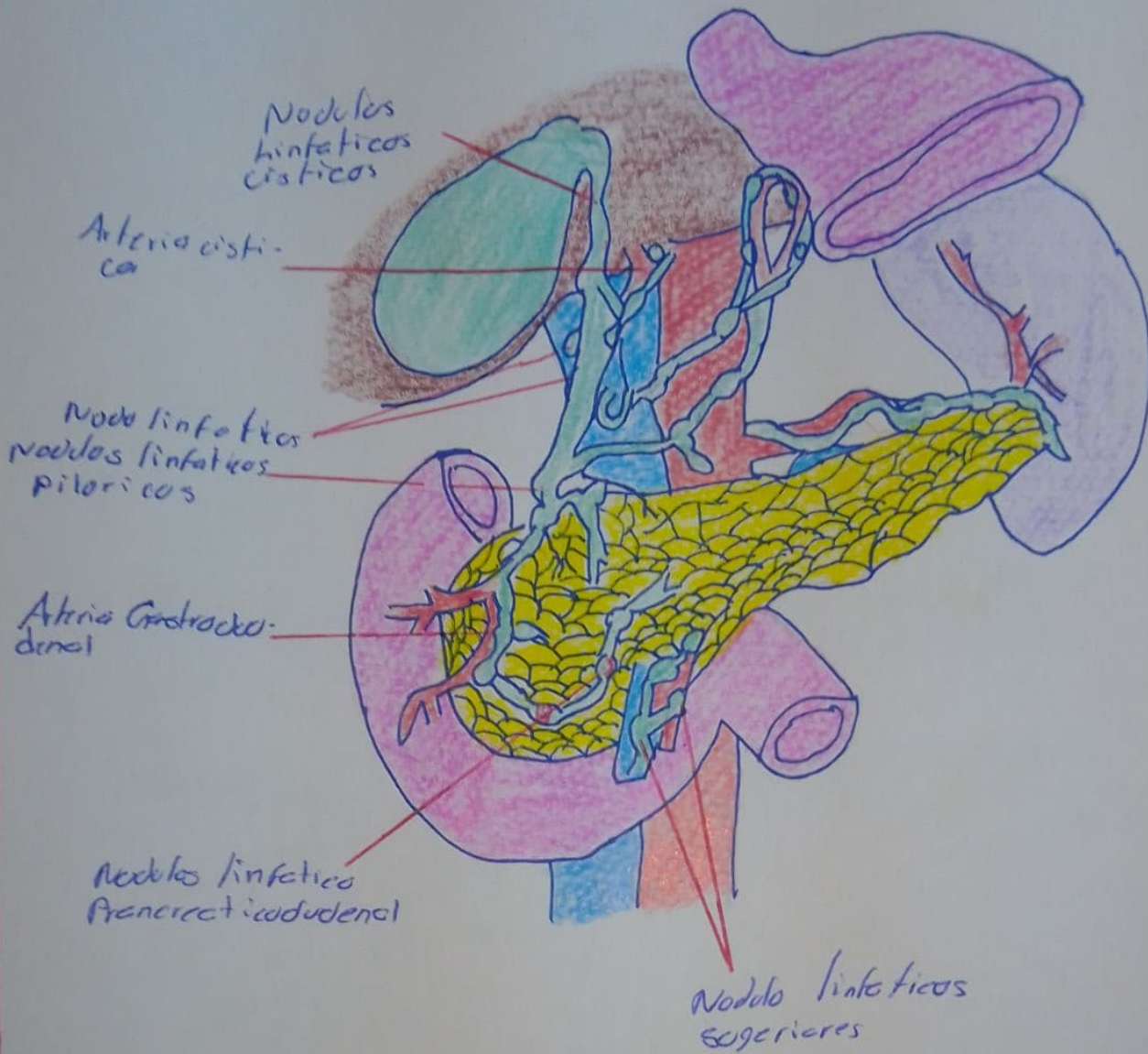




# HIGADO







# VESICULA BILIAR