



**UNIVERSIDAD DEL SURESTE**

**LICENCIATURA EN ENFERMERIA**

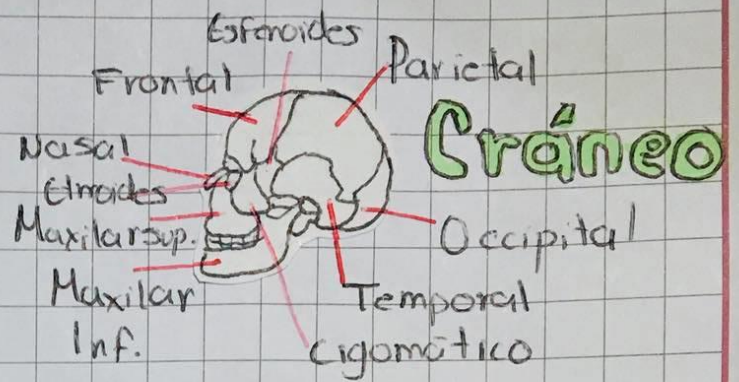
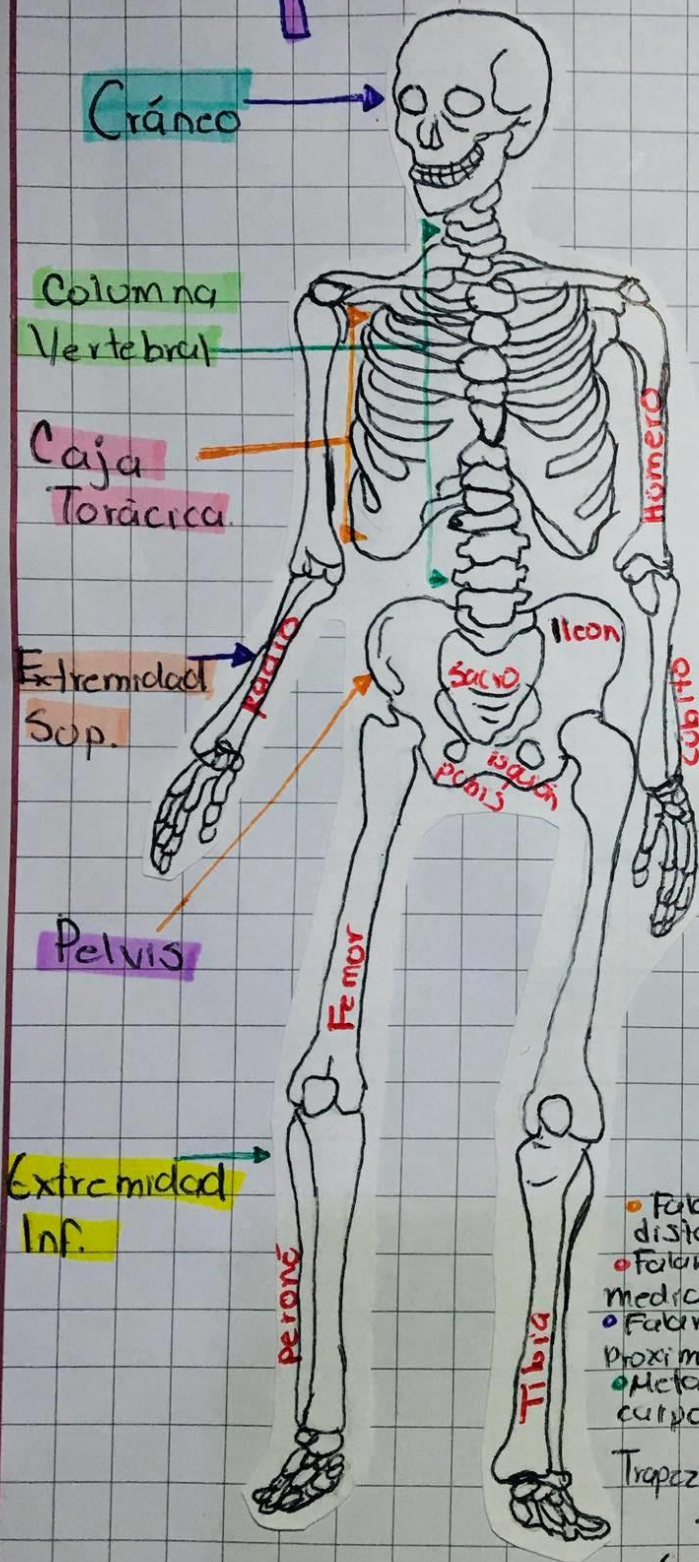
**9D**

**PRACTICAS PROFESIONALES**

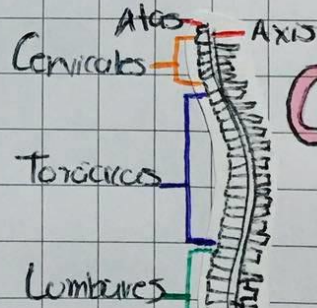
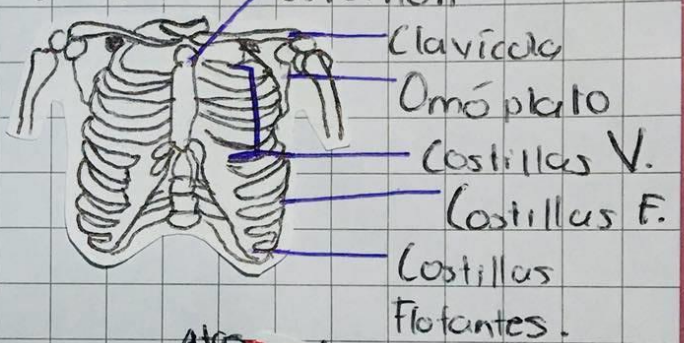
**PROF. LOPEZ SILBA MARIA DEL CARMEN**

**ALUMNA. GONZALEZ PARADA DALIT  
ITZAMANAT**

# Esqueleto humano.



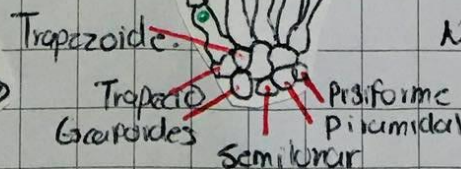
## Torax



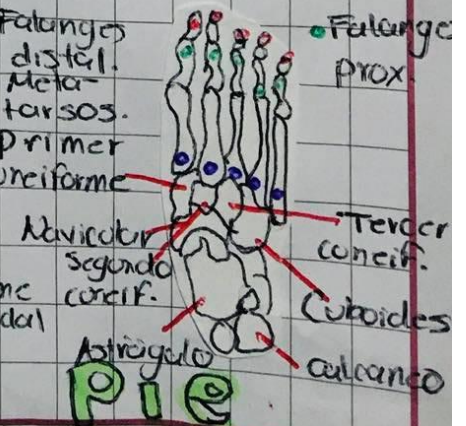## Columna V.

## Mano

- Falanges distales.
- Falanges mediales.
- Falanges proximales.
- Metacarpos.



- Falanges distales.
- Metatarsos.
- Primer carif.



## Pie

# Musculos

