



UNIVERSIDAD DEL SURESTE

ESCUELA DE MEDICINA

“Mapa mental de cataratas”

Javier Octavio Guillén Narváez

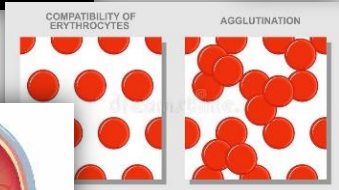
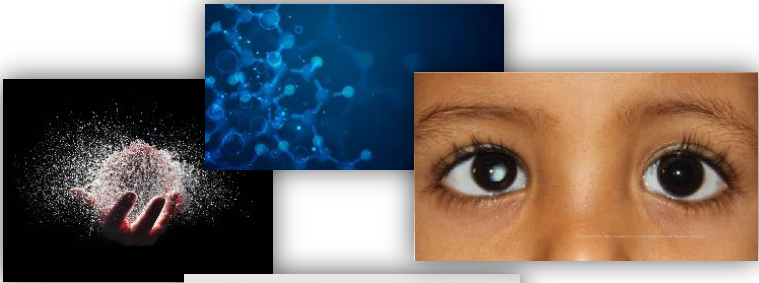“Geriatría”

Semestre: 6°

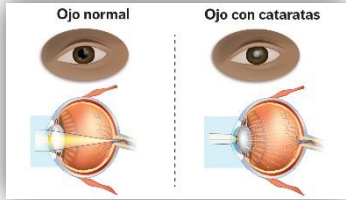
Grupo: “A”

Dr. Julliscer Aguilar Indili

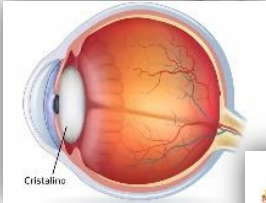Comitán de Domínguez, Chiapas junio 2020.



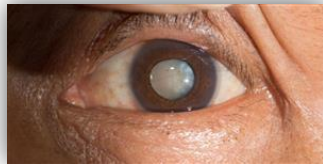
Etiología



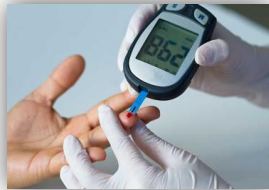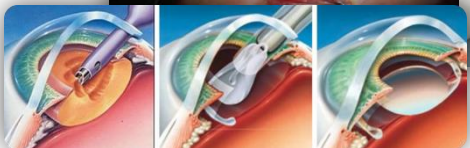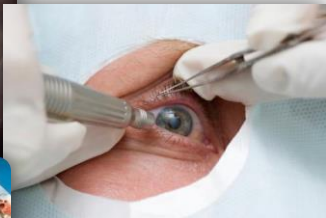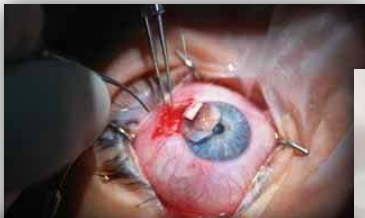Cataratas



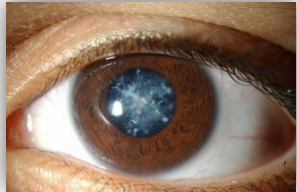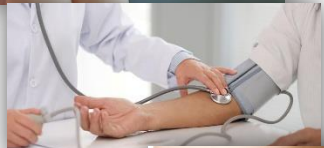Sintomatología



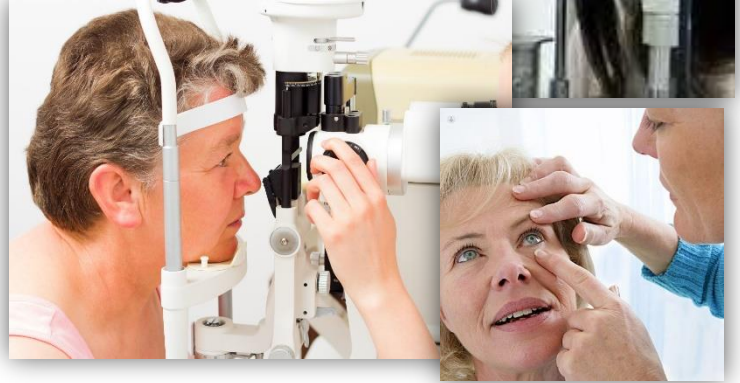Tratamiento




Factores de riesgo



Diagnóstico

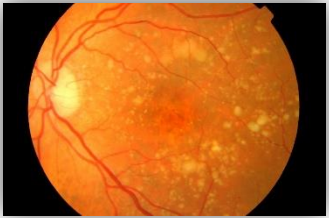



Incidencia



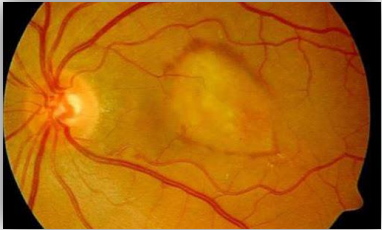
Factores de riesgo




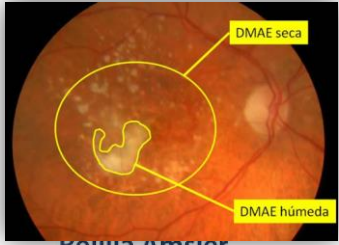
DEMAE



Sintomatología

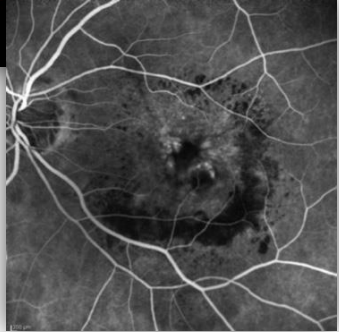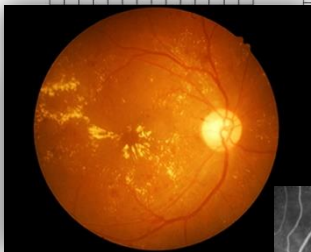


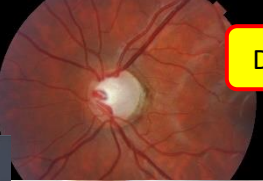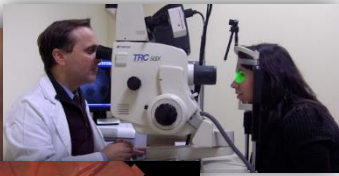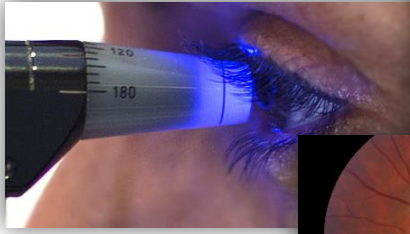
Diagnóstico



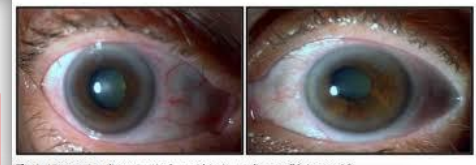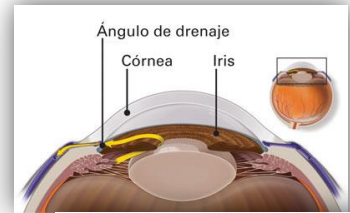
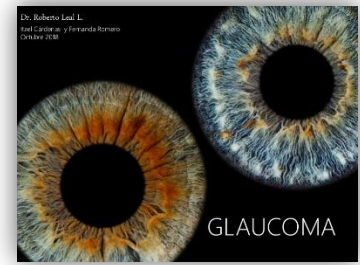GRAPHIC ILLUSTRATES THE PROGRESSION OF EYESIGHT MOVING FROM NORMAL VISION TO WET AMD (A » D)

Tratamiento

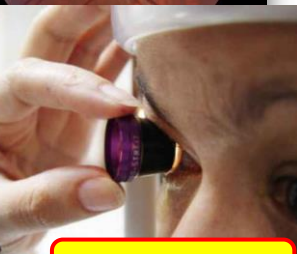



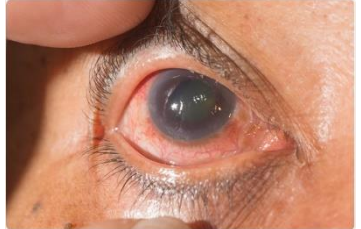Diagnóstico



Ángulo Cerrado



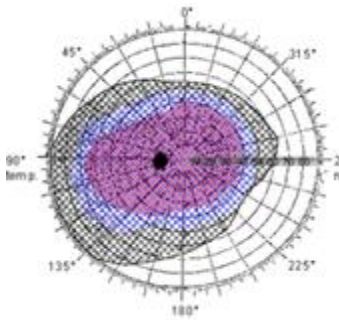
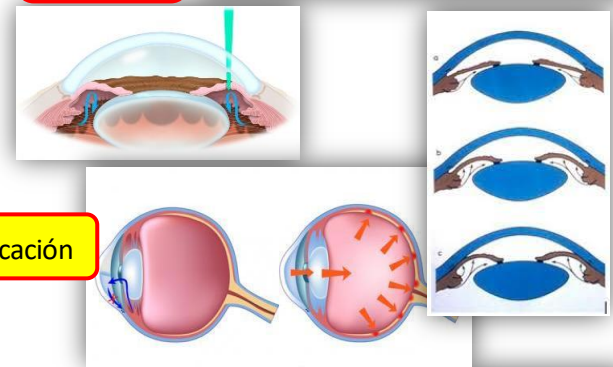


Sintomatología

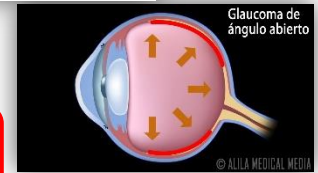


Glaucoma

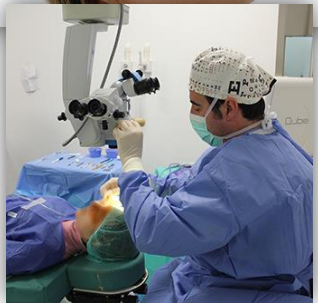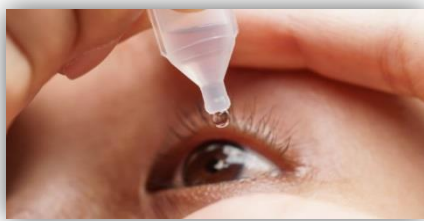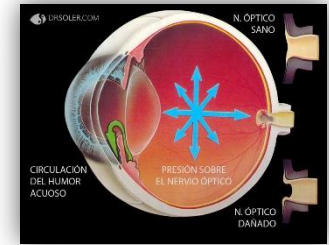
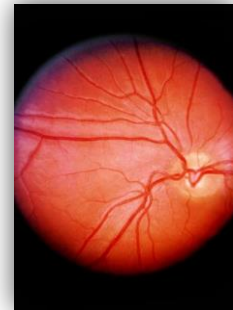
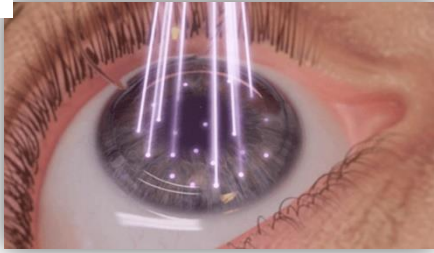
Clasificación

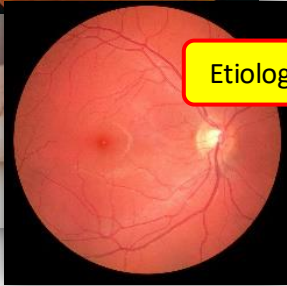
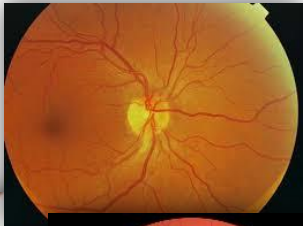
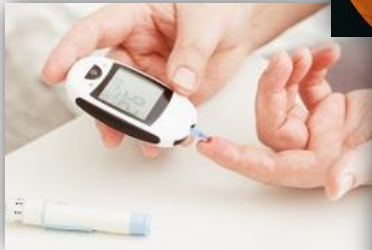
Ángulo Abierto

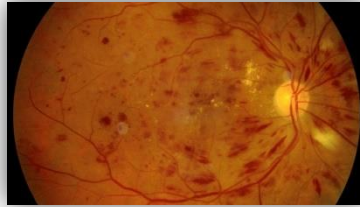
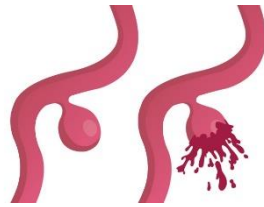


Tratamiento





Etiología



Retinopatía diabética

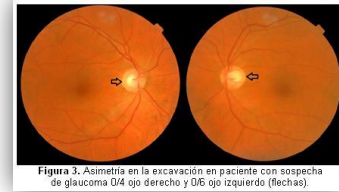
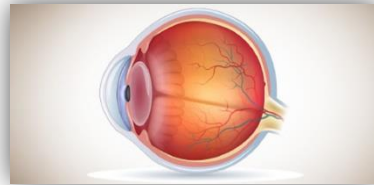
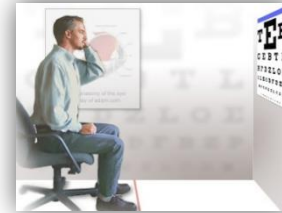
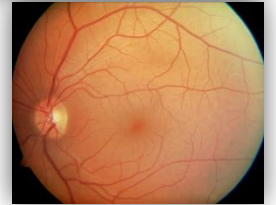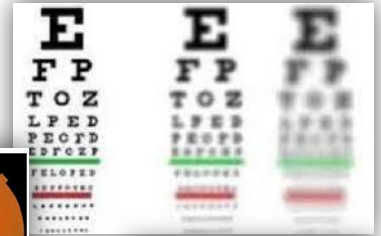


Figura 3. Asimetría en la excavación en paciente con sospecha de glaucoma O/4 ojo derecho y O/6 ojo izquierdo (flechas).

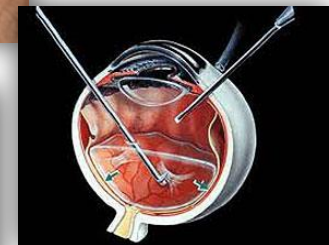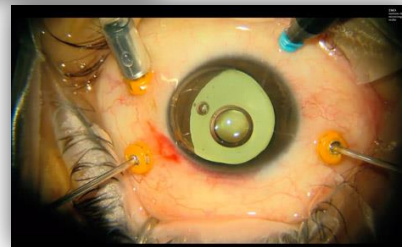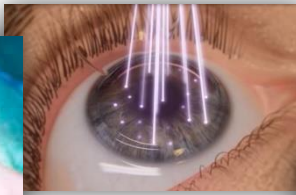
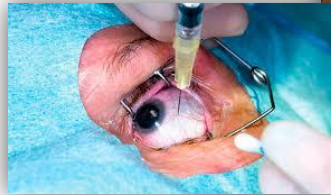Diagnóstico



Sintomatología



Tratamiento



Fuente bibliográfica

Sociedad española de Oftalmología . Retinopatía diabética. 941 congreso SEO

Manual divulgativo de la Sociedad de Retina y Vitreo

Dubón M. Mendoza L. Larios A. Retinopatía diabética. Revista de la Facultad de Medicina de la UNAM

Brechtel M. González O. y cols. (2001). Glaucoma primario de ángulo abierto. Revista del Hospital General Dr. Manuel Gea González

Marcello J. Lansingh V. y cols. (2012). Guía de catarata senil para Latinoamérica. ORBIS. International