

**Universidad del Sureste**

**Materia: Clínica de Pediatría**

**Docente: Dr. Luis Mauricio Jiménez Ortega**

**Alumno: José Alfredo Sánchez Álvarez**

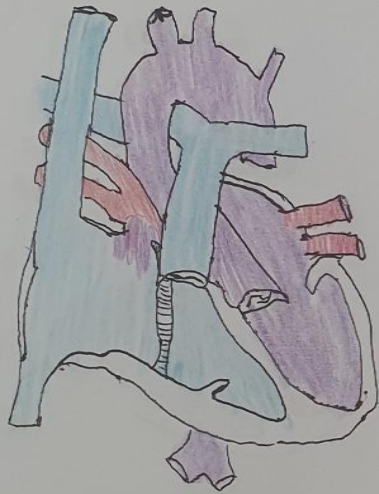
**7° Semestre      Grupo “Único”**

**Comitán de Domínguez**

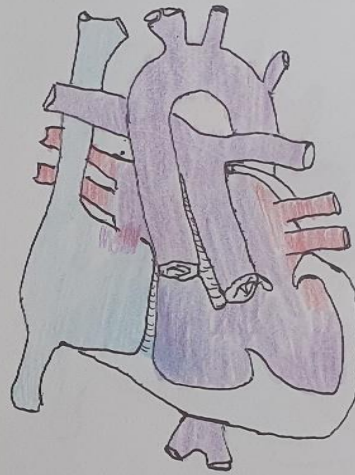**30 de Junio del 2020**

# Cardiopatías

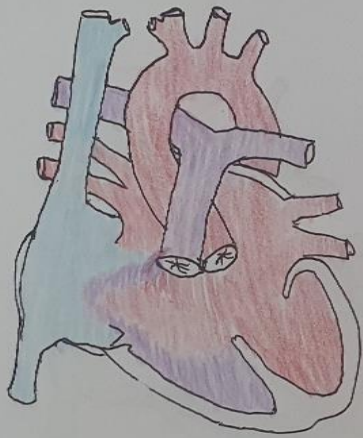
Anomalia de Ebstein



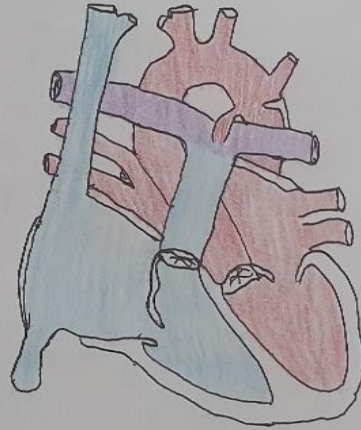
Atresia tricúspide



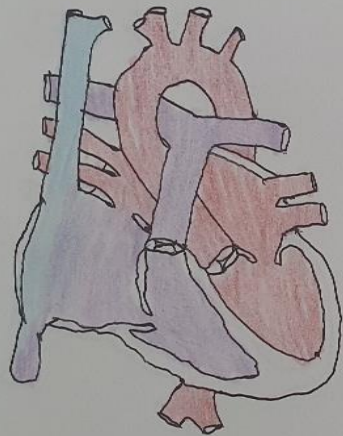
Corazón aorticoventricular (Corazón AV)



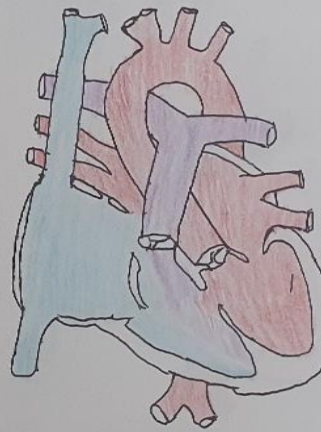
Coartación de la aorta



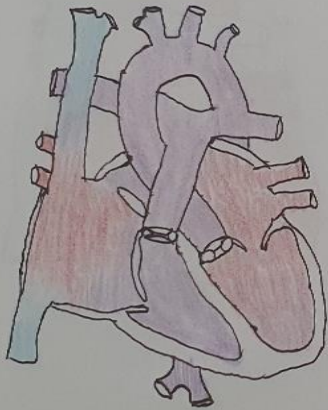
Comunicación interventricular (CIA)



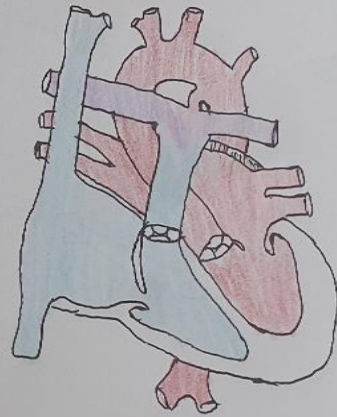
Comunicación interventricular (CIV)



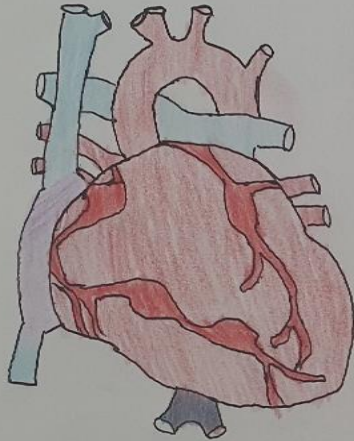
Drenaje venoso pulmonar unimale



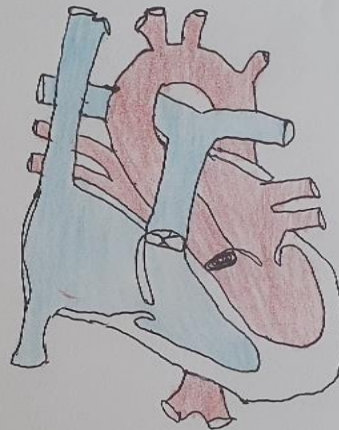
Ductus arterioso persistente



Enfermedad de Kawasaki

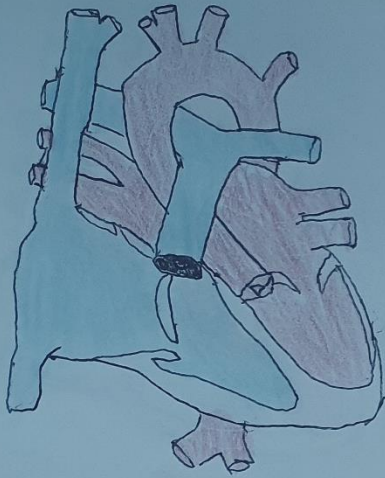


Estenosis aórtica

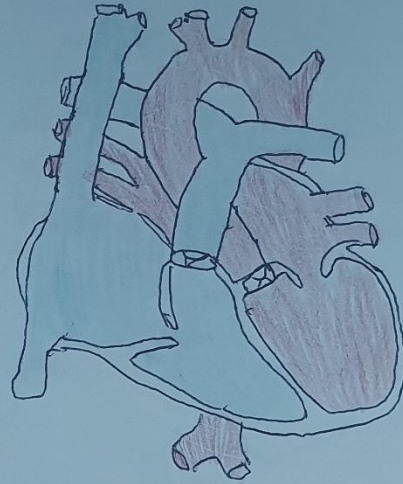




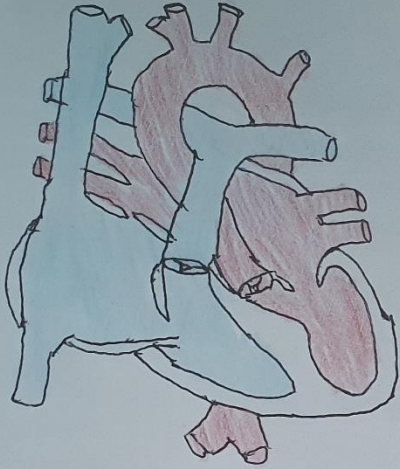
Estenosis pulmonar



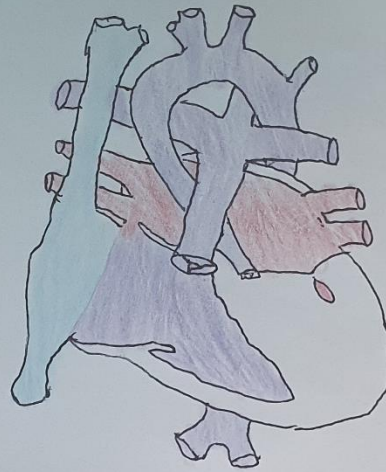
Miocardio patia dilatada



Miocardopatía hipertrofica

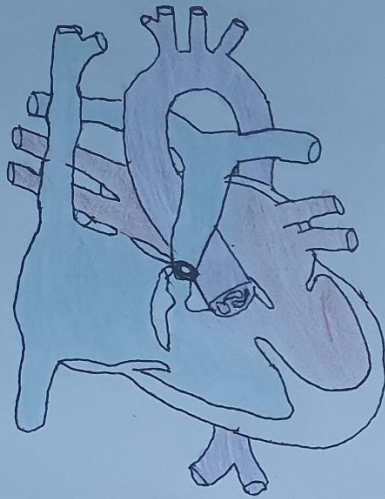


Sx del ventrículo izquierdo hipoplásico

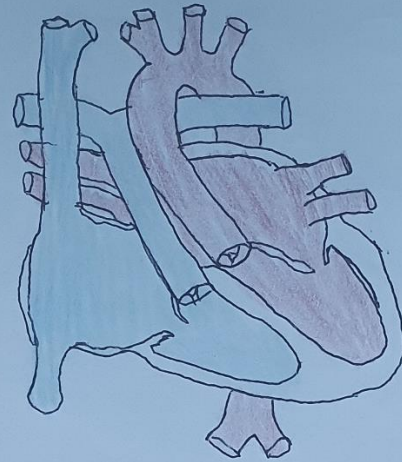




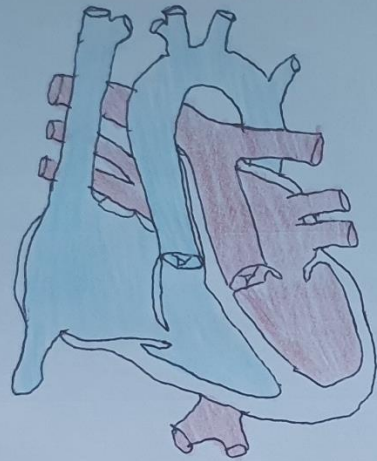
Tetralogía de Fallot



Trasposición corregida de las grandes arterias



Trasposición de las grandes arterias



Tronco arterial (o tronco arterial común)

